National Comprehensive Cancer Network®

NCCN Clinical Practice Guidelines in Oncology (NCCN Guidelines®)

Testicular Cancer

Version 1.2026 — October 15, 2025

NCCN.org

NCCN recognizes the importance of clinical trials and encourages participation when applicable and available. Trials should be designed to maximize inclusiveness and broad representative enrollment.

Continue

Version 1.2026, 10/15/2025 © 2025 National Comprehensive Cancer Network® (NCCN®), All rights reserved. NCCN Guidelines® and this illustration may not be reproduced in any form without the express written permission of NCCN.

PLEASE NOTE that use of this NCCN Content is governed by the End-User License Agreement, and you MAY NOT distribute this Content or use it with any artificial intelligence model or tool.
Printed by Máximo López Chenlo on 5/4/2026 6:31:34 PM. Copyright © 2026 National Comprehensive Cancer Network, Inc. All Rights Reserved.

***Timothy Gilligan, MD, MS/Chair †**
Case Comprehensive Cancer Center/
University Hospitals Seidman Cancer
Center and Cleveland Clinic Taussig
Cancer Institute

***Daniel W. Lin, MD/Vice-Chair ω**
Fred Hutchinson Cancer Center

***Nabil Adra, MD, MSc †**
Indiana University Melvin and Bren Simon
Comprehensive Cancer Center

Asim Afaq, MD ∩
UT Southwestern Simmons
Comprehensive Cancer Center

Rahul Aggarwal, MD † ‡ Þ
UCSF Helen Diller Family
Comprehensive Cancer Center

***Aditya Bagrodia, MD ω**
UC San Diego Moores Cancer Center

Thenappan Chandrasekar, MD ω
UC Davis Comprehensive Cancer Center

Alexandra Drakaki, MD, PhD †
UCLA Jonsson Comprehensive Cancer Center

Scott Eggener, MD ω
The UChicago Medicine
Comprehensive Cancer Center

Hamid Emamekhoo, MD †
University of Wisconsin
Carbone Cancer Center

***Darren R. Feldman, MD †**
Memorial Sloan Kettering Cancer Center

Daniel M. Geynisman, MD †
Fox Chase Cancer Center

Laura Graham, MD †
University of Colorado Cancer Center

Peter Humphrey, MD, PhD ≠
Yale Cancer Center/Smilow Cancer Hospital

Daniel Joyce, MD, MS ω
Vanderbilt-Ingram Cancer Center

Christopher Ledbetter, MD ω
St. Jude Children's Research Hospital/
The University of Tennessee Health Science Center

Harshraj Leuva, MBBS ‡
Fred & Pamela Buffett Cancer Center

Ellis G. Levine, MD † ‡
Roswell Park Comprehensive Cancer Center

Benjamin L. Maughan, MD, PharmD †
Huntsman Cancer Institute
at the University of Utah

Bradley McGregor, MD †
Dana-Farber/Brigham and
Women's Cancer Center

Paul Monk, MD †
The Ohio State University Comprehensive
Cancer Center - James Cancer Hospital
and Solove Research Institute

Charles Peyton, MD ω
O'Neal Comprehensive
Cancer Center at UAB

Joel Picus, MD ‡
Siteman Cancer Center at Barnes-
Jewish Hospital and Washington
University School of Medicine

Phillip Pierorazio, MD ω
Abramson Cancer Center
at the University of Pennsylvania

Zachery Reichert, MD, PhD † Þ
University of Michigan
Rogel Cancer Center

Jean-Claude Rwigema, MD §
Mayo Clinic Comprehensive Cancer Center

Philip Saylor, MD †
Mass General Cancer Center

Ankeet Shah, MD † ω
Duke Cancer Institute

Sumit Shah, MD, MPH ‡
Stanford Cancer Institute

Nirmish Singla, MD, MSc ω
Johns Hopkins Kimmel Cancer Center

Kanishka Sircar, MD ≠
The University of Texas
MD Anderson Cancer Center

David VanderWeele, MD, PhD †
Robert H. Lurie Comprehensive Cancer
Center of Northwestern University

***Kosj Yamoah, MD, PhD §**
Moffitt Cancer Center

Ali Zhumkhawala, MD ω
City of Hope National Medical Center

NCCN
Sarah Montgomery, BA
Bailee Sliker, PhD

‡ Hematology/Hematology oncology
Þ Internal medicine
† Medical oncology
≠ Pathology
∩ Radiology/Diagnostic radiology
§ Radiotherapy/Radiation oncology
ω Urology
* Discussion writing committee member

NCCN Guidelines Panel Disclosures

PLEASE NOTE that use of this NCCN Content is governed by the End-User License Agreement, and you MAY NOT distribute this Content or use it with any artificial intelligence model or tool.
Printed by Máximo López Chenlo on 5/4/2026 6:31:34 PM. Copyright © 2026 National Comprehensive Cancer Network, Inc. All Rights Reserved.

NCCN Guidelines Version 1.2026 Testicular Cancer

NCCN Testicular Cancer Panel Members
Summary of the Guidelines Updates

Workup, Primary Treatment, and Pathologic Diagnosis (TEST-1)
Pure Seminoma: Postdiagnostic Workup and Clinical Stage (SEM-1)
- Stage IA, IB, and IS (SEM-2)
- Stage IIA and IIB (SEM-3)
- Stage IIC and III (SEM-4)
- Post First-Line Chemotherapy Management (SEM-5)
- Recurrence and Second-Line Therapy (SEM-6)
- Post Second-Line Therapy Management (SEM-7)
- Third-Line Therapy (SEM-8)

Nonseminoma: Postdiagnostic Workup and Clinical Stage (NSEM-1)
- Stage I With and Without Risk Factors, Stage IS (NSEM-2)
- Stage IIA and IIB (NSEM-3)
- Post First-Line Chemotherapy Management (NSEM-4)
- Postsurgical Management (NSEM-5)
- Stage IS, IIA, IIB, IIC, IIIA, IIIB, IIIC, and Brain Metastases (NSEM-6)
- Postchemotherapy Management of Partial Response to Primary Treatment (NSEM-7)
- Recurrence and Second-Line Therapy (NSEM-8)
- Post Second-Line Therapy Management (NSEM-9)
- Third-Line Therapy (NSEM-10)

Follow-up for Seminoma (TEST-A)
Follow-up for Nonseminoma (TEST-B)
Principles of Radiotherapy for Pure Testicular Seminoma (TEST-C)
Risk Classification for Advanced Disease (TEST-D)
First-Line Chemotherapy Regimens for Germ Cell Tumors (TEST-E)
Second-Line Chemotherapy Regimens for Metastatic Germ Cell Tumors (TEST-F)
Third-Line Systemic Therapy Regimens for Metastatic Germ Cell Tumors (TEST-G)
Principles of Surgery for Germ Cell Tumors (TEST-H)
Principles of Imaging (TEST-I)

Staging (ST-1)

Abbreviations (ABBR-1)

Find an NCCN Member Institution: https://www.nccn.org/home/member-institutions.

NCCN Categories of Evidence and Consensus: All recommendations are category 2A unless otherwise indicated.

See NCCN Categories of Evidence and Consensus.

NCCN Categories of Preference: All recommendations are considered appropriate.

See NCCN Categories of Preference.

The NCCN Guidelines® are a statement of evidence and consensus of the authors regarding their views of currently accepted approaches to treatment. Any clinician seeking to apply or consult the NCCN Guidelines is expected to use independent medical judgment in the context of individual clinical circumstances to determine any patient's care or treatment. The National Comprehensive Cancer Network® (NCCN®) makes no representations or warranties of any kind regarding their content, use or application and disclaims any responsibility for their application or use in any way. The NCCN Guidelines are copyrighted by National Comprehensive Cancer Network®. All rights reserved. The NCCN Guidelines and the illustrations herein may not be reproduced in any form without the express written permission of NCCN. ©2025.

PLEASE NOTE that use of this NCCN Content is governed by the End-User License Agreement, and you MAY NOT distribute this Content or use it with any artificial intelligence model or tool.
Printed by Máximo López Chenlo on 5/4/2026 6:31:34 PM. Copyright © 2026 National Comprehensive Cancer Network, Inc. All Rights Reserved.

Updates in Version 1.2026 of the NCCN Guidelines for Testicular Cancer from Version 2.2025 include:

Global Updates
- References have been updated throughout the Guidelines.

SEM-1
- Footnote c added: Consider referral to social work. Refer to the NCCN Distress Thermometer and Problem List, which includes social determinants of health. See NCCN Guidelines for Distress Management (DIS-A). See Discussion. (Also for NSEM-1)
- Footnote e modified: "Elevations of AFP either pre- or post-orchiectomy indicate the presence of nonseminomatous elements. *The expected half-life for AFP is 5-7 days.* For patients with elevated pre-orchiectomy beta-hCG levels, beta-hCG levels should be followed with repeated..." (Also for footnote f on NSEM-1)

SEM-2
- Stage IS
  - Bullet 1 modified: Chest/abdomen/pelvis (C/A/P) CT (with contrast) ~~or MRI (with and without contrast)~~ to scan for evaluable disease
  - Bullet added: Repeat scrotal ultrasound to rule out a contralateral testis mass if one has not been conducted in the last 3 months

SEM-3
- Stage IIA/IIB, Nerve-sparing RPLND
  - pN0 treatment option added: Surveillance
  - pN1–3 treatment option added: Surveillance or Adjuvant chemotherapy
- Footnote r modified: Providers should engage in shared decision-making for stage IIA*/IIB* seminoma that includes informing patients of the recurrence rates and potential for dual therapy with each treatment option.
- Footnote aa added: Chemotherapy is based on data from nonseminoma and includes EP for 2 cycles. This is an evolving field and data are still needed to provide a definitive option.

SEM-4
- Footnote ee modified: Consider intensification of therapy for patients with good risk and an LDH >2.5 times the upper limit of normal (ULN). *See Discussion.*

SEM-5
- Residual mass (>3 cm) and normal serum AFP and beta-hCG
  - Positive post first-line chemotherapy management option modified: Repeat imaging in 6–~~8~~ *12* weeks (Also for SEM-7)

SEM-6
- Second-line therapy option modified: Clinical trial ~~(preferred)~~

SEM-8
- Prior first- and second-line conventional-dose chemotherapy
  - Third-line therapy option modified: Molecular testing ~~(including microsatellite instability (MSI)/mismatch repair (MMR) and tumor mutational burden (TMB) testing)~~ for *biomarker-driven* therapy if progression
  - Third-line therapy option added: Consider surgical treatment if resectable solitary site
- Prior high-dose chemotherapy
  - Third-line therapy option modified: Molecular testing ~~(including MSI/MMR and TMB testing)~~ for *biomarker-driven* therapy if progression
  - Third-line therapy option added: Consider surgical treatment if resectable solitary site
- Footnote rr added: Should include both NGS and IHC testing.

Continued

Version 1.2026, 10/15/2025 © 2025 National Comprehensive Cancer Network® (NCCN®), All rights reserved. NCCN Guidelines® and this illustration may not be reproduced in any form without the express written permission of NCCN.

PLEASE NOTE that use of this NCCN Content is governed by the End-User License Agreement, and you MAY NOT distribute this Content or use it with any artificial intelligence model or tool.
Printed by Máximo López Chenlo on 5/4/2026 6:31:34 PM. Copyright © 2026 National Comprehensive Cancer Network, Inc. All Rights Reserved.

Updates in Version 1.2026 of the NCCN Guidelines for Testicular Cancer from Version 2.2025 include:

NSEM-2
- Footnote j modified: "RPLND is preferred as primary treatment for stage ~~II~~ *I* germ cell tumors..."
- Footnote k added: Repeat scrotal ultrasound to rule out a contralateral testis mass if one has not been conducted in the last 3 months.

NSEM-4
- Footnote t modified: Patients with subcentimeter residual nodes who have teratoma or yolk sac tumor in their primary tumor *may be at higher risk of teratoma or viable germ cell elements in the post-chemotherapy residual nodes. More data are still needed to know if they are at a higher risk of relapse or worse outcomes. See Discussion.*

NSEM-6
- Footnote dd modified: Recommend referral to a high-volume center *for residual masses with abnormal AFP and/or beta-hCG levels.*

NSEM-7
- Partial response, residual masses with normal AFP and beta-hCG levels
  - Residual embryonal, yolk sac, choriocarcinoma, or seminoma element, postchemotherapy management option modified: Chemotherapy ~~(preferred)~~ for 2 cycles (EP or TIP or VIP or VeIP)
- Partial response, residual masses with abnormal AFP and/or beta-hCG levels
  - Elevated and rising AFP and/or beta-hCG levels, postchemotherapy management option added: Surgery in highly select cases
  - Elevated but stable AFP and/or beta-hCG levels, postchemotherapy management option added: Surgery in highly select cases
  - Mildly elevated and normalizing AFP and/or beta-hCG levels
    - Residual embryonal, yolk sac, choriocarcinoma, or seminoma element, postchemotherapy option modified: Chemotherapy ~~(preferred)~~ for 2 cycles (EP or TIP or VIP or VeIP)

NSEM-7A
- Footnote hh added: Presentation of resectable retroperitoneal-only disease, significant factors that preclude chemotherapy use, and/or presence of cystic components.

NSEM-8
- Prior first-line chemotherapy
  - Early relapse (recurrence ≤2 years after completion of primary treatment), second-line therapy option modified: Clinical trial ~~(preferred)~~
- Footnote ll added: For select patients, RPLND may be appropriate.

NSEM-10
- Prior second-line chemotherapy
  - Prior high-dose chemotherapy, third-line therapy option modified: Molecular testing ~~(including MSI/MMR and TMB testing)~~ for *biomarker-driven* therapy if progression
- Footnote nn added: Should include both NGS and IHC testing.

TEST-B (2 of 3)
- Table 10 header modified: Clinical Stage II–III NSGCT: Surveillance After Chemotherapy ± ~~Chemotherapy~~ Surgery
- Footnote g modified: *In year 2, this is* optional for patients treated with primary RPLND.

TEST-B (3 of 3)
- Footnote p modified: Patients with clinical stage IIA/IIB nonseminoma who undergo primary RPLND and are found to have pN0 disease (no cancer and no teratoma, pathologic stage I) should revert to the surveillance schedule for low-risk NSGCT with the exception that only 1 CT scan is needed postoperatively around month 4 (Table ~~5~~ *9*).

Continued

Version 1.2026, 10/15/2025 © 2025 National Comprehensive Cancer Network® (NCCN®), All rights reserved. NCCN Guidelines® and this illustration may not be reproduced in any form without the express written permission of NCCN.

PLEASE NOTE that use of this NCCN Content is governed by the End-User License Agreement, and you MAY NOT distribute this Content or use it with any artificial intelligence model or tool.
Printed by Máximo López Chenlo on 5/4/2026 6:31:34 PM. Copyright © 2026 National Comprehensive Cancer Network, Inc. All Rights Reserved.

Updates in Version 1.2026 of the NCCN Guidelines for Testicular Cancer from Version 2.2025 include:

TEST-G (1 of 3)
- High-Dose Chemotherapy NOT Previously Received
  - Bullet 1 added: Pan-cancer, tumor-agnostic treatments can be considered for patients with actionable mutations. (Also for TEST-G 2 of 3)
  - Useful in certain circumstances, regimen removed: Pembrolizumab (for MSI-high [MSI-H]/MMR deficient [dMMR] or TMB-high [TMB-H] tumors) (Also for TEST-G 2 of 3, High-Dose Chemotherapy Previously Received)
  - Footnotes
    - Footnote a added: Studies on other regimens in this setting have been published that could be useful in certain circumstances. See Discussion for more information. (Also for TEST-G 2 of 3)
    - Footnote removed: Pan-cancer, tumor-agnostic treatments can be considered for patients with actionable mutations. (Also for TEST-G 2 of 3)
    - Footnote removed: TMB-H [≥10 mutations/megabase (mut/Mb)] tumors, as determined by a validated and/or FDA-approved comprehensive genomic profiling (CGP) assay. (Also for TEST-G 2 of 3)

TEST-H (1 of 2)
- Page has been significantly revised

TEST-H (2 of 2)
- Page has been significantly revised

TEST-I
- Treatment Response Assessment
  - Bullet 2, sub-bullet 1 modified: "...An alternative is to wait an additional ~~8~~ *6*–12 weeks and repeat imaging to assess for changes. If the mass is persistently positive then resection or biopsy is recommended."

Continued

Version 1.2026, 10/15/2025 © 2025 National Comprehensive Cancer Network® (NCCN®), All rights reserved. NCCN Guidelines® and this illustration may not be reproduced in any form without the express written permission of NCCN.

PLEASE NOTE that use of this NCCN Content is governed by the End-User License Agreement, and you MAY NOT distribute this Content or use it with any artificial intelligence model or tool.
Printed by Máximo López Chenlo on 5/4/2026 6:31:34 PM. Copyright © 2026 National Comprehensive Cancer Network, Inc. All Rights Reserved.

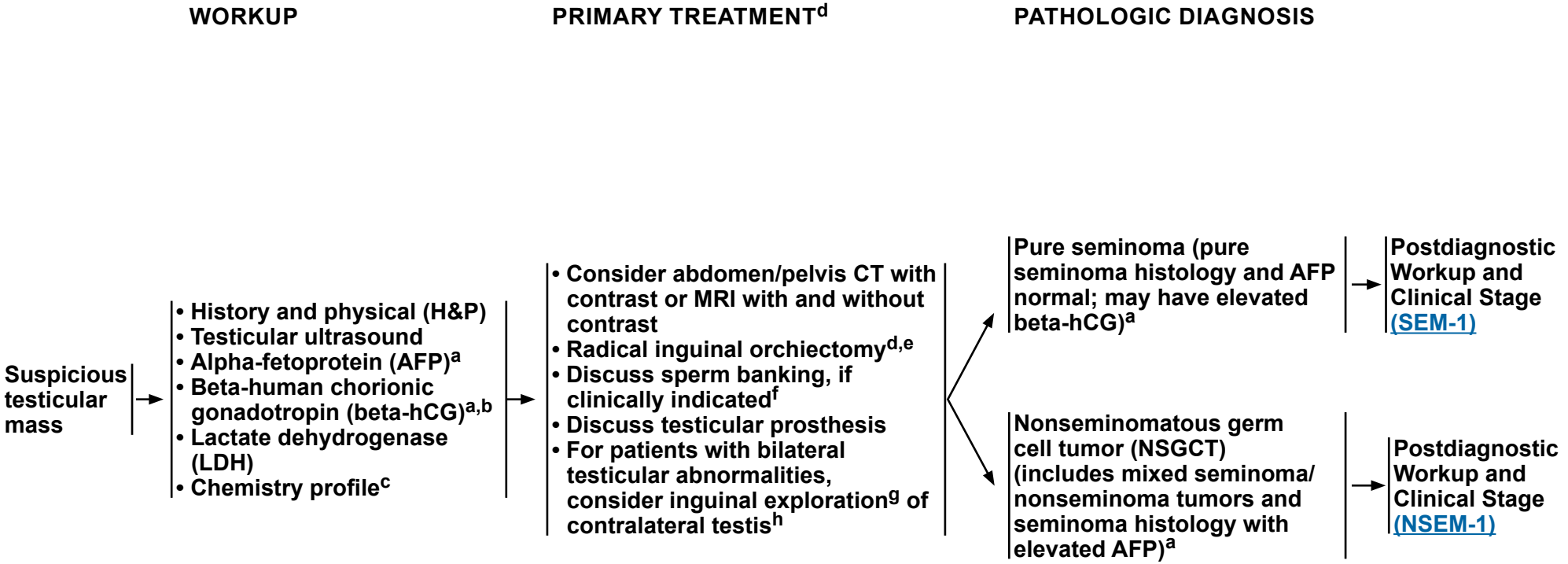

[a] Mildly elevated, non-rising AFP levels may not indicate presence of germ cell tumor. Decisions to treat should not be based solely on AFP values <20 ng/mL. More highly elevated AFP levels generally indicate the presence of nonseminomatous tumor elements. Further workup should be considered before initiating treatment for mildly elevated beta-hCG (generally <20 IU/L) since other factors, including hypogonadism and cannabis use, can cause false-positive results. See Discussion.

[b] Quantitative analysis of beta subunit.

[c] Consider measuring baseline levels of gonadal function.

[d] Although rare, when a patient presents with rapidly increasing beta-hCG or AFP and symptoms related to disseminated disease with a testicular mass, chemotherapy can be initiated immediately without waiting for a biopsy diagnosis or performing orchiectomy. However, orchiectomy should be performed at completion of chemotherapy.

[e] May consider testis-sparing surgery (TSS) (ie, partial orchiectomy) in select patients. See Principles of Surgery (TEST-H).

[f] For patients wishing to preserve fertility, sperm banking is recommended prior to chemotherapy, radiation therapy (RT), or retroperitoneal lymph node dissection (RPLND). For patients with a single testicle and patients undergoing bilateral orchiectomy, sperm banking is recommended prior to orchiectomy.

[g] Inguinal exploration with exposure of testis, with direct observation and partial orchiectomy. See Principles of Surgery (TEST-H).

[h] If ultrasound shows cryptorchid testis, marked atrophy, or suspicious mass. Biopsies are not recommended for microcalcifications.

Note: All recommendations are category 2A unless otherwise indicated.

Version 1.2026, 10/15/2025 © 2025 National Comprehensive Cancer Network® (NCCN®), All rights reserved. NCCN Guidelines® and this illustration may not be reproduced in any form without the express written permission of NCCN.

PLEASE NOTE that use of this NCCN Content is governed by the End-User License Agreement, and you MAY NOT distribute this Content or use it with any artificial intelligence model or tool.
Printed by Máximo López Chenlo on 5/4/2026 6:31:34 PM. Copyright © 2026 National Comprehensive Cancer Network, Inc. All Rights Reserved.

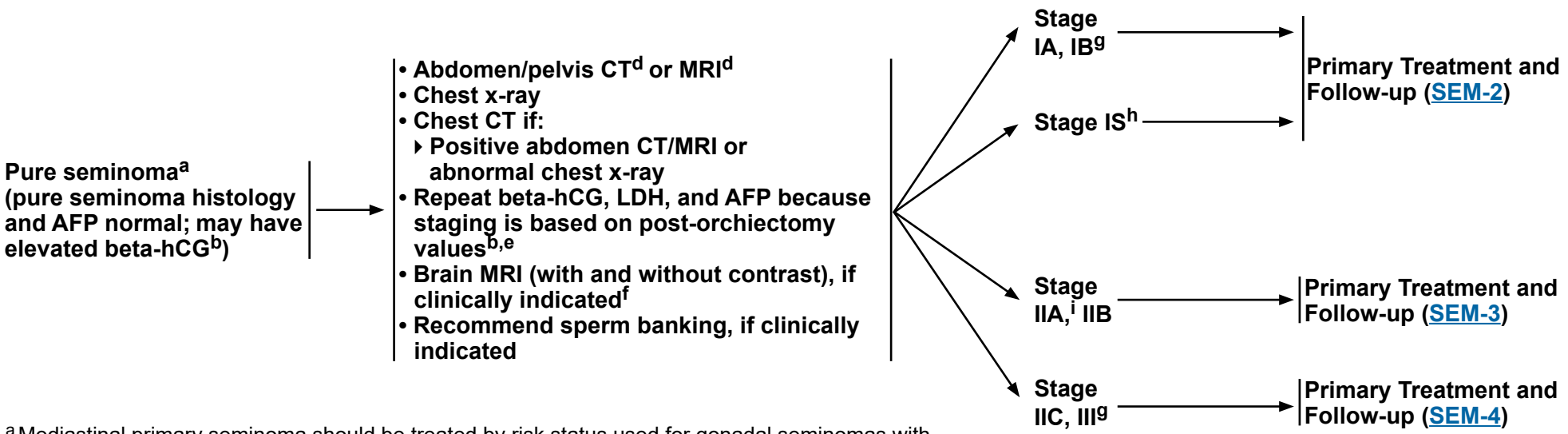

[a] Mediastinal primary seminoma should be treated by risk status used for gonadal seminomas with etoposide/cisplatin for 4 cycles or bleomycin/etoposide/cisplatin for 3 cycles.

[b] Mildly elevated, non-rising AFP levels may not indicate presence of germ cell tumor. Decisions to treat should not be based solely on AFP values <20 ng/mL. More highly elevated AFP levels generally indicate the presence of nonseminomatous tumor elements. Further workup should be considered before initiating treatment for mildly elevated beta-hCG (generally <20 IU/L) since other factors, including hypogonadism and cannabis use, can cause false-positive results. See Discussion.

[c] Consider referral to social work. Refer to the NCCN Distress Thermometer and Problem List, which includes social determinants of health. See NCCN Guidelines for Distress Management (DIS-A). See Discussion.

[d] CT with contrast or MRI with and without contrast should be performed unless performed prior to orchiectomy.

[e] Elevations of AFP either pre- or post-orchiectomy indicate the presence of nonseminomatous elements. The expected half-life for AFP is 5–7 days. For patients with elevated pre-orchiectomy beta-hCG levels, beta-hCG levels should be followed with repeated determinations after orchiectomy to determine their trajectory and, if declining, their nadir. The expected half-life for beta-hCG is ≤3 days. For patients with normal imaging (ie, stage I), rising or persistently elevated beta-hCG levels generally indicate the presence of metastatic disease (stage IS). For patients with metastatic disease to the retroperitoneum or beyond (stage II or III), highly elevated post-orchiectomy beta-hCG (>1000 IU/L) levels may indicate the presence of nonseminomatous tumor elements. See Discussion.

[f] Eg, beta-hCG >5000 IU/L, non-pulmonary visceral metastases, extensive lung metastasis, or neurologic symptoms present.

[g] The Panel recommends staging tumors with discontinuous invasion of the spermatic cord as pT3 (high-risk stage I) and not as M1 (stage III) as is recommended in the 8th edition of the AJCC Cancer Staging Manual. If surveillance is elected, the pelvis should be included in the imaging due to a higher risk of pelvic relapses in these patients. See Discussion.

[h] For further information on stage IS, see Discussion.

[i] For select cases of clinical stage IIA disease with borderline retroperitoneal lymph nodes, waiting 4–8 weeks and repeating imaging (CT or MRI) to confirm staging before initiating treatment can be considered.

Note: All recommendations are category 2A unless otherwise indicated.

Version 1.2026, 10/15/2025 © 2025 National Comprehensive Cancer Network® (NCCN®), All rights reserved. NCCN Guidelines® and this illustration may not be reproduced in any form without the express written permission of NCCN.

PLEASE NOTE that use of this NCCN Content is governed by the End-User License Agreement, and you MAY NOT distribute this Content or use it with any artificial intelligence model or tool.
Printed by Máximo López Chenlo on 5/4/2026 6:31:34 PM. Copyright © 2026 National Comprehensive Cancer Network, Inc. All Rights Reserved.

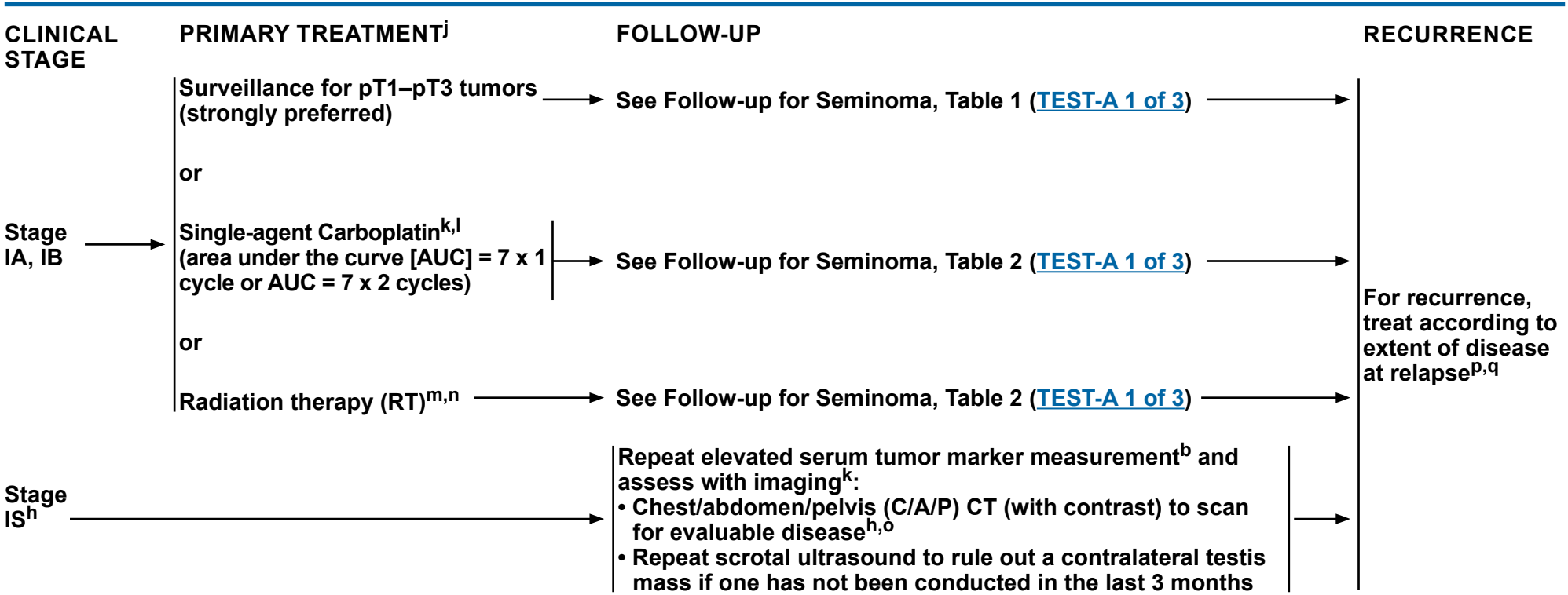

[b] Mildly elevated, non-rising AFP levels may not indicate presence of germ cell tumor. Decisions to treat should not be based solely on AFP values <20 ng/mL. More highly elevated AFP levels generally indicate the presence of nonseminomatous tumor elements. Further workup should be considered before initiating treatment for mildly elevated beta-hCG (generally <20 IU/L) since other factors, including hypogonadism and cannabis use, can cause false-positive results. See Discussion.

[h] For further information on stage IS, see Discussion.

[j] Discuss sperm banking prior to chemotherapy or radiation treatment.

[k] Recommend imaging within the 4 weeks prior to the initiation of chemotherapy to confirm staging, even if the scan was done previously. See Principles of Imaging (TEST-I).

[l] There are limited long-term follow-up data on the toxicity and efficacy of carboplatin. A recent population-based study suggested patients with larger tumors, rete testis involvement, or both derive a smaller reduction in relapse rate with 1 cycle of carboplatin than previously reported. See Discussion.

[m] Principles of Radiotherapy for Pure Testicular Seminoma (TEST-C).

[n] For stage I seminoma, long-term follow-up studies indicate an increase in late toxicities with radiation treatment. See Discussion.

[o] Elevated tumor markers increase the risk of disease outside of the retroperitoneum. Therefore, systemic therapy should be encouraged. See First-Line Chemotherapy Regimens for Germ Cell Tumors (TEST-E).

[p] Patients should not be treated based upon an elevated LDH alone.

[q] Patients previously on surveillance can be treated with RT or chemotherapy (depending on the extent of disease). Patients who received carboplatin or RT should be treated with first-line cisplatin-based chemotherapy. See First-Line Chemotherapy Regimens for Germ Cell Tumors (TEST-E).

Note: All recommendations are category 2A unless otherwise indicated.

Version 1.2026, 10/15/2025 © 2025 National Comprehensive Cancer Network® (NCCN®), All rights reserved. NCCN Guidelines® and this illustration may not be reproduced in any form without the express written permission of NCCN.

PLEASE NOTE that use of this NCCN Content is governed by the End-User License Agreement, and you MAY NOT distribute this Content or use it with any artificial intelligence model or tool.
Printed by Máximo López Chenlo on 5/4/2026 6:31:34 PM. Copyright © 2026 National Comprehensive Cancer Network, Inc. All Rights Reserved.

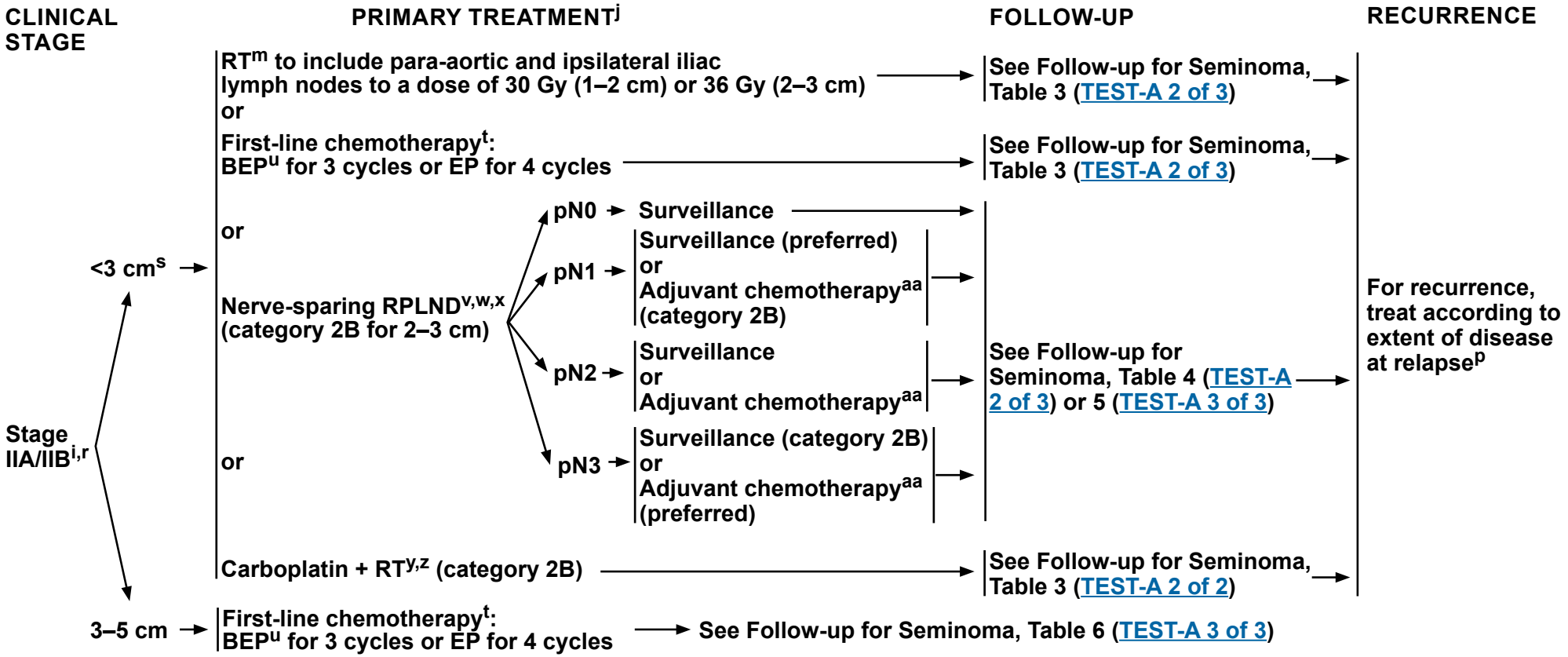

BEP = Bleomycin/Etoposide/Cisplatin
EP = Etoposide/Cisplatin

[i] For select cases of clinical stage IIA disease with borderline retroperitoneal lymph nodes, waiting 4–8 weeks and repeating imaging (CT or MRI) to confirm staging before initiating treatment can be considered.
[j] Discuss sperm banking prior to chemotherapy or radiation treatment.
[m] Principles of Radiotherapy for Pure Testicular Seminoma (TEST-C).
[p] Patients should not be treated based upon an elevated LDH alone.
[r] Providers should engage in shared decision-making for stage IIA/IIB seminoma that includes informing patients of the recurrence rates and potential for dual therapy with each treatment option.
[s] For nonbulky IIB, <3 cm in transaxial long axis.
[t] First-Line Chemotherapy Regimens for Germ Cell Tumors (TEST-E).
[u] Consider a bleomycin-free regimen in patients at increased risk for bleomycin toxicity, such as those with reduced glomerular filtration rate (GFR) or older age. See Discussion.
[v] Principles of Surgery for Germ Cell Tumors (TEST-H).
[w] All locoregional treatment is recommended within 4 weeks of CT or MRI and within 2 weeks of confirmation of normal tumor markers.
[x] Recommend referral to a high-volume center.
[y] Late toxicities should be considered as current studies only extend out to 3 years.
[z] Papachristofilou A, et al. Lancet Oncol 2022;23:1441-1450.
[aa] Chemotherapy is based on data from nonseminoma and includes EP for 2 cycles. This is an evolving field and data are still needed to provide a definitive option.

Note: All recommendations are category 2A unless otherwise indicated.

Version 1.2026, 10/15/2025 © 2025 National Comprehensive Cancer Network® (NCCN®), All rights reserved. NCCN Guidelines® and this illustration may not be reproduced in any form without the express written permission of NCCN.

PLEASE NOTE that use of this NCCN Content is governed by the End-User License Agreement, and you MAY NOT distribute this Content or use it with any artificial intelligence model or tool.
Printed by Máximo López Chenlo on 5/4/2026 6:31:34 PM. Copyright © 2026 National Comprehensive Cancer Network, Inc. All Rights Reserved.

CLINICAL STAGE[bb]	PRIMARY TREATMENT[j]	FOLLOW-UP
Stage IIC, III[cc] → Good risk[dd,ee]	First-line chemotherapy[t]: BEP[u] for 3 cycles (category 1) or EP for 4 cycles (category 1)	Post First-Line Chemotherapy Management and Follow-up (SEM-5)
Stage IIC, III[cc] → Intermediate risk[bb,dd]	First-line chemotherapy[t]: BEP[u] for 4 cycles (category 1, preferred) or VIP for 4 cycles	

BEP = Bleomycin/Etoposide/Cisplatin
EP = Etoposide/Cisplatin
VIP = Etoposide/Ifosfamide/Cisplatin

[j] Discuss sperm banking prior to chemotherapy or radiation treatment.
[t] First-Line Chemotherapy Regimens for Germ Cell Tumors (TEST-E).
[u] Consider a bleomycin-free regimen in patients at increased risk for bleomycin toxicity, such as those with reduced GFR or older age. See Discussion.
[bb] Intermediate risk in seminoma is based on metastases to organs other than the lungs (stage IIIC). Stage IIIB does not apply to pure seminomas. Patients with elevated AFP have nonseminomas. In patients with a serum beta-hCG >1000 IU/L, consider the possibility of a nonseminoma, re-review surgical specimen with pathology, and consider discussion with a high-volume center. Beta-hCG alone should not be used to stage or risk stratify patients with pure seminoma. Use of LDH to risk stratify metastatic seminoma is controversial. See Discussion.
[cc] All stage IIC and stage III seminomas are considered good-risk disease except for stage III disease with non-pulmonary visceral metastases (eg, bone, liver, brain), which is considered intermediate risk.
[dd] Risk Classification for Advanced Disease (TEST-D).
[ee] Consider intensification of therapy for patients with good risk and an LDH >2.5 times the upper limit of normal (ULN). See Discussion.

Note: All recommendations are category 2A unless otherwise indicated.

Version 1.2026, 10/15/2025 © 2025 National Comprehensive Cancer Network® (NCCN®), All rights reserved. NCCN Guidelines® and this illustration may not be reproduced in any form without the express written permission of NCCN.

PLEASE NOTE that use of this NCCN Content is governed by the End-User License Agreement, and you MAY NOT distribute this Content or use it with any artificial intelligence model or tool.
Printed by Máximo López Chenlo on 5/4/2026 6:31:34 PM. Copyright © 2026 National Comprehensive Cancer Network, Inc. All Rights Reserved.

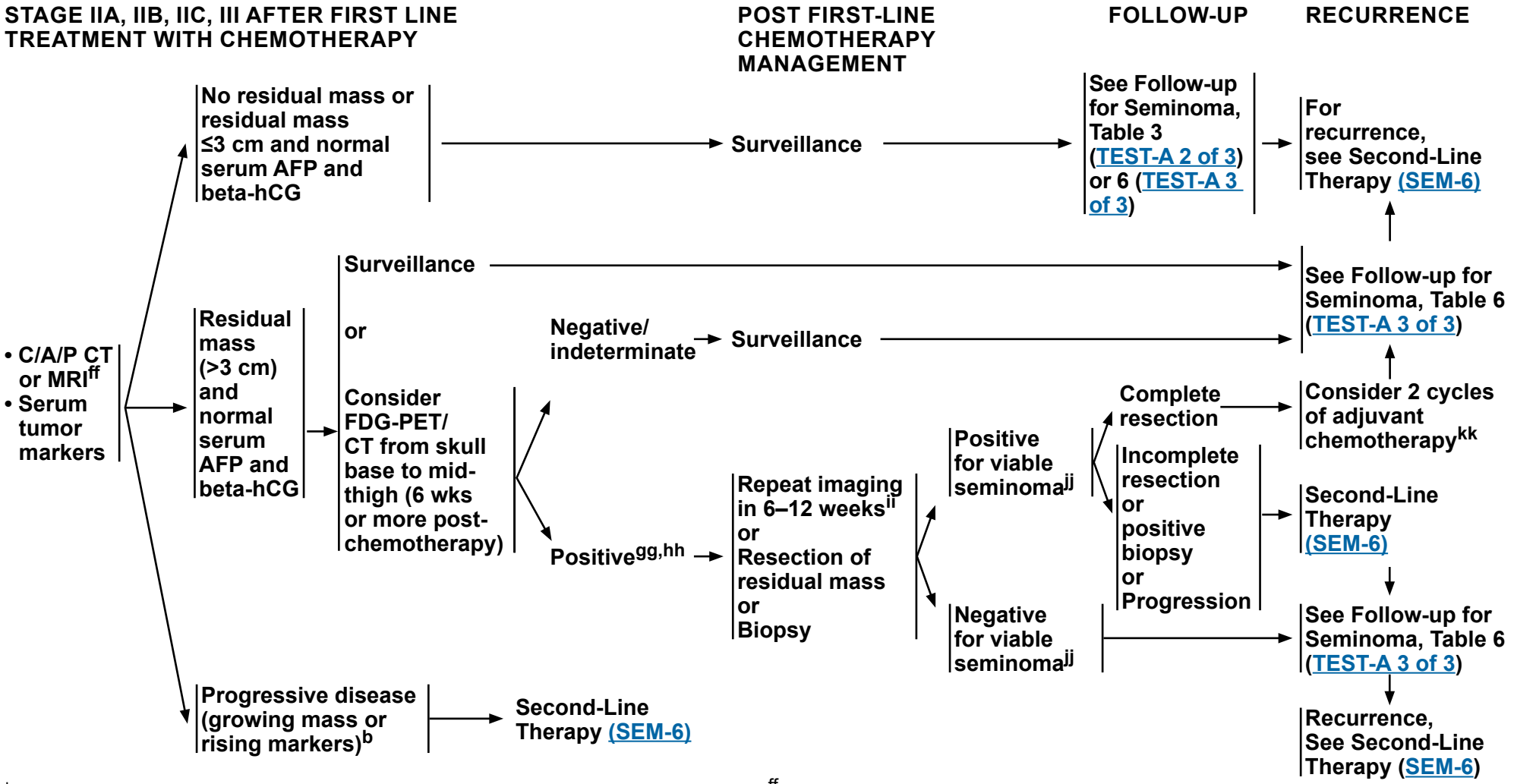

[b] Mildly elevated, non-rising AFP levels may not indicate presence of germ cell tumor. Decisions to treat should not be based solely on AFP values <20 ng/mL. More highly elevated AFP levels generally indicate the presence of nonseminomatous tumor elements. Further workup should be considered before initiating treatment for mildly elevated beta-hCG (generally <20 IU/L) since other factors, including hypogonadism and cannabis use, can cause false-positive results. See Discussion.

[ff] CT with contrast or MRI with and without contrast.
[gg] Principles of Imaging (TEST-I).
[hh] Consider referral to a high-volume center.
[ii] If persistently positive, proceed with resection or biopsy.
[jj] In rare cases, nonseminomatous elements will be identified. If they are non-teratomatous, then proceed in the same fashion as for viable seminoma above.
[kk] EP or TIP or VIP or VeIP.

Note: All recommendations are category 2A unless otherwise indicated.

Version 1.2026, 10/15/2025 © 2025 National Comprehensive Cancer Network® (NCCN®), All rights reserved. NCCN Guidelines® and this illustration may not be reproduced in any form without the express written permission of NCCN.

PLEASE NOTE that use of this NCCN Content is governed by the End-User License Agreement, and you MAY NOT distribute this Content or use it with any artificial intelligence model or tool.
Printed by Máximo López Chenlo on 5/4/2026 6:31:34 PM. Copyright © 2026 National Comprehensive Cancer Network, Inc. All Rights Reserved.

RECURRENCE[ll]

SECOND-LINE THERAPY[mm,nn]

Prior first-line chemotherapy →

- **Clinical trial**
- **Chemotherapy[oo]**
  - **Conventional-dose second-line chemotherapy (VeIP for 4 cycles or TIP for 4 cycles)**
  - **High-dose chemotherapy**
- **Recommend sperm banking if clinically indicated[pp]**

→ **Post Second-Line Therapy Management (SEM-7)**

- **TIP = Paclitaxel/Ifosfamide/Cisplatin**
- **VeIP = Vinblastine/Ifosfamide/Cisplatin**

[ll] It is preferred that patients with recurrent seminoma be treated at centers with expertise in the management of this disease.

[mm] To assess response after treatment, CT with contrast or MRI with and without contrast of C/A/P and any other sites of disease is recommended. FDG-PET/CT from skull base to mid thigh may also be considered in assessing treatment response and residual masses following chemotherapy in patients with seminoma.

[nn] Includes best supportive care and palliative care. See NCCN Guidelines for Palliative Care.

[oo] Second-Line Chemotherapy Regimens for Metastatic Germ Cell Tumors (TEST-F).

[pp] Patients should wait at least 6 months post-chemotherapy to conceive a child or up to 2 years under extreme caution. While more data are needed in this space, the Panel believes these recommendations are currently well supported.

Note: All recommendations are category 2A unless otherwise indicated.

Version 1.2026, 10/15/2025 © 2025 National Comprehensive Cancer Network® (NCCN®), All rights reserved. NCCN Guidelines® and this illustration may not be reproduced in any form without the express written permission of NCCN.

PLEASE NOTE that use of this NCCN Content is governed by the End-User License Agreement, and you MAY NOT distribute this Content or use it with any artificial intelligence model or tool.
Printed by Máximo López Chenlo on 5/4/2026 6:31:34 PM. Copyright © 2026 National Comprehensive Cancer Network, Inc. All Rights Reserved.

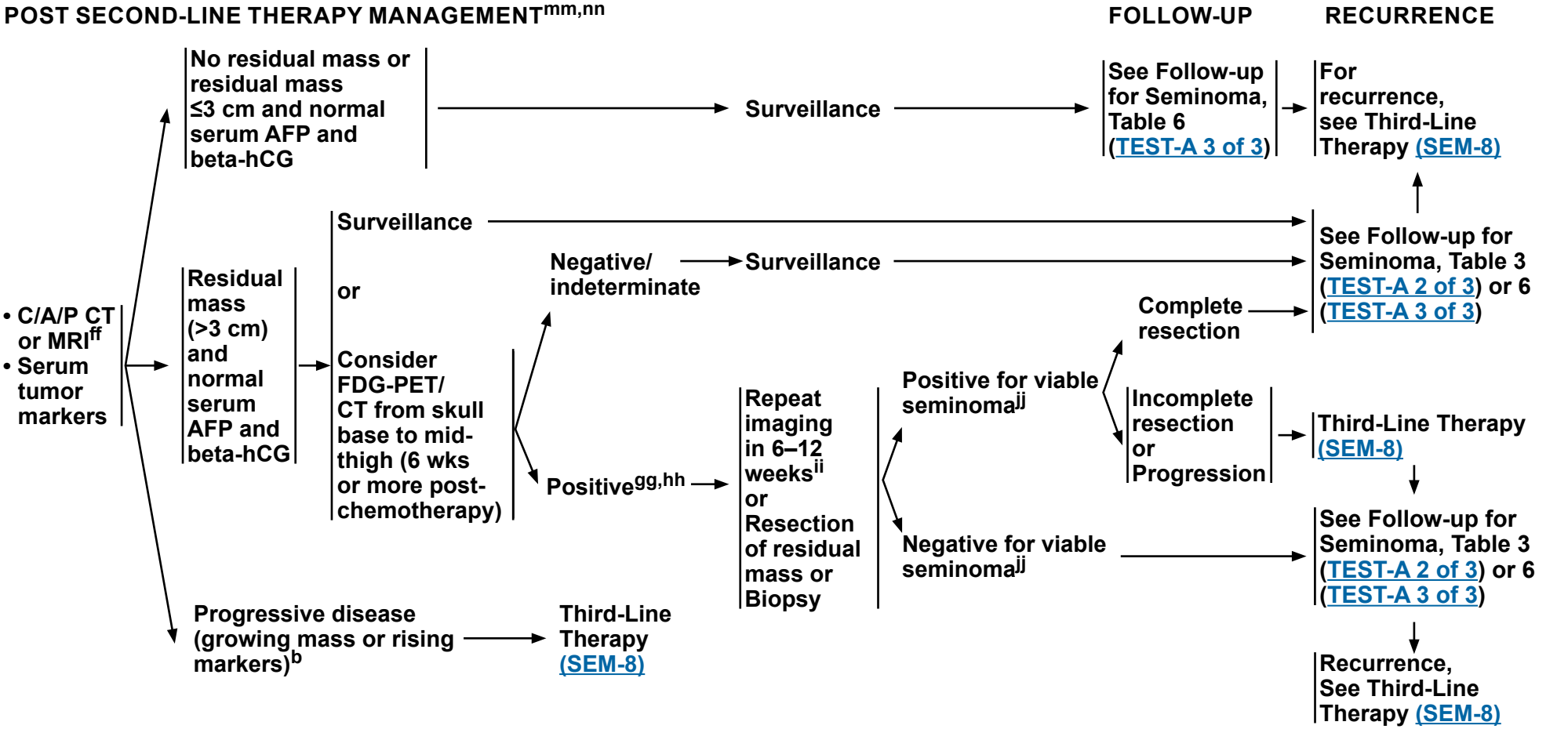

[b] Mildly elevated, non-rising AFP levels may not indicate presence of germ cell tumor. Decisions to treat should not be based solely on AFP values <20 ng/mL. More highly elevated AFP levels generally indicate the presence of nonseminomatous tumor elements. Further workup should be considered before initiating treatment for mildly elevated beta-hCG (generally <20 IU/L) since other factors, including hypogonadism and cannabis use, can cause false-positive results. See Discussion.

[ff] CT with contrast or MRI with and without contrast.

[gg] Principles of Imaging (TEST-I).

[hh] Consider referral to a high-volume center.

[ii] If persistently positive, proceed with resection or biopsy.

[jj] In rare cases, nonseminomatous elements will be identified. If they are non-teratomatous, then proceed in the same fashion as for viable seminoma above.

[mm] To assess response after treatment, CT with contrast or MRI with and without contrast of C/A/P and any other sites of disease is recommended. FDG-PET/CT from skull base to mid thigh may also be considered in assessing treatment response and residual masses following chemotherapy in patients with seminoma.

[nn] Includes best supportive care and palliative care. See NCCN Guidelines for Palliative Care.

Note: All recommendations are category 2A unless otherwise indicated.

Version 1.2026, 10/15/2025 © 2025 National Comprehensive Cancer Network® (NCCN®), All rights reserved. NCCN Guidelines® and this illustration may not be reproduced in any form without the express written permission of NCCN.

PLEASE NOTE that use of this NCCN Content is governed by the End-User License Agreement, and you MAY NOT distribute this Content or use it with any artificial intelligence model or tool.
Printed by Máximo López Chenlo on 5/4/2026 6:31:34 PM. Copyright © 2026 National Comprehensive Cancer Network, Inc. All Rights Reserved.

RECURRENCE[ll]

THIRD-LINE THERAPY[mm,nn]

Prior second-line chemotherapy

→ **Prior first- and second-line conventional-dose chemotherapy** →

Clinical trial
or
High-dose chemotherapy (preferred)[qq]
or
Conventional-dose third-line chemotherapy[qq]
or
Molecular testing for biomarker-driven therapy if progression[rr,ss,tt]
or
RT in select patients[m]
or
Consider surgical treatment if resectable solitary site

→ **Prior high-dose chemotherapy** →

Clinical trial (preferred)
or
Conventional-dose third-line chemotherapy[qq]
or
Molecular testing for biomarker-driven therapy if progression[rr,ss,tt]
or
RT in select patients[m]
or
Consider surgical treatment if resectable solitary site

[m] Principles of Radiotherapy for Pure Testicular Seminoma (TEST-C).
[ll] It is preferred that patients with recurrent seminoma be treated at centers with expertise in the management of this disease.
[mm] To assess response after treatment, CT with contrast or MRI with and without contrast of C/A/P and any other sites of disease is recommended. FDG-PET/CT from skull base to mid thigh may also be considered in assessing treatment response and residual masses following chemotherapy in patients with seminoma.
[nn] Includes best supportive care and palliative care. See NCCN Guidelines for Palliative Care.
[qq] Third-Line Systemic Therapy Regimens for Metastatic Germ Cell Tumors (TEST-G).
[rr] Should include both NGS and IHC testing.
[ss] Molecular testing is to assess for sensitivity to targeted therapies. See Third-Line Systemic Therapy Regimens for Metastatic Germ Cell Tumors (TEST-G).
[tt] Pan-cancer, tumor-agnostic treatments can be considered for patients with actionable mutations.

Note: All recommendations are category 2A unless otherwise indicated.

Version 1.2026, 10/15/2025 © 2025 National Comprehensive Cancer Network® (NCCN®), All rights reserved. NCCN Guidelines® and this illustration may not be reproduced in any form without the express written permission of NCCN.

PLEASE NOTE that use of this NCCN Content is governed by the End-User License Agreement, and you MAY NOT distribute this Content or use it with any artificial intelligence model or tool.
Printed by Máximo López Chenlo on 5/4/2026 6:31:34 PM. Copyright © 2026 National Comprehensive Cancer Network, Inc. All Rights Reserved.

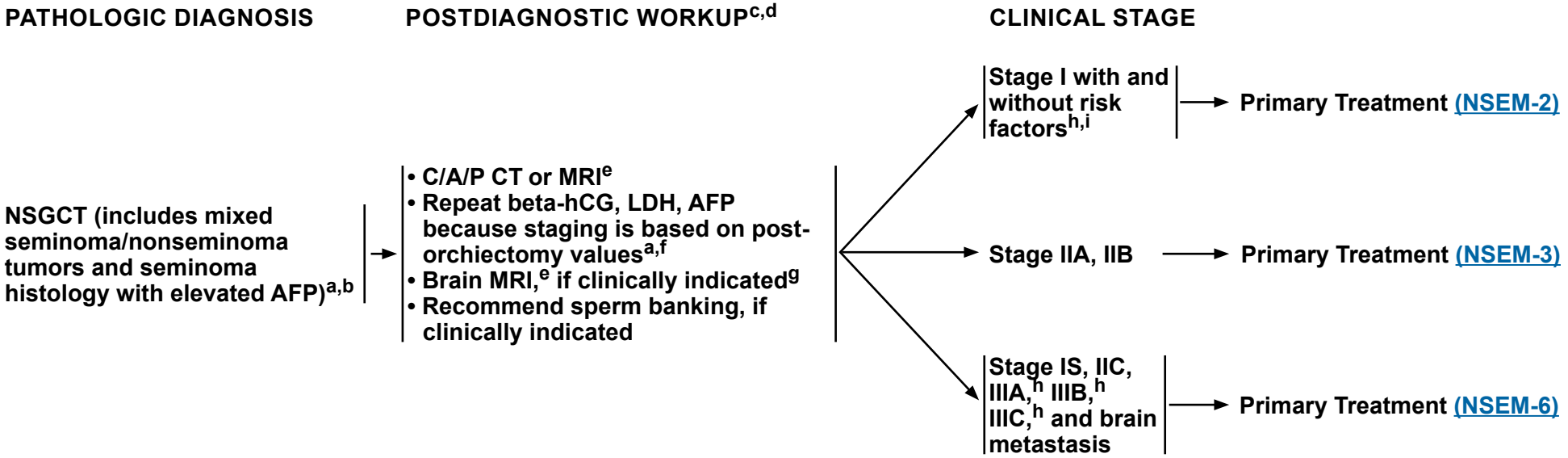

[a] Mildly elevated, non-rising AFP levels may not indicate presence of germ cell tumor. Decisions to treat should not be based solely on AFP values <20 ng/mL. More highly elevated AFP levels generally indicate the presence of nonseminomatous tumor elements. Further workup should be considered before initiating treatment for mildly elevated beta-hCG (generally <20 IU/L) since other factors, including hypogonadism and cannabis use, can cause false-positive results. See Discussion.

[b] Mediastinal primary nonseminoma is poor-risk disease and should be treated with either VIP or BEP with careful pulmonary functioning monitoring. See Discussion.

[c] Consider referral to social work. Refer to the NCCN Distress Thermometer and Problem List, which includes social determinants of health. See NCCN Guidelines for Distress Management (DIS-A). See Discussion.

[d] FDG-PET/CT scan is not clinically indicated for nonseminoma.

[e] CT with contrast and MRI with and without contrast should be performed unless performed prior to orchiectomy.

[f] Elevations of AFP either pre- or post-orchiectomy indicate the presence of nonseminomatous elements. The expected half-life for AFP is 5–7 days. For patents with elevated pre-orchiectomy beta-hCG levels, beta-hCG levels should be followed with repeated determinations after orchiectomy to determine their trajectory and, if declining, their nadir. The expected half-life for beta-hCG is ≤3 days. For patients with normal imaging (ie, stage I), rising or persistently elevated beta-hCG levels generally indicate the presence of metastatic disease (stage IS). For patients with metastatic disease to the retroperitoneum or beyond (stage II or III), highly elevated post-orchiectomy beta-hCG (>1000 IU/L) levels may indicate the presence of non-seminomatous tumor elements. See Discussion.

[g] Eg, beta-hCG >5000 IU/L, extensive lung metastasis, predominance of choriocarcinoma, neurologic symptoms, non-pulmonary visceral metastasis, or AFP >10,000 ng/mL.

[h] The Panel recommends staging tumors with discontinuous invasion of the spermatic cord as pT3 (high-risk stage I) and not as M1 (stage III) as is recommended in the 8th edition of the AJCC Cancer Staging Manual. If surveillance is elected, the pelvis should be included in the imaging due to a higher risk of pelvic relapses in these patients. See Discussion.

[i] Risk factors for recurrence include lymphovascular invasion or invasion of spermatic cord or scrotum. Some centers consider predominance of embryonal carcinoma as an additional risk factor for relapse.

Note: All recommendations are category 2A unless otherwise indicated.

Version 1.2026, 10/15/2025 © 2025 National Comprehensive Cancer Network® (NCCN®), All rights reserved. NCCN Guidelines® and this illustration may not be reproduced in any form without the express written permission of NCCN.

PLEASE NOTE that use of this NCCN Content is governed by the End-User License Agreement, and you MAY NOT distribute this Content or use it with any artificial intelligence model or tool.
Printed by Máximo López Chenlo on 5/4/2026 6:31:34 PM. Copyright © 2026 National Comprehensive Cancer Network, Inc. All Rights Reserved.

CLINICAL STAGE	PRIMARY TREATMENT[j]	
Stage I without risk factors[i,j]	Surveillance (preferred)	See Follow-up for Nonseminoma, Table 7 (TEST-B 1 of 3)
	or	
	Nerve-sparing RPLND[l]	Postsurgical Management (NSEM-5)
	or	
	Adjuvant chemotherapy[m]: BEP for 1 cycle	See Follow-up for Nonseminoma, Table 9 (TEST-B 2 of 3)
Stage I with risk factors[i,j]	Surveillance	See Follow-up for Nonseminoma, Table 8 (TEST-B 1 of 3)
	or	
	Adjuvant chemotherapy[m]: BEP for 1 cycle	See Follow-up for Nonseminoma, Table 9 (TEST-B 2 of 3)
	or	
	Nerve-sparing RPLND[l]	Postsurgical Management (NSEM-5)
Stage IS	Highly elevated or persistently rising markers[a,k]	Primary Treatment (NSEM-6)

BEP = Bleomycin/Etoposide/Cisplatin

[a] Mildly elevated, non-rising AFP levels may not indicate presence of germ cell tumor. Decisions to treat should not be based solely on AFP values <20 ng/mL. More highly elevated AFP levels generally indicate the presence of nonseminomatous tumor elements. Further workup should be considered before initiating treatment for mildly elevated beta-hCG (generally <20 IU/L) since other factors, including hypogonadism and cannabis use, can cause false-positive results. See Discussion.

[i] Risk factors for recurrence include lymphovascular invasion or invasion of spermatic cord or scrotum. Some centers consider predominance of embryonal carcinoma as an additional risk factor for relapse.

[j] RPLND is preferred as primary treatment for stage I germ cell tumors with somatic type malignancy (previously referred to as transformed teratoma).Patients with stage I pure teratoma and normal markers should receive either surveillance or RPLND. See Discussion.

[k] Repeat scrotal ultrasound to rule out a contralateral testis mass if one has not been conducted in the last 3 months.

[l] All locoregional treatment is recommended within 4 weeks of CT or MRI and within 2 weeks of confirmation of normal tumor markers. Referral to a high-volume center is recommended. See Principles of Surgery for Germ Cell Tumors (TEST-H).

[m] Recommend imaging within the 4 weeks prior to the initiation of chemotherapy to confirm staging, even if the scan was done previously. See Principles of Imaging (TEST-I).

Note: All recommendations are category 2A unless otherwise indicated.

Version 1.2026, 10/15/2025 © 2025 National Comprehensive Cancer Network® (NCCN®), All rights reserved. NCCN Guidelines® and this illustration may not be reproduced in any form without the express written permission of NCCN.

PLEASE NOTE that use of this NCCN Content is governed by the End-User License Agreement, and you MAY NOT distribute this Content or use it with any artificial intelligence model or tool.
Printed by Máximo López Chenlo on 5/4/2026 6:31:34 PM. Copyright © 2026 National Comprehensive Cancer Network, Inc. All Rights Reserved.

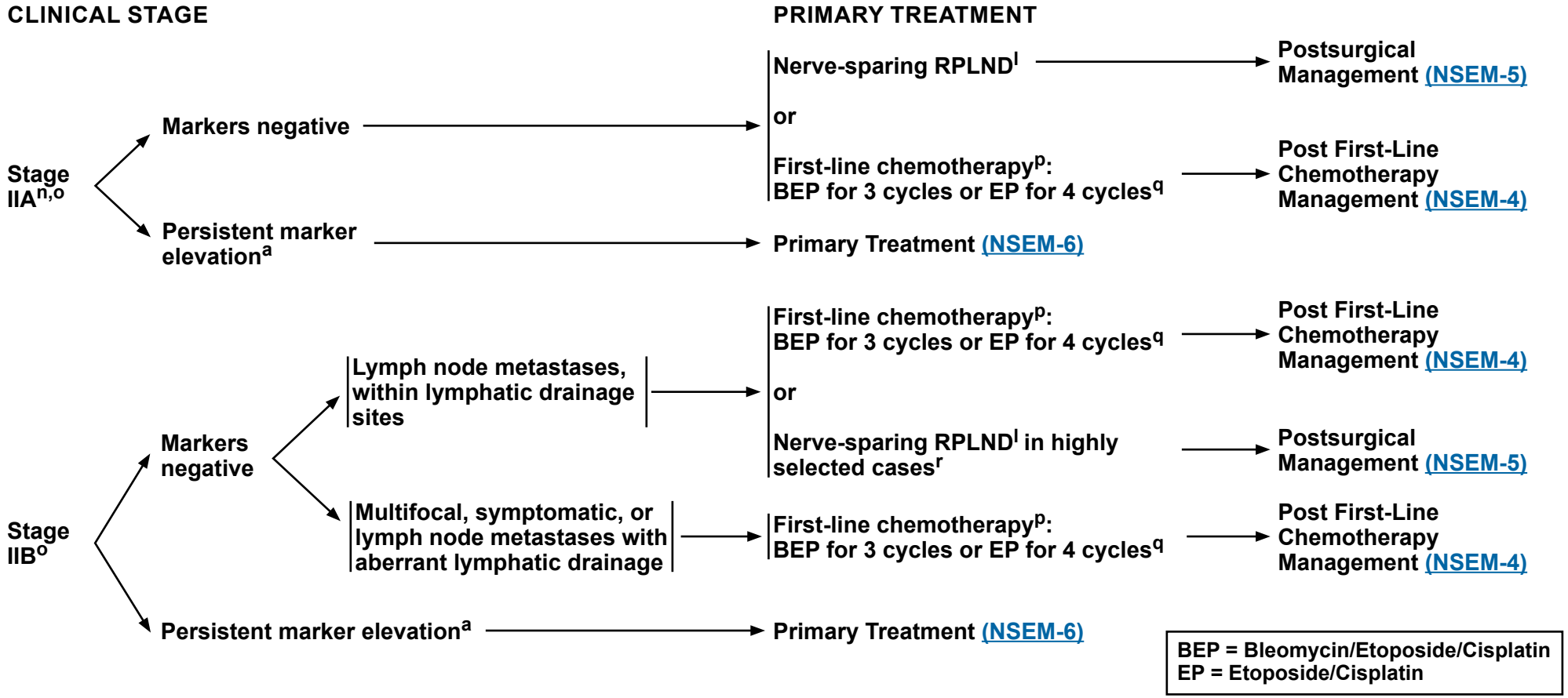

[a] Mildly elevated, non-rising AFP levels may not indicate presence of germ cell tumor. Decisions to treat should not be based solely on AFP values <20 ng/mL. More highly elevated AFP levels generally indicate the presence of nonseminomatous tumor elements. Further workup should be considered before initiating treatment for mildly elevated beta-hCG (generally <20 IU/L) since other factors, including hypogonadism and cannabis use, can cause false-positive results. See Discussion.

[l] All locoregional treatment is recommended within 4 weeks of CT or MRI and within 2 weeks of confirmation of normal tumor markers. Referral to a high-volume center is recommended. See Principles of Surgery for Germ Cell Tumors (TEST-H).

[n] For select cases of clinical stage IIA disease with borderline retroperitoneal lymph nodes, waiting 4–8 weeks and repeat imaging (CT or MRI) to confirm staging before initiating treatment can be considered.

[o] RPLND is preferred as primary treatment for stage II germ cell tumors with somatic type malignancy (previously referred to as transformed teratoma). See Discussion.

[p] First-Line Chemotherapy Regimens for Germ Cell Tumors (TEST-E).

[q] Consider a bleomycin-free regimen in patients at increased risk for bleomycin toxicity, such as those with reduced GFR or older age. See Discussion.

[r] RPLND should be considered for stage II tumors with teratoma predominance in patients with normal markers.

Note: All recommendations are category 2A unless otherwise indicated.

Version 1.2026, 10/15/2025 © 2025 National Comprehensive Cancer Network® (NCCN®), All rights reserved. NCCN Guidelines® and this illustration may not be reproduced in any form without the express written permission of NCCN.

PLEASE NOTE that use of this NCCN Content is governed by the End-User License Agreement, and you MAY NOT distribute this Content or use it with any artificial intelligence model or tool.
Printed by Máximo López Chenlo on 5/4/2026 6:31:34 PM. Copyright © 2026 National Comprehensive Cancer Network, Inc. All Rights Reserved.

POST FIRST-LINE CHEMOTHERAPY MANAGEMENT

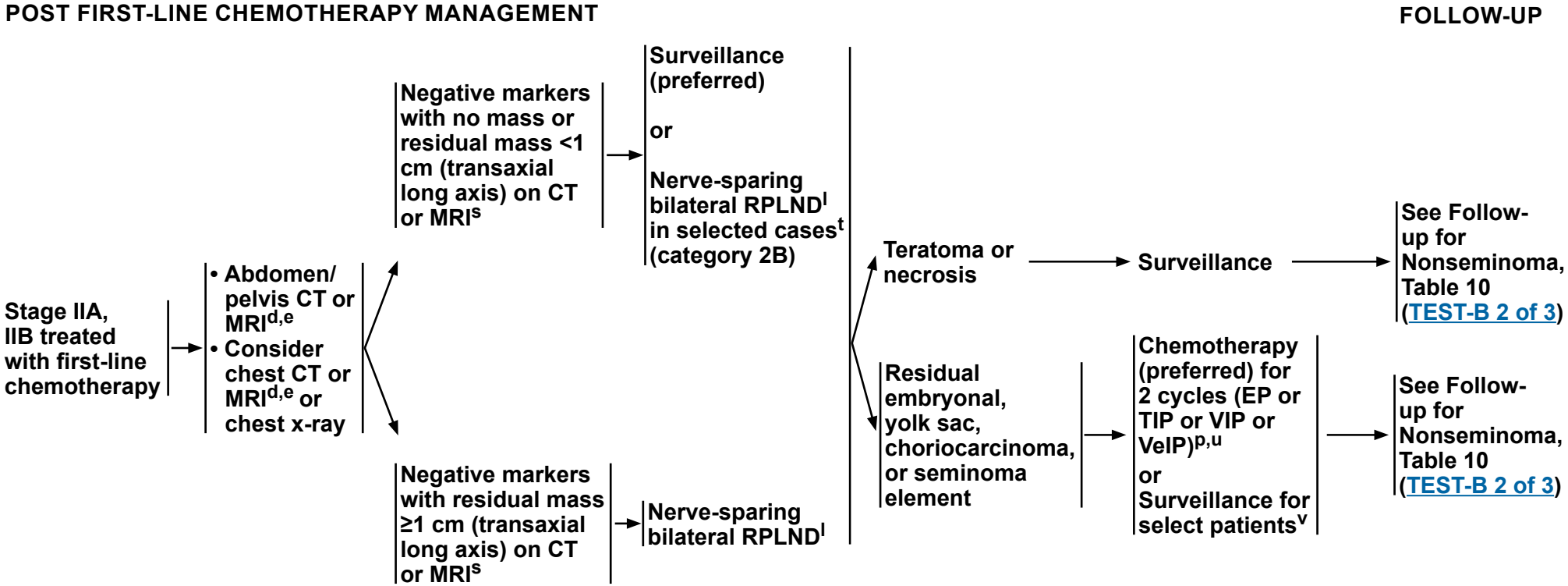

EP = Etoposide/Cisplatin
TIP = Paclitaxel/Ifosfamide/Cisplatin
VIP = Etoposide/Ifosfamide/Cisplatin
VeIP = Vinblastine/Ifosfamide/Cisplatin

[d] FDG-PET/CT scan is not clinically indicated for nonseminoma.
[e] CT with contrast and MRI with and without contrast should be performed unless performed prior to orchiectomy.
[l] All locoregional treatment is recommended within 4 weeks of CT or MRI and within 2 weeks of confirmation of normal tumor markers. Referral to a high-volume center is recommended. See Principles of Surgery for Germ Cell Tumors (TEST-H).
[p] First-Line Chemotherapy Regimens for Germ Cell Tumors (TEST-E).
[s] Craniocaudal axis should not be used.
[t] Patients with subcentimeter residual nodes who have teratoma or yolk sac tumor in their primary tumor may be at higher risk of teratoma or viable germ cell elements in the post-chemotherapy residual nodes. More data are still needed to know if they are at a higher risk of relapse or worse outcomes. See Discussion.
[u] Second-Line Chemotherapy Regimens for Metastatic Germ Cell Tumors (TEST-F).
[v] Surveillance is a reasonable alternative to chemotherapy for patients with residual masses that have been completely resected if all of the residual masses have <10% viable cancer cells in the resected tissue.

Note: All recommendations are category 2A unless otherwise indicated.

Version 1.2026, 10/15/2025 © 2025 National Comprehensive Cancer Network® (NCCN®), All rights reserved. NCCN Guidelines® and this illustration may not be reproduced in any form without the express written permission of NCCN.

PLEASE NOTE that use of this NCCN Content is governed by the End-User License Agreement, and you MAY NOT distribute this Content or use it with any artificial intelligence model or tool.
Printed by Máximo López Chenlo on 5/4/2026 6:31:34 PM. Copyright © 2026 National Comprehensive Cancer Network, Inc. All Rights Reserved.

POSTSURGICAL MANAGEMENT

FOLLOW-UP

Stage IA, IB with and without risk factors,[i] IIA, IIB treated with primary nerve-sparing RPLND

- **pN0** → **Surveillance** → **See Follow-up for Nonseminoma, Table 9 (TEST-B 2 of 3)**
- **pN1** →
  - **Surveillance (preferred)** → **See Follow-up for Nonseminoma, Table 9 (TEST-B 2 of 3) or 12 (TEST-B 3 of 3)**
  - **or**
  - **Chemotherapy[p]: EP for 2 cycles** → **See Follow-up for Nonseminoma, Table 11 (TEST-B 3 of 3)**
- **pN2[w]** →
  - **Chemotherapy[p]: EP for 2 cycles** → **See Follow-up for Nonseminoma, Table 11 (TEST-B 3 of 3)**
  - **or**
  - **Surveillance** → **See Follow-up for Nonseminoma, Table 12 (TEST-B 3 of 3)**
- **pN3[w]** →
  - **Chemotherapy[p,x]** → **See Follow-up for Nonseminoma, Table 11 (TEST-B 3 of 3)**
  - **or**
  - **Surveillance[y]** → **See Follow-up for Nonseminoma, Table 12 (TEST-B 3 of 3)**

EP = Etoposide/Cisplatin

[i] Risk factors for recurrence include lymphovascular invasion or invasion of spermatic cord or scrotum. Some centers consider predominance of embryonal carcinoma as an additional risk factor for relapse.
[p] First-Line Chemotherapy Regimens for Germ Cell Tumors (TEST-E).
[w] Surveillance is preferred for patients who have pure teratoma.
[x] This is a rare circumstance. Due to the limited available data, the Panel could not reach a consensus as to the optimal regimen. BEP for 2–3 cycles or EP for 2–4 cycles can be considered.
[y] CT or MRI of abdomen/pelvis or chest x-ray 2–3 months after surgery.

Note: All recommendations are category 2A unless otherwise indicated.

Version 1.2026, 10/15/2025 © 2025 National Comprehensive Cancer Network® (NCCN®), All rights reserved. NCCN Guidelines® and this illustration may not be reproduced in any form without the express written permission of NCCN.

PLEASE NOTE that use of this NCCN Content is governed by the End-User License Agreement, and you MAY NOT distribute this Content or use it with any artificial intelligence model or tool.
Printed by Máximo López Chenlo on 5/4/2026 6:31:34 PM. Copyright © 2026 National Comprehensive Cancer Network, Inc. All Rights Reserved.

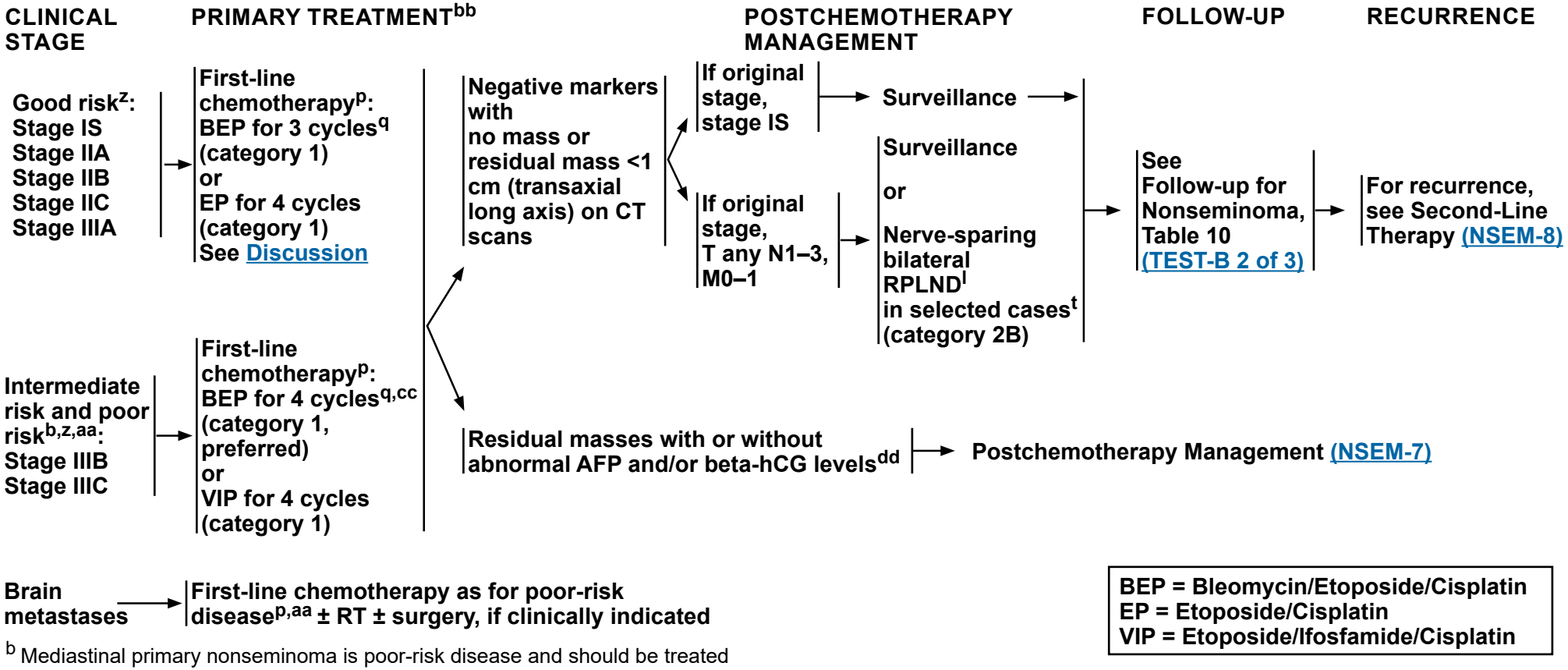

BEP = Bleomycin/Etoposide/Cisplatin
EP = Etoposide/Cisplatin
VIP = Etoposide/Ifosfamide/Cisplatin

[b] Mediastinal primary nonseminoma is poor-risk disease and should be treated with either VIP or BEP with careful pulmonary functioning monitoring. See Discussion.

[l] All locoregional treatment is recommended within 4 weeks of CT or MRI and within 2 weeks of confirmation of normal tumor markers. Referral to a high-volume center is recommended. See Principles of Surgery for Germ Cell Tumors (TEST-H).

[p] First-Line Chemotherapy Regimens for Germ Cell Tumors (TEST-E).

[q] Consider a bleomycin-free regimen in patients at increased risk for bleomycin toxicity, such as those with reduced GFR or older age. See Discussion.

[t] Patients with subcentimeter residual nodes who have teratoma or yolk sac tumor in their primary tumor may be at higher risk of teratoma or viable germ cell elements in the post-chemotherapy residual nodes. More data are still needed to know if they are at a higher risk of relapse or worse outcomes. See Discussion.

[z] Risk Classification for Advanced Disease (TEST-D).

[aa] Referral to a high-volume center is recommended for patients with poor-risk disease. Consider referral to a high-volume center for patients with intermediate-risk disease.

[bb] To assess response after treatment, CT with contrast or MRI with and without contrast of C/A/P and any other sites of disease is recommended. FDG-PET/CT has no role in assessing treatment response and residual masses following chemotherapy in patients with nonseminoma.

[cc] If intermediate risk is based only on LDH 1.5–3 times the ULN, then BEP for 3 cycles or EP for 4 cycles can be considered.

[dd] Recommend referral to a high-volume center for residual masses with abnormal AFP and/or beta-hCG levels.

Note: All recommendations are category 2A unless otherwise indicated.

Version 1.2026, 10/15/2025 © 2025 National Comprehensive Cancer Network® (NCCN®), All rights reserved. NCCN Guidelines® and this illustration may not be reproduced in any form without the express written permission of NCCN.

PLEASE NOTE that use of this NCCN Content is governed by the End-User License Agreement, and you MAY NOT distribute this Content or use it with any artificial intelligence model or tool.
Printed by Máximo López Chenlo on 5/4/2026 6:31:34 PM. Copyright © 2026 National Comprehensive Cancer Network, Inc. All Rights Reserved.

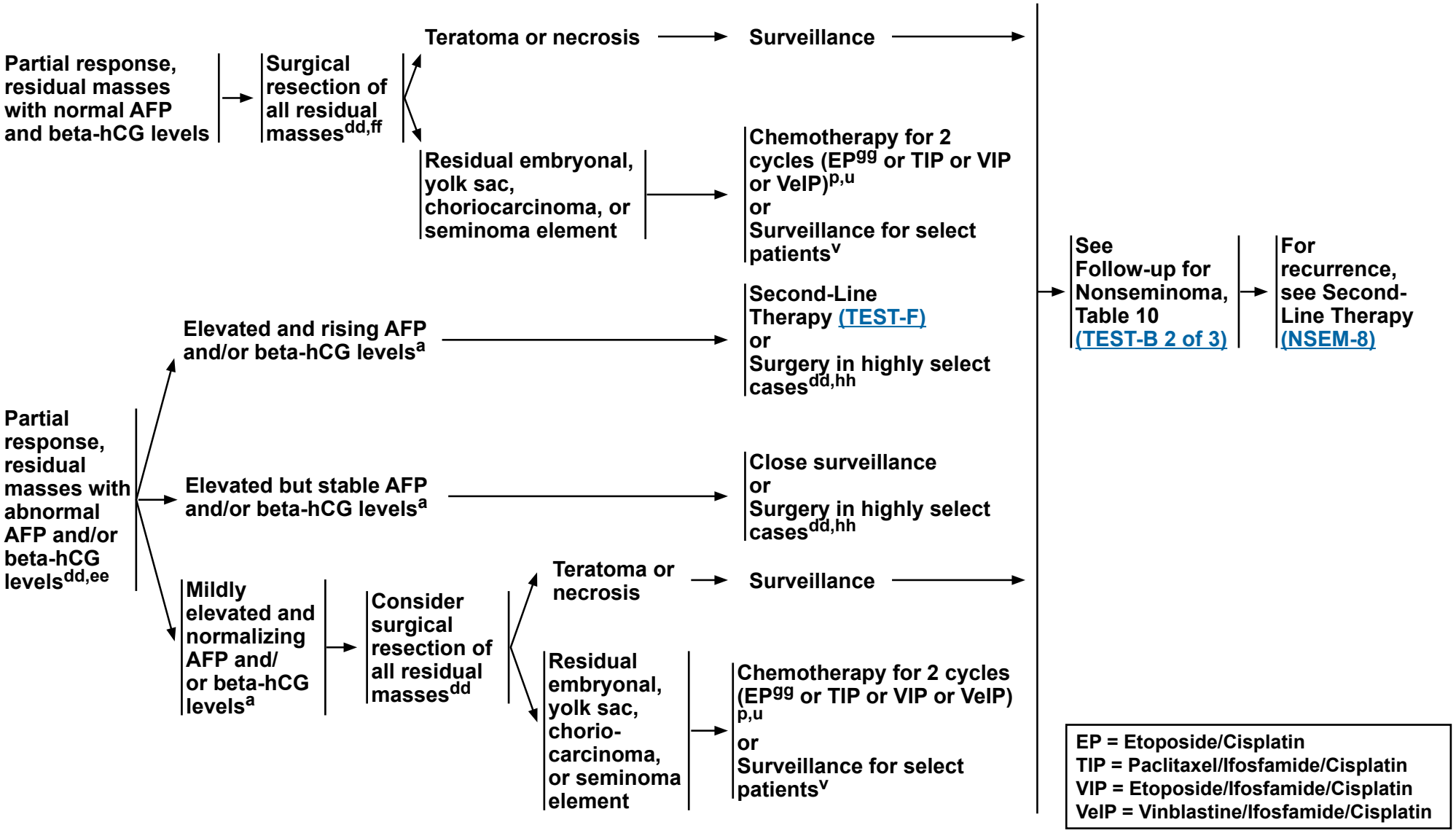

Note: All recommendations are category 2A unless otherwise indicated.

Footnotes on NSEM-7A

Version 1.2026, 10/15/2025 © 2025 National Comprehensive Cancer Network® (NCCN®), All rights reserved. NCCN Guidelines® and this illustration may not be reproduced in any form without the express written permission of NCCN.

PLEASE NOTE that use of this NCCN Content is governed by the End-User License Agreement, and you MAY NOT distribute this Content or use it with any artificial intelligence model or tool.
Printed by Máximo López Chenlo on 5/4/2026 6:31:34 PM. Copyright © 2026 National Comprehensive Cancer Network, Inc. All Rights Reserved.

FOOTNOTES

[a] Mildly elevated, non-rising AFP levels may not indicate presence of germ cell tumor. Decisions to treat should not be based solely on AFP values <20 ng/mL. More highly elevated AFP levels generally indicate the presence of nonseminomatous tumor elements. Further workup should be considered before initiating treatment for mildly elevated beta-hCG (generally <20 IU/L) since other factors, including hypogonadism and cannabis use, can cause false-positive results. See Discussion.
[p] First-Line Chemotherapy Regimens for Germ Cell Tumors (TEST-E).
[u] Second-Line Chemotherapy Regimens for Metastatic Germ Cell Tumors (TEST-F).
[v] Surveillance is a reasonable alternative to chemotherapy for patients with residual masses that have been completely resected if all of the residual masses have <10% viable cancer cells in the resected tissue.
[dd] Recommend referral to a high-volume center for residual masses with abnormal AFP and/or beta-hCG levels.
[ee] Consider brain imaging and testicular ultrasound in patients with elevated or rising markers after primary or secondary chemotherapy to evaluate for occult brain metastases or contralateral primary disease.
[ff] If there is a teratoma with somatic-type malignancy, consider histology-directed therapy and referral to an academic center with a high-volume germ cell tumor unit.
[gg] Consider EP for low-volume residual disease.
[hh] Presentation of resectable retroperitoneal-only disease, significant factors that preclude chemotherapy use, and/or presence of cystic components.

Note: All recommendations are category 2A unless otherwise indicated.

Version 1.2026, 10/15/2025 © 2025 National Comprehensive Cancer Network® (NCCN®), All rights reserved. NCCN Guidelines® and this illustration may not be reproduced in any form without the express written permission of NCCN.

PLEASE NOTE that use of this NCCN Content is governed by the End-User License Agreement, and you MAY NOT distribute this Content or use it with any artificial intelligence model or tool.
Printed by Máximo López Chenlo on 5/4/2026 6:31:34 PM. Copyright © 2026 National Comprehensive Cancer Network, Inc. All Rights Reserved.

RECURRENCE[ii] | **SECOND-LINE THERAPY[bb,jj]** | **FOLLOW-UP**

Prior first-line chemotherapy

→ **Early relapse (recurrence ≤2 years after completion of primary treatment)** →
- **Clinical trial**
- **Chemotherapy[u]**
  - **Conventional-dose therapy (VeIP for 4 cycles or TIP for 4 cycles)**
  - **High-dose chemotherapy**
- **Consider surgical treatment if resectable with normal or mildly elevated markers[dd]**
- **Recommend sperm banking if clinically indicated**

→ **Late relapse (recurrence >2 years after completion of primary treatment)** →
- **Surgical treatment, if resectable, regardless of markers (preferred)**
- **Clinical trial, if unresectable**
- **Chemotherapy[u]**
  - **Conventional-dose therapy (VeIP for 4 cycles or TIP for 4 cycles)**
  - **High-dose chemotherapy[kk]**
- **Recommend sperm banking if clinically indicated**

→ **Post Second-Line Therapy Management (NSEM-9)**

No prior first-line chemotherapy → **Treat per risk status on (NSEM-6) and Recommend sperm banking if clinically indicated**

Prior adjuvant therapy (1 cycle of BEP only) → **First-line chemotherapy[ll] (NSEM-6)**

- **TIP = Paclitaxel/Ifosfamide/Cisplatin**
- **VeIP = Vinblastine/Ifosfamide/Cisplatin**

[u] Second-Line Chemotherapy Regimens for Metastatic Germ Cell Tumors (TEST-F).

[bb] To assess response after treatment, CT with contrast or MRI with and without contrast of C/A/P and any other sites of disease is recommended. FDG-PET/CT has no role in assessing treatment response and residual masses following chemotherapy in patients with nonseminoma.

[dd] Recommend referral to a high-volume center for residual masses with abnormal AFP and/or beta-hCG levels.

[ii] It is preferred that patients with recurrent nonseminoma be treated at centers with expertise in the management of this disease.

[jj] Includes best supportive care and palliative care. See NCCN Guidelines for Palliative Care.

[kk] Low efficacy of treatment should be considered.

[ll] For select patients, RPLND may be appropriate.

Note: All recommendations are category 2A unless otherwise indicated.

Version 1.2026, 10/15/2025 © 2025 National Comprehensive Cancer Network® (NCCN®), All rights reserved. NCCN Guidelines® and this illustration may not be reproduced in any form without the express written permission of NCCN.

PLEASE NOTE that use of this NCCN Content is governed by the End-User License Agreement, and you MAY NOT distribute this Content or use it with any artificial intelligence model or tool.
Printed by Máximo López Chenlo on 5/4/2026 6:31:34 PM. Copyright © 2026 National Comprehensive Cancer Network, Inc. All Rights Reserved.

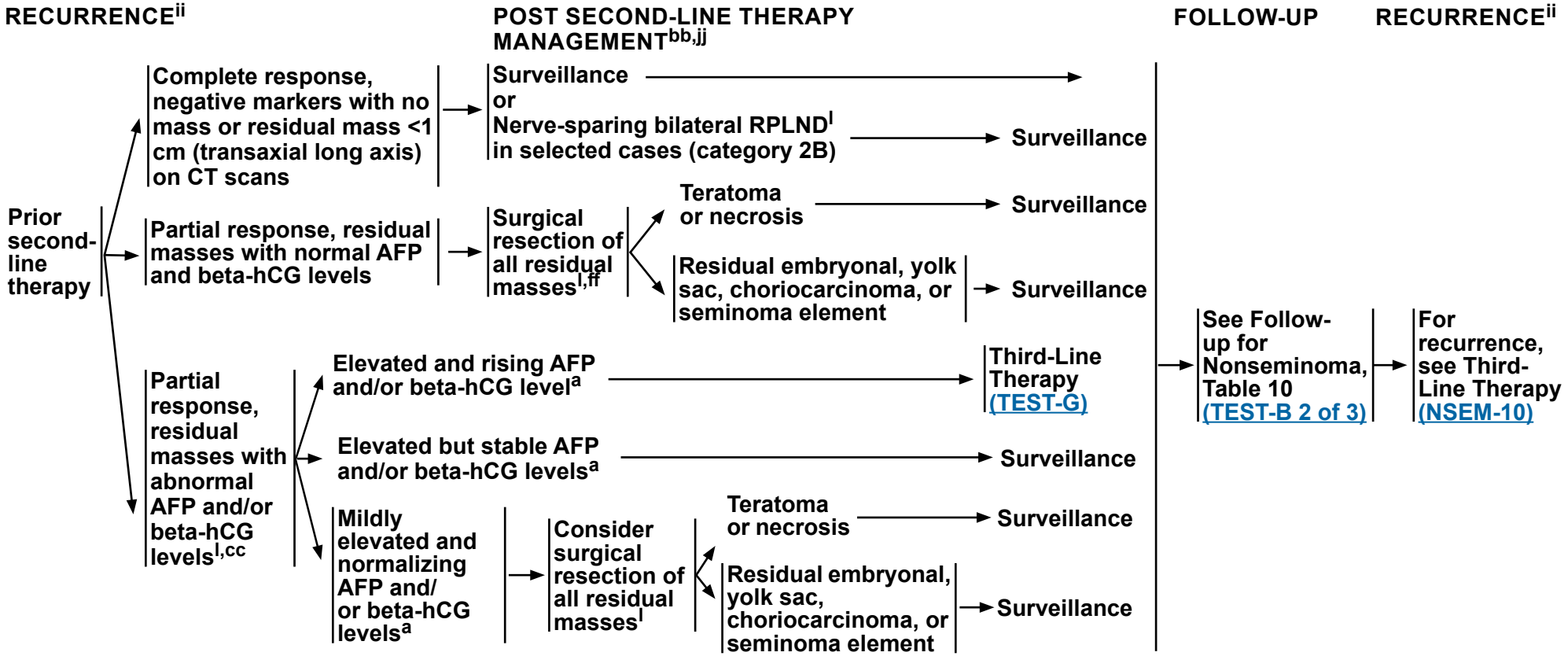

[a] Mildly elevated, non-rising AFP levels may not indicate presence of germ cell tumor. Decisions to treat should not be based solely on AFP values <20 ng/mL. More highly elevated AFP levels generally indicate the presence of nonseminomatous tumor elements. Further workup should be considered before initiating treatment for mildly elevated beta-hCG (generally <20 IU/L) since other factors, including hypogonadism and cannabis use, can cause false-positive results. See Discussion.

[l] All locoregional treatment is recommended within 4 weeks of CT or MRI and within 2 weeks of confirmation of normal tumor markers. Referral to a high-volume center is recommended. See Principles of Surgery for Germ Cell Tumors (TEST-H).

[bb] To assess response after treatment, CT with contrast or MRI with and without contrast of C/A/P and any other sites of disease is recommended. FDG-PET/CT has no role in assessing treatment response and residual masses following chemotherapy in patients with nonseminoma.

[cc] If intermediate risk is based only on LDH 1.5–3 times the ULN, then BEP for 3 cycles or EP for 4 cycles can be considered.

[ff] If there is a teratoma with somatic-type malignancy, consider histology-directed therapy and referral to an academic center with a high-volume germ cell tumor unit.

[ii] It is preferred that patients with recurrent nonseminoma be treated at centers with expertise in the management of this disease.

[jj] Includes best supportive care and palliative care. See NCCN Guidelines for Palliative Care.

Note: All recommendations are category 2A unless otherwise indicated.

Version 1.2026, 10/15/2025 © 2025 National Comprehensive Cancer Network® (NCCN®), All rights reserved. NCCN Guidelines® and this illustration may not be reproduced in any form without the express written permission of NCCN.

PLEASE NOTE that use of this NCCN Content is governed by the End-User License Agreement, and you MAY NOT distribute this Content or use it with any artificial intelligence model or tool.
Printed by Máximo López Chenlo on 5/4/2026 6:31:34 PM. Copyright © 2026 National Comprehensive Cancer Network, Inc. All Rights Reserved.

RECURRENCE[ii] | **THIRD-LINE THERAPY[bb,jj]**

Prior second-line chemotherapy

- **Prior first- and second-line conventional-dose chemotherapy** →
  - **Clinical trial**
  - **or**
  - **High-dose chemotherapy (preferred)[mm]**
  - **or**
  - **Consider surgical treatment if solitary site**
- **Prior high-dose chemotherapy** →
  - **Clinical trial (preferred)**
  - **or**
  - **Conventional-dose third-line chemotherapy[mm]**
  - **or**
  - **Consider surgical treatment if solitary site**
  - **or**
  - **Molecular testing for biomarker-driven therapy if progression[nn,oo,pp]**
- **Late relapse (recurrence >2 years after completion of second-line chemotherapy)** →
  - **Surgical treatment, if resectable (preferred)**
  - **or**
  - **Chemotherapy[mm]**
    - **• Conventional-dose therapy**
    - **• High-dose chemotherapy (if not previously received)**

[bb] To assess response after treatment, CT with contrast or MRI with and without contrast of C/A/P and any other sites of disease is recommended. FDG-PET/CT has no role in assessing treatment response and residual masses following chemotherapy in patients with nonseminoma.

[ii] It is preferred that patients with recurrent nonseminoma be treated at centers with expertise in the management of this disease.

[jj] Includes best supportive care and palliative care. See NCCN Guidelines for Palliative Care.

[mm] Third-Line Systemic Therapy Regimens for Metastatic Germ Cell Tumors (TEST-G).

[nn] Should include both NGS and IHC testing.

[oo] Molecular testing is to assess for sensitivity to targeted therapies. See Third-Line Systemic Therapy Regimens for Metastatic Germ Cell Tumors (TEST-G).

[pp] Pan-cancer, tumor-agnostic treatments can be considered for patients with actionable mutations.

Note: All recommendations are category 2A unless otherwise indicated.

Version 1.2026, 10/15/2025 © 2025 National Comprehensive Cancer Network® (NCCN®), All rights reserved. NCCN Guidelines® and this illustration may not be reproduced in any form without the express written permission of NCCN.

PLEASE NOTE that use of this NCCN Content is governed by the End-User License Agreement, and you MAY NOT distribute this Content or use it with any artificial intelligence model or tool.
Printed by Máximo López Chenlo on 5/4/2026 6:31:34 PM. Copyright © 2026 National Comprehensive Cancer Network, Inc. All Rights Reserved.

FOLLOW-UP FOR SEMINOMA

No single follow-up plan is appropriate for all patients. The follow-up for seminoma tables is to provide guidance, and should be modified for the individual patient based on sites of disease, biology of disease, and length of time on treatment *and may be extended beyond 5 years at the discretion of the physician*. Reassessment of disease activity should be performed in patients with new or worsening signs or symptoms of disease, regardless of the time interval from previous studies. Further study is required to define optimal follow-up duration. See NCCN Guidelines for Survivorship.

Table 1 Clinical Stage I Seminoma: Surveillance After Orchiectomy

	Year				
	1	2	3	4	5
H&P[a,b]	Every 4–6 mo	Every 6 mo	Every 6–12 mo	Annually	
Abdomen ± Pelvis CT[c] or MRI[d]	Every 4–6 mo	Every 6 mo	Every 6–12 mo	Every 12–24 mo	
Chest X-Ray	As clinically indicated, consider chest CT with contrast in symptomatic patients.				

If Recurrence, treat according to extent of disease at relapse

Table 2 Clinical Stage I Seminoma: Surveillance After Adjuvant Treatment (Chemotherapy or Radiation)

	Year				
	1	2	3	4	5[e]
H&P[a,b]	Every 6–12 mo	Every 6–12 mo	Annually		
Abdomen ± Pelvis CT[c] or MRI[d]	Annually			As clinically indicated	
Chest X-Ray	As clinically indicated, consider chest CT with contrast in symptomatic patients.				

If Recurrence, treat according to extent of disease at relapse

[a] Serum tumor markers are optional.
[b] Testicular ultrasound for any equivocal exam.
[c] With or without contrast. See Principles of Imaging (TEST-I).
[d] With and without contrast. The MRI protocol should include all the nodes that need to be assessed. See Principles of Imaging (TEST-I).
[e] CT or MRI is not recommended beyond 5 years unless clinically indicated.

Note: All recommendations are category 2A unless otherwise indicated.

Version 1.2026, 10/15/2025 © 2025 National Comprehensive Cancer Network® (NCCN®), All rights reserved. NCCN Guidelines® and this illustration may not be reproduced in any form without the express written permission of NCCN.

PLEASE NOTE that use of this NCCN Content is governed by the End-User License Agreement, and you MAY NOT distribute this Content or use it with any artificial intelligence model or tool.
Printed by Máximo López Chenlo on 5/4/2026 6:31:34 PM. Copyright © 2026 National Comprehensive Cancer Network, Inc. All Rights Reserved.

FOLLOW-UP FOR SEMINOMA

Table 3 Clinical Stage IIA and Non-Bulky IIB Seminoma: Surveillance After Radiotherapy or Chemotherapy or Both[f]

	Year				
	1	2	3	4	5[e]
H&P[a,b]	Every 3 mo	Every 6 mo			
CT[g] or MRI[d] of Abdomen + Pelvis	At 3 mo, then at 9 or 12 mo	Annually		As clinically indicated	
Chest X-Ray[h]	Every 6 mo		As clinically indicated		

If Recurrence, treat according to extent of disease at relapse

Table 4 Clinical Stage II Seminoma: Surveillance After Primary RPLND and NOT Treated with Adjuvant Chemotherapy

	Year				
	1	2	3	4	5[e]
H&P[a,b]	Every 4 mo	Every 6 mo			
CT[g] or MRI[d] of Abdomen + Pelvis	Every 4 mo	Every 6 mo	Annually	As clinically indicated	
Chest X-Ray[h]	Every 4 mo	Every 6 mo	Annually	As clinically indicated	

If Recurrence, treat according to extent of disease at relapse

[a] Serum tumor markers are optional.
[b] Testicular ultrasound for any equivocal exam.
[d] With and without contrast. The MRI protocol should include all the nodes that need to be assessed. See Principles of Imaging (TEST-I).
[e] CT or MRI is not recommended beyond 5 years unless clinically indicated.
[f] Assuming no residual mass or residual mass <3 cm and normal tumor markers.
[g] With contrast. See Principles of Imaging (TEST-I).
[h] Chest x-ray may be used for routine follow-up, but chest CT with contrast is preferred in the presence of thoracic symptoms.

Note: All recommendations are category 2A unless otherwise indicated.

Version 1.2026, 10/15/2025 © 2025 National Comprehensive Cancer Network® (NCCN®), All rights reserved. NCCN Guidelines® and this illustration may not be reproduced in any form without the express written permission of NCCN.

PLEASE NOTE that use of this NCCN Content is governed by the End-User License Agreement, and you MAY NOT distribute this Content or use it with any artificial intelligence model or tool.
Printed by Máximo López Chenlo on 5/4/2026 6:31:34 PM. Copyright © 2026 National Comprehensive Cancer Network, Inc. All Rights Reserved.

FOLLOW-UP FOR SEMINOMA

Table 5 Clinical Stage II Seminoma: Surveillance After Primary RPLND and Treated With Adjuvant Chemotherapy

	Year				
	1	2	3	4	5[e]
H&P[a,b]	Every 3 mo	Every 6 mo			
CT[g] or MRI[d] of Abdomen + Pelvis	Every 6 mo	Annually	As clinically indicated		
Chest X-Ray[h]	Every 6 mo	Annually	As clinically indicated		

If Recurrence, treat according to extent of disease at relapse

Table 6 Bulky Clinical Stage IIB, IIC, and Stage III Seminoma: Surveillance After Chemotherapy

	Year				
	1	2	3	4	5[e]
H&P and Markers[b]	Every 2–4 mo	Every 3–6 mo	Every 6 mo		Annually
CT[g,i,j,k] or MRI[d] of Abdomen/Pelvis	Every 4 mo	Every 6 mo	Annually		As clinically indicated
Chest X-ray[h]	Every 4 mo[l]	Every 6 mo[l]	Annually		

If Recurrence, see Second-Line Therapy (SEM-6)

[a] Serum tumor markers are optional.
[b] Testicular ultrasound for any equivocal exam.
[d] With and without contrast. The MRI protocol should include all the nodes that need to be assessed. See Principles of Imaging (TEST-I).
[e] CT or MRI is not recommended beyond 5 years unless clinically indicated.
[g] With contrast. See Principles of Imaging (TEST-I).
[h] Chest x-ray may be used for routine follow-up, but chest CT with contrast is preferred in the presence of thoracic symptoms.
[i] Patients with FDG-PET/CT-negative residual mass measuring >3 cm following chemotherapy should undergo an MRI with and without contrast or abdomen/pelvis CT scan with contrast every 6 months for the first year, then annually for 5 years.
[j] Patients with residual masses may require more frequent imaging based on clinical judgment.
[k] FDG-PET/CT scan of skull base to mid-thigh as clinically indicated.
[l] Add chest CT with contrast if supradiaphragmatic disease present at diagnosis.

Note: All recommendations are category 2A unless otherwise indicated.

Version 1.2026, 10/15/2025 © 2025 National Comprehensive Cancer Network® (NCCN®), All rights reserved. NCCN Guidelines® and this illustration may not be reproduced in any form without the express written permission of NCCN.

PLEASE NOTE that use of this NCCN Content is governed by the End-User License Agreement, and you MAY NOT distribute this Content or use it with any artificial intelligence model or tool.
Printed by Máximo López Chenlo on 5/4/2026 6:31:34 PM. Copyright © 2026 National Comprehensive Cancer Network, Inc. All Rights Reserved.

FOLLOW-UP FOR NONSEMINOMA

No single follow-up plan is appropriate for all patients. The follow-up for nonseminoma tables is to provide guidance, and should be modified for the individual patient based on sites of disease, biology of disease, and length of time on treatment *and may be extended beyond 5 years at the discretion of the physician*. Reassessment of disease activity should be performed in patients with new or worsening signs or symptoms of disease, regardless of the time interval from previous studies. Further study is required to define optimal follow-up duration.

Table 7 Clinical Stage I Without Risk Factors,[a] NSGCT: Active Surveillance

	Year				
	1	2	3	4	5
H&P and Markers[b]	Every 2–3 mo	Every 3 mo	Every 4–6 mo	Every 6 mo	Annually
CT[c] or MRI[d] of Abdomen ± Pelvis	Every 4–6 mo	Every 6 mo	Annually	Every 12–24 months	
Chest X-Ray[e]	At mo 4 and 12	Annually	As clinically indicated		

If Recurrence, treat according to extent of disease at relapse

Table 8 Clinical Stage I With Risk Factors,[a] NSGCT: Active Surveillance

	Year				
	1	2	3	4	5
H&P and Markers[b]	Every 2 mo	Every 3 mo	Every 4–6 mo	Every 6 mo	Annually
CT[c] or MRI[d] of Abdomen ± Pelvis	Every 4 mo	Every 4–6 mo	Every 6 mo	Annually	As clinically indicated
Chest X-Ray[e]	Every 4 mo	Every 4–6 mo	Every 6 mo	Annually	As clinically indicated

If Recurrence, treat according to extent of disease at relapse

[a] Risk factors for recurrence include lymphovascular invasion or invasion of spermatic cord or scrotum. Some centers consider predominance of embryonal carcinoma as an additional risk factor for relapse.
[b] Testicular ultrasound for any equivocal exam.
[c] With contrast. See Principles of Imaging (TEST-I).
[d] With and without contrast. The MRI protocol should include all the nodes that need to be assessed. See Principles of Imaging (TEST-I).
[e] Chest x-ray may be used for routine follow-up, but chest CT with contrast is preferred in the presence of thoracic symptoms.

Note: All recommendations are category 2A unless otherwise indicated.

Version 1.2026, 10/15/2025 © 2025 National Comprehensive Cancer Network® (NCCN®), All rights reserved. NCCN Guidelines® and this illustration may not be reproduced in any form without the express written permission of NCCN.

PLEASE NOTE that use of this NCCN Content is governed by the End-User License Agreement, and you MAY NOT distribute this Content or use it with any artificial intelligence model or tool.
Printed by Máximo López Chenlo on 5/4/2026 6:31:34 PM. Copyright © 2026 National Comprehensive Cancer Network, Inc. All Rights Reserved.

FOLLOW-UP FOR NONSEMINOMA

Table 9[f] Clinical Stage IA/B NSGCT: Treated with 1 Cycle of Adjuvant BEP Chemotherapy or Primary RPLND[f]

	Year				
	1	2	3	4	5
H&P and Markers[b]	Every 3 mo		Every 6 mo		Annually
CT[c] or MRI[d] of Abdomen ± Pelvis	Annually[g]		As clinically indicated		
Chest X-Ray[e]	Every 6–12 mo	Annually	As clinically indicated		

If Recurrence, treat according to extent of disease at relapse

Table 10 Clinical Stage II–III NSGCT: Surveillance After Chemotherapy ± Surgery[h]

	Year				
	1[h]	2[h]	3	4	5
H&P and Markers[b]	Every 2 mo	Every 3 mo	Every 6 mo[k]		
CT[c,i] or MRI[d] of Abdomen ± Pelvis	Every 4–6 mo	Every 6–12 mo	Annually	As clinically indicated[l]	
Chest X-Ray[e,j]	Every 4–6 mo	Every 6–12 mo	As clinically indicated[m]		

If Recurrence, see Second-Line Therapy (NSEM-8) or Third-Line Therapy (NSEM-10)

[b] Testicular ultrasound for any equivocal exam.
[c] With contrast. See Principles of Imaging (TEST-I).
[d] With and without contrast. The MRI protocol should include all the nodes that need to be assessed. See Principles of Imaging (TEST-I).
[e] Chest x-ray may be used for routine follow-up, but chest CT with contrast is preferred in the presence of thoracic symptoms.
[f] If pathologic stage I; if pathologic stage II see Table 11 (TEST-B 3 of 3).
[g] In year 2, this is optional for patients treated with primary RPLND.
[h] Patients who have a partial response to chemotherapy who are not surgical candidates require more frequent imaging than is listed on this table.
[i] Patients with clinical stage II disease treated with chemotherapy who undergo postchemotherapy RPLND and are found to have pN0 disease or pN1 pure teratoma need only 1 CT scan at postoperative month 3–4 and then as clinically indicated. See Discussion.
[j] Chest CT with contrast if supradiaphragmatic disease at baseline.
[k] Consider annual tumor markers for years 5–10 and as clinically indicated thereafter.
[l] For patients with unresected residual masses or resected residual masses containing viable cancer.
[m] Chest x-ray is optional at months 36 and 48.

Note: All recommendations are category 2A unless otherwise indicated.

Version 1.2026, 10/15/2025 © 2025 National Comprehensive Cancer Network® (NCCN®), All rights reserved. NCCN Guidelines® and this illustration may not be reproduced in any form without the express written permission of NCCN.

PLEASE NOTE that use of this NCCN Content is governed by the End-User License Agreement, and you MAY NOT distribute this Content or use it with any artificial intelligence model or tool.
Printed by Máximo López Chenlo on 5/4/2026 6:31:34 PM. Copyright © 2026 National Comprehensive Cancer Network, Inc. All Rights Reserved.

FOLLOW-UP FOR NONSEMINOMA

Table 11 Pathologic Stage IIA/B/C NSGCT: Surveillance After Primary RPLND and Treated with Adjuvant Chemotherapy

	Year				
	1	2	3	4	5
H&P and Markers[b]	Every 4–6 mo	Every 6 mo	Annually		
CT[c,n] or MRI[d] of Abdomen/ Pelvis	4 mo after RPLND	As clinically indicated			
Chest X-Ray[e]	Every 6 mo	Annually			

If Recurrence, see Second-Line Therapy (NSEM-8)

Table 12 Pathologic Stage IIA/B[o] NSGCT: Surveillance After Primary RPLND and NOT Treated with Adjuvant Chemotherapy[p]

	Year				
	1	2	3	4	5
H&P and Markers[b]	Every 2 mo	Every 3 mo	Every 4 mo	Every 6 mo	Annually
CT[c] or MRI[d] of Abdomen/ Pelvis	At 4 mo[q]	Annually	As clinically indicated		
Chest X-Ray[e]	Every 2–4 mo	Every 3–6 mo	Annually		

If Recurrence, see First-Line Therapy (NSEM-6)

[b] Testicular ultrasound for any equivocal exam.
[c] With contrast. See Principles of Imaging (TEST-I).
[d] With and without contrast. The MRI protocol should include all the nodes that need to be assessed. See Principles of Imaging (TEST-I).
[e] Chest x-ray may be used for routine follow-up, but chest CT with contrast is preferred in the presence of thoracic symptoms.
[n] Patients who undergo RPLND and are found to have pN0 disease or pN1 pure teratoma need only 1 CT scan at postoperative month 3–4 and then as clinically indicated. See Discussion.
[o] For pathologic stage IIC, more frequent imaging is recommended.
[p] Patients with clinical stage IIA/IIB nonseminoma who undergo primary RPLND and are found to have pN0 disease (no cancer and no teratoma, pathologic stage I) should revert to the surveillance schedule for low-risk NSGCT with the exception that only 1 CT scan is needed postoperatively around month 4 (Table 9).
[q] This schedule assumes a complete resection has taken place.

Note: All recommendations are category 2A unless otherwise indicated.

Version 1.2026, 10/15/2025 © 2025 National Comprehensive Cancer Network® (NCCN®), All rights reserved. NCCN Guidelines® and this illustration may not be reproduced in any form without the express written permission of NCCN.

PLEASE NOTE that use of this NCCN Content is governed by the End-User License Agreement, and you MAY NOT distribute this Content or use it with any artificial intelligence model or tool.
Printed by Máximo López Chenlo on 5/4/2026 6:31:34 PM. Copyright © 2026 National Comprehensive Cancer Network, Inc. All Rights Reserved.

PRINCIPLES OF RADIOTHERAPY FOR PURE TESTICULAR SEMINOMA

General Principles

- Modern radiotherapy involves smaller fields and lower doses than were used in the past. References are provided to support current recommended management.
- The mean dose (Dmean) and dose delivered to 50% of the volume (D50%) of the kidneys, liver, and bowel are lower with CT-based anteroposterior-posteroanterior (AP-PA) three-dimensional conformal RT (3D-CRT) than intensity-modulated RT (IMRT).[1] As a result, the risk of second cancers arising in the kidneys, liver, or bowel may be lower with 3D-CRT than IMRT, and IMRT is not necessary.[2] Proton therapy can also be considered. See Discussion.
- Timing of Radiotherapy:
  - Radiotherapy should start once the orchiectomy wound has fully healed.
  - Patients should be treated 5 days per week.
  - Patients who miss a fraction should be treated with the same total dose and with the same fraction size, extending the overall treatment time slightly.
- Antiemetic medication significantly improves nausea. See NCCN Guidelines for Antiemesis. Antiemetic prophylaxis is encouraged at least 2 hours prior to each treatment, and some cases may require more frequent dosing.

Preparation for Radiotherapy

- A discussion of semen analysis and sperm banking prior to post-orchiectomy treatment is recommended if clinically indicated.[3,4]
- If sperm banking is desired, it should be performed prior to the delivery of adjuvant therapy.

General Treatment Information

- Treatment Planning Principles
  - A non-contrast CT simulation should be performed with the patient supine, arms at the patient's sides, in the treatment position.
    - ◊ Immobilization with a cast may be used to improve the reproducibility of patient setup.
    - ◊ All patients, with the exception of those who have undergone bilateral orchiectomy, should be treated with a scrotal shield.

Stage I on TEST-C 2 of 5
Stage IIA/B on TEST-C 3 of 5
References on TEST-C 5 of 5

Note: All recommendations are category 2A unless otherwise indicated.

Version 1.2026, 10/15/2025 © 2025 National Comprehensive Cancer Network® (NCCN®), All rights reserved. NCCN Guidelines® and this illustration may not be reproduced in any form without the express written permission of NCCN.

PLEASE NOTE that use of this NCCN Content is governed by the End-User License Agreement, and you MAY NOT distribute this Content or use it with any artificial intelligence model or tool.
Printed by Máximo López Chenlo on 5/4/2026 6:31:34 PM. Copyright © 2026 National Comprehensive Cancer Network, Inc. All Rights Reserved.

PRINCIPLES OF RADIOTHERAPY FOR PURE TESTICULAR SEMINOMA

Stage I

- **Dose: For stages IA, IB: Recommended radiation dose regimens are listed in the table below for the minority of patients who prefer adjuvant treatment, realizing that there is a high likelihood of cure should a relapse occur during surveillance.[5]**

Table 1

Total Dose (Gy)	Dose per Fraction (Gy)	Number of Fractions
20 (preferred)	2.0	10
25.5	1.5	17
19.8	1.8	11
21.6	1.8	12

- **Para-aortic-Strip Fields[6] - Field Arrangement:**
  - **In patients with no history of pelvic or scrotal surgery, para-aortic strip irradiation may be delivered with opposed AP-PA fields. The weights of the fields may be equal.**
    - **Recent nodal mapping studies suggest that fields should target the retroperitoneal lymph nodes but not necessarily the ipsilateral renal hilar nodes (see lateral borders).[7,8]**
    - **Superior and inferior borders: Borders may be determined by bony anatomy.**
    - **The superior border should be placed at the bottom of vertebral body T10/T11.[9]**
    - **The inferior border should be placed at the inferior border of vertebral body L5.[6,10]**
    - **Lateral borders:**
      - **Conventionally, para-aortic-strip fields are approximately 10 cm wide, encompassing the tips of the transverse processes of the PA vertebrae.**
    - **The location of the kidneys within the para-aortic-strip fields varies from patient to patient.**
      - **For patients whose kidneys are relatively medial, small renal blocks may be added at the level of T12. The right and left kidney D50% should be ≤8 Gy (ie, ≤50% of each kidney can receive ≥8 Gy).[1] If only one kidney is present, the kidney D15% should be ≤20 Gy (ie, ≤15% of the volume of the kidney can receive ≥20 Gy).[1]**
      - **An alternative 3D-CRT planning technique is to base the lateral borders on vascular structures on a treatment planning CT scan without contrast. The aorta and inferior vena cava (IVC) may be contoured on the CT scan; one should allow a 1.2- to 1.9-cm margin on the aorta and IVC to include the para-aortic, paracaval, interaortocaval, and preaortic nodes in the clinical target volume.[7,11] The planning target volume is then established by uniformly expanding the clinical target volume by 0.5 cm in all directions to account for treatment setup errors.[12] A uniform 0.7-cm margin should be provided on the planning target volume to the block edge to take beam penumbra into account (Figure 1, TEST-C 4 of 5).[1]**

Special Considerations

- **Ipsilateral pelvic surgery (eg, inguinal herniorrhaphy or orchiopexy) may alter the lymphatic drainage of the testis. As a result, irradiation of the ipsilateral iliac and inguinal lymph nodes, including the surgical scar from prior surgery, has been advocated even in patients with stage I cancer.[8,13]**

Stage IIA/B on TEST-C 3 of 5
References on TEST-C 5 of 5

Note: All recommendations are category 2A unless otherwise indicated.

Version 1.2026, 10/15/2025 © 2025 National Comprehensive Cancer Network® (NCCN®), All rights reserved. NCCN Guidelines® and this illustration may not be reproduced in any form without the express written permission of NCCN.

PLEASE NOTE that use of this NCCN Content is governed by the End-User License Agreement, and you MAY NOT distribute this Content or use it with any artificial intelligence model or tool.
Printed by Máximo López Chenlo on 5/4/2026 6:31:34 PM. Copyright © 2026 National Comprehensive Cancer Network, Inc. All Rights Reserved.

PRINCIPLES OF RADIOTHERAPY FOR PURE TESTICULAR SEMINOMA

Stage II

- Patients should not receive primary RT if they have a horseshoe (pelvic) kidney, inflammatory bowel disease, or a history of RT.
- For patients with clinical stage IIA–B disease, treatment is delivered in two consecutive AP-PA phases (modified dog-leg fields and cone down). There is no break between the two phases.
- Modified Dog-Leg Fields:
  - Dose:
    - The initial phase consists of treatment of modified dog-leg fields to 20–25.5 Gy (see Table 1 on TEST-C 2 of 5 for dose fractionation options).
    - Boost gross disease to achieve a total dose of approximately:

Table 2: Boost to Gross Disease

Stage IIA/B	Total Dose (Gy)	Dose per Fraction (Gy)
1–2 cm	30	1.8–2.0 Gy per fraction
2–3 cm	36	1.8–2.0 Gy per fraction

  - Target: The fields should include the retroperitoneal and proximal ipsilateral iliac lymph nodes.
    - Modified dog-leg fields as described by Classen et al are preferred.[14]
    - Care should be taken to ensure coverage of the ipsilateral common, external, and proximal internal iliac lymph nodes down to the top of the acetabulum.
    - The fields can be set up using bony landmarks or by contouring the vascular structures, as for stage I.
      - The superior border should be placed at the bottom of vertebral body T10/T11.[15]
      - The inferior border should be placed at the top of the acetabulum.[14]
      - The medial border for the lower aspect of the modified dog-leg fields extends from the tip of the contralateral transverse process of the fifth lumbar vertebra toward the medial border of the ipsilateral obturator foramen.
      - The lateral border for the lower aspect of the modified dog-leg fields is defined by a line from the tip of the ipsilateral transverse process of the fifth lumbar vertebra to the superolateral border of the ipsilateral acetabulum.
      - Preferably, one should contour the aorta and IVC from the bottom of the T10/T11 vertebra inferiorly and ipsilateral iliac arteries and veins down to the top of the acetabulum. One should provide a 1.2- to 1.9-cm margin on these vascular structures for the clinical target volume.[7,11] The planning target volume is then established by uniformly expanding the clinical target volume by 0.5 cm in all directions to account for treatment setup errors.[12] A uniform 0.7-cm margin should be provided on the planning target volume to the block edge to take beam penumbra into account (Figure 2, TEST-C 4 of 5).[1]
      - It is not necessary to include the ipsilateral inguinal nodes or the inguinal scar in the AP-PA fields unless the patient has a history of ipsilateral pelvic surgery (eg, inguinal herniorrhaphy or orchiopexy).
- Cone Down:
  - Dose: The second phase (cone down) of the radiotherapy consists of daily 1.8–2 Gy fractions to a cumulative total dose of approximately 30 Gy (1–2 cm) for stage IIA and 36 Gy (2–3 cm) for stage IIB.[14]
  - Target: The nodal mass (gross tumor volume) must be contoured. A uniform, 2-cm margin from the gross tumor volume to block edge should be provided for the AP-PA cone-down fields (Figure 3, TEST-C 4 of 5).

Stage I on TEST-C 2 of 5
References on TEST-C 5 of 5

Note: All recommendations are category 2A unless otherwise indicated.

Version 1.2026, 10/15/2025 © 2025 National Comprehensive Cancer Network® (NCCN®), All rights reserved. NCCN Guidelines® and this illustration may not be reproduced in any form without the express written permission of NCCN.

PLEASE NOTE that use of this NCCN Content is governed by the End-User License Agreement, and you MAY NOT distribute this Content or use it with any artificial intelligence model or tool.
Printed by Máximo López Chenlo on 5/4/2026 6:31:34 PM. Copyright © 2026 National Comprehensive Cancer Network, Inc. All Rights Reserved.

PRINCIPLES OF RADIOTHERAPY FOR PURE TESTICULAR SEMINOMA

Treatment Modalities

- **Linear accelerators with >6 MV photons should be used when possible.**

Target Volumes by Stage (or location)

Figure 1:
Stage I RT Field

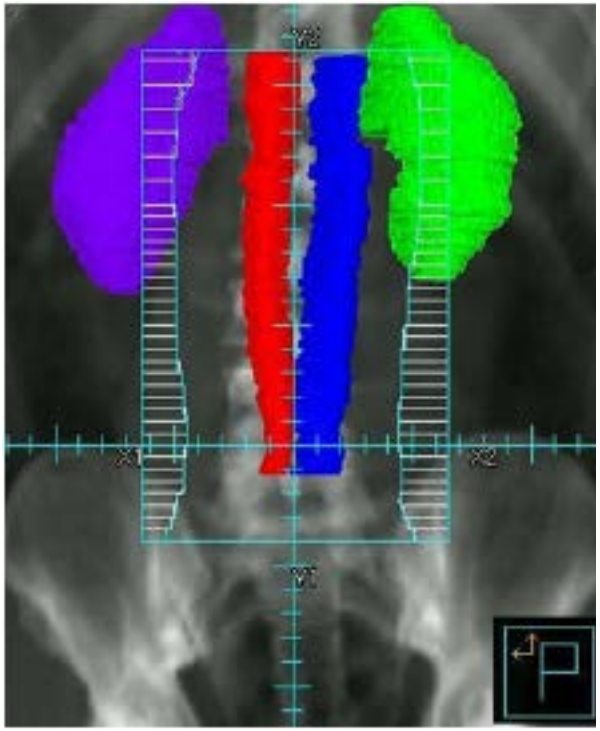

Figure 2:
Stage II RT Large Field

Figure 3:
Stage II Cone-Down Field

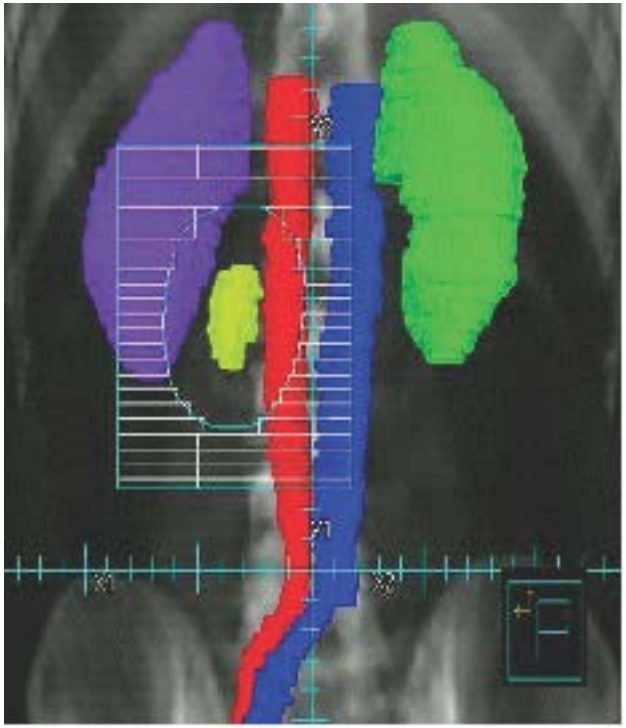

Stage I on TEST-C 2 of 5
Stage IIA/B on TEST-C 3 of 5
References on TEST-C 5 of 5

Note: All recommendations are category 2A unless otherwise indicated.

Version 1.2026, 10/15/2025 © 2025 National Comprehensive Cancer Network® (NCCN®), All rights reserved. NCCN Guidelines® and this illustration may not be reproduced in any form without the express written permission of NCCN.

PLEASE NOTE that use of this NCCN Content is governed by the End-User License Agreement, and you MAY NOT distribute this Content or use it with any artificial intelligence model or tool.
Printed by Máximo López Chenlo on 5/4/2026 6:31:34 PM. Copyright © 2026 National Comprehensive Cancer Network, Inc. All Rights Reserved.

PRINCIPLES OF RADIOTHERAPY FOR PURE TESTICULAR SEMINOMA
REFERENCES

[1] Zilli T, Boudreau C, Doucet R, et al. Bone marrow-sparing intensity-modulated radiation therapy for Stage I seminoma. Acta Oncol 2011;50:555-562.
[2] Hall EJ, Wuu CS. Radiation-induced second cancers: the impact of 3D-CRT and IMRT. Int J Radiat Oncol Biol Phys 2003;56:83-88.
[3] Ragni G, Somigliana E, Restelli L, et al. Sperm banking and rate of assisted reproduction treatment: insights from a 15-year cryopreservation program for male cancer patients. Cancer 2003;97:1624-1629.
[4] Saito K, Suzuki K, Iwasaki A, et al. Sperm cryopreservation before cancer chemotherapy helps in the emotional battle against cancer. Cancer 2005;104:521-524.
[5] Garmezy B, Pagliaro LC. Choosing treatment for stage I seminoma: who should get what? Oncology (Williston Park) 2009;23:753, 759.
[6] Fossa SD, Horwich A, Russell JM, et al. Optimal planning target volume for stage I testicular seminoma: A Medical Research Council randomized trial. Medical Research Council Testicular Tumor Working Group. J Clin Oncol 1999;17:1146.
[7] Dinniwell R, Chan P, Czarnota G, et al. Pelvic lymph node topography for radiotherapy treatment planning from ferumoxtran-10 contrast-enhanced magnetic resonance imaging. Int J Radiat Oncol Biol Phys 2009;74:844-851.
[8] McMahon CJ, Rofsky NM, Pedrosa I. Lymphatic metastases from pelvic tumors: anatomic classification, characterization, and staging. Radiology 2010;254:31-46.
[9] Bruns F, Bremer M, Meyer A, Karstens JH. Adjuvant radiotherapy in stage I seminoma: is there a role for further reduction of treatment volume? Acta Oncol 2005;44:142-148.
[10] Classen J, Schmidberger H, Meisner C, et al. Para-aortic irradiation for stage I testicular seminoma: results of a prospective study in 675 patients. A trial of the German testicular cancer study group (GTCSG). Br J Cancer 2004;90:2305-2311.
[11] Shih HA, Harisinghani M, Zietman AL, et al. Mapping of nodal disease in locally advanced prostate cancer: rethinking the clinical target volume for pelvic nodal irradiation based on vascular rather than bony anatomy. Int J Radiat Oncol Biol Phys 2005;63:1262-1269.
[12] Boujelbene N, Cosinschi A, Khanfir K, et al. Pure seminoma: a review and update. Radiat Oncol 2011;6:90.
[13] Jones WG, Fossa SD, Mead GM, et al. Randomized trial of 30 versus 20 Gy in the adjuvant treatment of stage I Testicular Seminoma: a report on Medical Research Council Trial TE18, European Organisation for the Research and Treatment of Cancer Trial 30942 (ISRCTN18525328). J Clin Oncol 2005;23:1200-1208.
[14] Classen J, Schmidberger H, Meisner C, Souchon R. Radiotherapy for stages IIA/B testicular seminoma: final report of a prospective multicenter clinical trial. J Clin Oncol 2003;21:1101-1106.
[15] Paly JJ, Efstathiou JA, Hedgire SS, et al. Mapping patterns of nodal metastases in seminoma: rethinking radiotherapy fields. Radiother Oncol 2013;106:64-68.

Note: All recommendations are category 2A unless otherwise indicated.

Version 1.2026, 10/15/2025 © 2025 National Comprehensive Cancer Network® (NCCN®), All rights reserved. NCCN Guidelines® and this illustration may not be reproduced in any form without the express written permission of NCCN.

PLEASE NOTE that use of this NCCN Content is governed by the End-User License Agreement, and you MAY NOT distribute this Content or use it with any artificial intelligence model or tool.
Printed by Máximo López Chenlo on 5/4/2026 6:31:34 PM. Copyright © 2026 National Comprehensive Cancer Network, Inc. All Rights Reserved.

RISK CLASSIFICATION FOR ADVANCED DISEASE (post-orchiectomy)[a,b]

Risk Status	Nonseminoma	Seminoma	Chemotherapy Regimens
Good Risk	Testicular or retroperitoneal primary tumor[c] and No nonpulmonary visceral metastases and Post-orchiectomy markers- all of: AFP < 1,000 ng/mL hCG < 5,000 IU/L LDH < 1.5 x upper limit of normal	Any primary site and No nonpulmonary visceral metastases and Normal AFP Any hCG Any LDH[d]	BEP for 3 cycles or EP for 4 cycles
Intermediate Risk	Testicular or retroperitoneal primary tumor[c] and No nonpulmonary visceral metastases and Post-orchiectomy markers- any of: AFP 1,000–10,000 ng/mL hCG 5,000–50,000 IU/L LDH 1.5–10 x upper limit of normal	Any primary site and Nonpulmonary visceral metastases and Normal AFP Any hCG Any LDH	BEP for 4 cycles or VIP for 4 cycles
Poor Risk	Mediastinal primary tumor[c] or Nonpulmonary visceral metastases or Post-orchiectomy markers- any of: AFP > 10,000 ng/mL hCG > 50,000 IU/L LDH > 10 x upper limit of normal	No patients classified as poor prognosis	BEP for 4 cycles or VIP for 4 cycles

Source: Figure 4 from the International Germ Cell Cancer Collaborative Group: International Germ Cell Consensus Classification: A Prognostic Factor-Based Staging System for Metastatic Germ Cell Cancers. J Clin Oncol 1997;15:594-603. Adapted with permission of the American Society of Clinical Oncology.

[a] Markers used for risk classification are post-orchiectomy.
[b] Newer risk model to give prognostic information can be used through nomogram: https://eortc.shinyapps.io/IGCCCG-Update (Gillessen S, et al. J Clin Oncol 2021;39:1563-1574).
[c] Referral to a high-volume center is recommended for patients with extragonadal germ cell tumors. See Discussion.
[d] Patients with good-risk disseminated seminoma with an LDH >2.5 x ULN have a worse prognosis than other patients with good risk. Consider intensification of therapy for patients with good risk and elevated LDH. See Discussion.

Note: All recommendations are category 2A unless otherwise indicated.

Version 1.2026, 10/15/2025 © 2025 National Comprehensive Cancer Network® (NCCN®), All rights reserved. NCCN Guidelines® and this illustration may not be reproduced in any form without the express written permission of NCCN.

PLEASE NOTE that use of this NCCN Content is governed by the End-User License Agreement, and you MAY NOT distribute this Content or use it with any artificial intelligence model or tool.
Printed by Máximo López Chenlo on 5/4/2026 6:31:34 PM. Copyright © 2026 National Comprehensive Cancer Network, Inc. All Rights Reserved.

FIRST-LINE CHEMOTHERAPY REGIMENS FOR GERM CELL TUMORS

Preferred Regimens

- **BEP**
  Etoposide 100 mg/m² IV on Days 1–5
  Cisplatin 20 mg/m² IV on Days 1–5
  Bleomycin 30 units IV weekly on Days 1, 8, and 15 or Days 2, 9, and 16
  Repeat every 21 days[1]

- **EP**
  (Option only for patients with good risk [TEST-D], patients with pathologic stage II disease, and patients with viable germ cell tumor at surgery following first-line chemotherapy)
  Etoposide 100 mg/m² IV on Days 1–5
  Cisplatin 20 mg/m² IV on Days 1–5
  Repeat every 21 days[2]

Other Recommended Regimens

- **VIP[3]**
  (For patients with intermediate- or poor-risk disease or patients with viable germ cell tumor at surgery following first-line chemotherapy [SEM-5 and NSEM-6])
  Etoposide 75 mg/m² IV on Days 1–5
  Ifosfamide 1200 mg/m² on Days 1–5 with mesna protection
  Cisplatin 20 mg/m² IV on Days 1–5
  Repeat every 21 days[4]

[1] Saxman SB, Finch D, Gonin R, Einhorn LH. Long-term follow-up of a phase III study of three versus four cycles of bleomycin, etoposide, and cisplatin in favorable-prognosis germ-cell tumors: The Indiana University Experience. J Clin Oncol 1998;16:702-706.
[2] Xiao H, Mazumdar M, Bajorin DF, et al. Long-term follow-up of patients with good-risk germ cell tumors treated with etoposide and cisplatin. J Clin Oncol 1997;15:2553-2558.
[3] VIP: This regimen is high risk for febrile neutropenia and granulocyte colony-stimulating factors (G-CSFs) should be used (NCCN Guidelines for Hematopoietic Growth Factors).
[4] Nichols CR, Catalano PJ, Crawford ED, et al. Randomized comparison of cisplatin and etoposide and either bleomycin or ifosfamide in treatment of advanced disseminated germ cell tumors: An Eastern Cooperative Oncology Group, Southwest Oncology Group, and Cancer and Leukemia Group B Study. J Clin Oncol 1998;16:1287-1293.

Note: All recommendations are category 2A unless otherwise indicated.

Version 1.2026, 10/15/2025 © 2025 National Comprehensive Cancer Network® (NCCN®), All rights reserved. NCCN Guidelines® and this illustration may not be reproduced in any form without the express written permission of NCCN.

PLEASE NOTE that use of this NCCN Content is governed by the End-User License Agreement, and you MAY NOT distribute this Content or use it with any artificial intelligence model or tool.
Printed by Máximo López Chenlo on 5/4/2026 6:31:34 PM. Copyright © 2026 National Comprehensive Cancer Network, Inc. All Rights Reserved.

SECOND-LINE CHEMOTHERAPY REGIMENS FOR METASTATIC GERM CELL TUMORS

Conventional-Dose Chemotherapy Regimens

Preferred Regimens

- **TIP[1]**
  Paclitaxel 250 mg/m² IV on Day 1
  Ifosfamide 1500 mg/m² IV on Days 2–5 with mesna protection
  Cisplatin 25 mg/m² IV on Days 2–5
  Repeat every 21 days[2]

- **VeIP[1]**
  Vinblastine 0.11 mg/kg IV on Days 1–2
  Ifosfamide 1200 mg/m² IV on Days 1–5 with mesna protection
  Cisplatin 20 mg/m² IV on Days 1–5
  Repeat every 21 days[3]

High-Dose Chemotherapy Regimens

Preferred Regimens

- **Carboplatin/Etoposide**
  Carboplatin 700 mg/m²/day (body surface area) IV administered on Days -5, -4, and -3
  Etoposide 750 mg/m²/day IV administered on Days -5, -4, and -3
  Administer Days -5, -4, and -3 before peripheral blood stem cell infusion for 2 cycles[4]

- **Paclitaxel/Ifosfamide/Carboplatin/Etoposide**
  Paclitaxel 200 mg/m² IV over 24 hours on Day 1
  Ifosfamide 2000 mg/m² over 4 hours with mesna protection on Days 2–4
  Repeat every 14 days for 2 cycles followed by
  Carboplatin AUC 7–8 IV over 60 minutes on Days 1–3
  Etoposide 400 mg/m² IV on Days 1–3
  Administer with peripheral blood stem cell support at 14- to 21-day intervals for 3 cycles[5]

[1] TIP, VeIP: These regimens are high risk for febrile neutropenia and G-CSFs should be used (NCCN Guidelines for Hematopoietic Growth Factors).

[2] Kondagunta GV, Bacik J, Donadio A, et al. Combination of paclitaxel, ifosfamide, and cisplatin is an effective second-line therapy for patients with relapsed testicular germ cell tumors. J Clin Oncol 2005;23:6549-6555.

[3] Loehrer PJ Sr, Lauer R, Roth BJ, et al. Salvage therapy in recurrent germ cell cancer: ifosfamide and cisplatin plus either vinblastine or etoposide. Ann Intern Med 1988;109:540-546.

[4] Einhorn LH, Williams SD, Chamness A, et al. High-dose chemotherapy and stem-cell rescue for metastatic germ-cell tumors. N Engl J Med 2007;357:340-348.

[5] Feldman DR, Sheinfeld J, Bajorin DF, et al. TI-CE high-dose chemotherapy for patients with previously treated germ cell tumors: Results and prognostic factor analysis. J Clin Oncol 2010;28:1706-1713.

Note: All recommendations are category 2A unless otherwise indicated.

Version 1.2026, 10/15/2025 © 2025 National Comprehensive Cancer Network® (NCCN®), All rights reserved. NCCN Guidelines® and this illustration may not be reproduced in any form without the express written permission of NCCN.

PLEASE NOTE that use of this NCCN Content is governed by the End-User License Agreement, and you MAY NOT distribute this Content or use it with any artificial intelligence model or tool.
Printed by Máximo López Chenlo on 5/4/2026 6:31:34 PM. Copyright © 2026 National Comprehensive Cancer Network, Inc. All Rights Reserved.

THIRD-LINE SYSTEMIC THERAPY REGIMENS FOR METASTATIC GERM CELL TUMORS[a,b]
High-Dose Chemotherapy NOT Previously Received

- **Pan-cancer, tumor-agnostic treatments can be considered for patients with actionable mutations.**

Preferred Regimens (High-Dose Chemotherapy)

- **Carboplatin/Etoposide**
  Carboplatin 700 mg/m²/day (body surface area) IV administered on days -5, -4, and -3
  Etoposide 750 mg/m²/day IV administered on Days -5, -4, and -3
  Administered Days -5, -4, and -3 before peripheral blood stem cell infusion for 2 cycles[1]
- **Paclitaxel/Ifosfamide/Carboplatin/Etoposide**
  Paclitaxel 200 mg/m² IV over 24 hours on Day 1
  Ifosfamide 2000 mg/m² over 4 hours with mesna protection on Days 2–4
  Repeat every 14 days for 2 cycles followed by
  Carboplatin AUC 7–8 IV over 60 minutes on Days 1–3
  Etoposide 400 mg/m² IV on Days 1–3
  Administered with peripheral blood stem cell support at 14- to 21-day intervals for 3 cycles[2]

Other Recommended Regimens

- **Gemcitabine/Oxaliplatin/Paclitaxel[3]**
  Gemcitabine 800 mg/m² IV over 30 minutes on Days 1 and 8
  Paclitaxel 80 mg/m² IV over 60 minutes on Days 1 and 8
  Oxaliplatin 130 mg/m² IV over 2 hours on Day 1
  Administered on a 21-day cycle for 8 cycles
- **Gemcitabine/Oxaliplatin[4-6]**
  Gemcitabine 1000–1250 mg/m² IV over 30 minutes on Days 1 and 8 followed by
  Oxaliplatin 130 mg/m² IV over 2 hours on Day 1
  Administered on a 21-day cycle until disease progression or unacceptable toxicity
- **Gemcitabine/Paclitaxel[7,8]**
  Gemcitabine 1000 mg/m² IV over 30 minutes on Days 1, 8, and 15
  Paclitaxel 100 mg/m² IV over 60 minutes on Days 1, 8, and 15
  Administered on a 28-day cycle for 6 cycles
- **Oral Etoposide[9]**
  Etoposide 50–100 mg PO daily on Days 1–21
  Administered on a 28-day cycle until disease progression or unacceptable toxicity

[a] Studies on other regimens in this setting have been published that could be useful in certain circumstances. See Discussion for more information.

[b] If VeIP or TIP received as second-line therapy, high-dose chemotherapy is the preferred third-line option.

Note: All recommendations are category 2A unless otherwise indicated.

References

Version 1.2026, 10/15/2025 © 2025 National Comprehensive Cancer Network® (NCCN®), All rights reserved. NCCN Guidelines® and this illustration may not be reproduced in any form without the express written permission of NCCN.

PLEASE NOTE that use of this NCCN Content is governed by the End-User License Agreement, and you MAY NOT distribute this Content or use it with any artificial intelligence model or tool.
Printed by Máximo López Chenlo on 5/4/2026 6:31:34 PM. Copyright © 2026 National Comprehensive Cancer Network, Inc. All Rights Reserved.

THIRD-LINE SYSTEMIC THERAPY REGIMENS FOR METASTATIC GERM CELL TUMORS[a,b]
High-Dose Chemotherapy Previously Received

- **Pan-cancer, tumor-agnostic treatments can be considered for patients with actionable mutations.**

Preferred Regimens

- **Gemcitabine/Oxaliplatin/Paclitaxel[3]**
  Gemcitabine 800 mg/m² IV over 30 minutes on Days 1 and 8
  Paclitaxel 80 mg/m² IV over 60 minutes on Days 1 and 8
  Oxaliplatin 130 mg/m² IV over 2 hours on Day 1
  Administered on a 21-day cycle for 8 cycles
- **Gemcitabine/Oxaliplatin[4-6]**
  Gemcitabine 1000–1250 mg/m² IV over 30 minutes on Days 1 and 8
  followed by
  Oxaliplatin 130 mg/m² IV over 2 hours on Day 1
  Administered on a 21-day cycle until disease progression or unacceptable toxicity
- **Gemcitabine/Paclitaxel[7,8]**
  Gemcitabine 1000 mg/m² IV over 30 minutes on Days 1, 8, and 15
  Paclitaxel 100 mg/m² IV over 60 minutes on Days 1, 8, and 15
  Administered on a 28-day cycle for 6 cycles
- **Oral Etoposide[9]**
  Etoposide 50–100 mg PO daily on Days 1–21
  Administered on a 28-day cycle until disease progression or unacceptable toxicity

[a] Studies on other regimens in this setting have been published that could be useful in certain circumstances. See Discussion for more information.

[b] If VeIP or TIP received as second-line therapy, high-dose chemotherapy is the preferred third-line option.

Note: All recommendations are category 2A unless otherwise indicated.

References

Version 1.2026, 10/15/2025 © 2025 National Comprehensive Cancer Network® (NCCN®), All rights reserved. NCCN Guidelines® and this illustration may not be reproduced in any form without the express written permission of NCCN.

PLEASE NOTE that use of this NCCN Content is governed by the End-User License Agreement, and you MAY NOT distribute this Content or use it with any artificial intelligence model or tool.
Printed by Máximo López Chenlo on 5/4/2026 6:31:34 PM. Copyright © 2026 National Comprehensive Cancer Network, Inc. All Rights Reserved.

THIRD-LINE SYSTEMIC THERAPY REGIMENS FOR METASTATIC GERM CELL TUMORS
REFERENCES

[1] Einhorn LH, Williams SD, Chamness A, et al. High-dose chemotherapy and stem-cell rescue for metastatic germ-cell tumors. N Engl J Med 2007;357:340-348.
[2] Feldman DR, Sheinfeld J, Bajorin DF, et al. TI-CE high-dose chemotherapy for patients with previously treated germ cell tumors: Results and prognostic factor analysis. J Clin Oncol 2010;28:1706-1713.
[3] Bokemeyer C, Oechsle K, Honecker F, et al; German Testicular Cancer Study Group. Combination chemotherapy with gemcitabine, oxaliplatin, and paclitaxel in patients with cisplatin-refractory or multiply relapsed germ-cell tumors: A study of the German Testicular Cancer Study Group. Ann Oncol 2008;19:448-453.
[4] Pectasides D, Pectasides M, Farmakis D, et al. Gemcitabine and oxaliplatin (GEMOX) in patients with cisplatin-refractory germ cell tumors: a phase II study. Ann Oncol 2004;15:493-497.
[5] Kollmannsberger C, Beyer J, Liersch R, et al. Combination chemotherapy with gemcitabine plus oxaliplatin in patients with intensively pretreated or refractory germ cell cancer: a study of the German Testicular Cancer Study Group. J Clin Oncol 2004;22:108-114.
[6] De Giorgi U, Rosti G, Aieta M, et al. Phase II study of oxaliplatin and gemcitabine salvage chemotherapy in patients with cisplatin-refractory nonseminomatous germ cell tumor. Eur Urol 2006;50:1032-1038.
[7] Einhorn LH, Brames MJ, Juliar B, Williams SD. Phase II study of paclitaxel plus gemcitabine salvage chemotherapy for germ cell tumors after progression following high-dose chemotherapy with tandem transplant. J Clin Oncol 2007;25:513-516.
[8] Mulherin BP, Brames MJ, Einhorn LH. Long-term survival with paclitaxel and gemcitabine for germ cell tumors after progression following high-dose chemotherapy with tandem transplant. Am J Clin Oncol 2015;38:373-376.
[9] Miller JC, Einhorn LH. Phase II study of daily oral etoposide in refractory germ cell tumors. Semin Oncol 1990;17:36-39.

Note: All recommendations are category 2A unless otherwise indicated.

Version 1.2026, 10/15/2025 © 2025 National Comprehensive Cancer Network® (NCCN®), All rights reserved. NCCN Guidelines® and this illustration may not be reproduced in any form without the express written permission of NCCN.

PLEASE NOTE that use of this NCCN Content is governed by the End-User License Agreement, and you MAY NOT distribute this Content or use it with any artificial intelligence model or tool.
Printed by Máximo López Chenlo on 5/4/2026 6:31:34 PM. Copyright © 2026 National Comprehensive Cancer Network, Inc. All Rights Reserved.

PRINCIPLES OF SURGERY FOR GERM CELL TUMORS

- **Radical inguinal orchiectomy is the gold standard for the diagnosis and initial management of a suspected testicular cancer. Trans-scrotal orchiectomy is discouraged, as scrotal violation is associated with higher rates of local recurrence and altered pathways of metastatic dissemination.**
  - **When a patient presents with a testicular mass, rapidly increasing beta-hCG[a] or AFP, metastatic disease on imaging, and symptoms related to disseminated disease, chemotherapy can be initiated immediately without waiting for orchiectomy or a biopsy-proven histologic diagnosis. However, radical inguinal orchiectomy should be performed at completion of chemotherapy.**
- **For an equivocal mass <2 cm with normal serum AFP and beta-hCG, short-interval imaging is can be considered prior to partial orchiectomy.**
- **Use of a testicular prosthesis should be discussed prior to radical inguinal orchiectomy.**
- **Fertility counseling should be considered prior to surgery with potential sperm banking. If warranted by semen analysis, sperm extraction during orchiectomy (Onco-Testicular Sperm Extraction [OncoTESE]) can be considered [see NCCN Guidelines for Adolescent and Young Adult (AYA) Oncology].**

Testis-Sparing Surgery (TSS)

- **TSS (partial orchiectomy) can be considered in select patients with a testicular mass.**
  - **Relative indications for TSS:**
    - ◊ **Equivocal mass in the setting of bilateral, otherwise normal testes**
    - ◊ **Synchronous bilateral tumors**
    - ◊ **Solitary testicle with a mass suspicious for germ cell tumor, or a functionally solitary testicle (eg, contralateral testicular atrophy) with adequate gonadal function (androgen and/or sperm production)**
  - **These patients should be counseled regarding the following:**
    - ◊ **Higher risk of local recurrence with TSS**
    - ◊ **Need for continued surveillance with testicular self-exam, exam by a physician, and/or ultrasound**
    - ◊ **Option of adjuvant radiation[b] to reduce the risk of local recurrence**
    - ◊ **Potential impact of RT on sperm and testosterone production[c]**
    - ◊ **Risk of testicular atrophy, need for testosterone replacement, and/or infertility**
  - **Principles of TSS:**
    - ◊ **TSS should be performed through an inguinal approach.**
    - ◊ **Frozen section of the tumor and surrounding parenchyma should be performed by an experienced genitourinary pathologist.**
      - – **Preoperative discussion is recommended regarding plan for completion of orchiectomy versus preservation based on frozen section results.**
    - ◊ **In the setting of a normal contralateral testicle, radical orchiectomy is recommended if biopsy shows testicular cancer.**

[a] If beta-hCG is only mildly elevated (eg, <50 mIU/mL) in the setting of normal AFP, recommend radical orchiectomy before chemotherapy. In scenarios of isolated hCG elevation, biopsy (either orchiectomy or percutaneous) may be considered in equivocal cases as the histology may impact management of post-chemotherapy residual masses.

[b] Principles of Radiotherapy (TEST-C).

[c] There will be no ipsilateral sperm production. Most data suggest approximately 50%–60% of patients will maintain endogenous testosterone production and be able to refrain from using supplementation.

Note: All recommendations are category 2A unless otherwise indicated.

Version 1.2026, 10/15/2025 © 2025 National Comprehensive Cancer Network® (NCCN®), All rights reserved. NCCN Guidelines® and this illustration may not be reproduced in any form without the express written permission of NCCN.

PLEASE NOTE that use of this NCCN Content is governed by the End-User License Agreement, and you MAY NOT distribute this Content or use it with any artificial intelligence model or tool.
Printed by Máximo López Chenlo on 5/4/2026 6:31:34 PM. Copyright © 2026 National Comprehensive Cancer Network, Inc. All Rights Reserved.

PRINCIPLES OF SURGERY FOR GERM CELL TUMORS

General Principles of Retroperitoneal Lymph Node Dissection (RPLND)

- Referral to high-volume centers should be considered.
- Dissection should include mass resection, lymphatic tissue around and behind the great vessels (ie, aorta, IVC), and the affected spermatic cord.
  - Techniques to facilitate removal of all lymphoid tissue include the "split and roll" technique in which lumbar vessels are identified and sequentially ligated.
- Nerve-sparing approaches should be prioritized, if clinically appropriate, to minimize the risk of ejaculatory disorders; this requires knowledge of ejaculatory neuroanatomy (sympathetic chain, post-sympathetic fibers from T12–L2, and hypogastric plexus).
  - If future fertility is a consideration, preoperative sperm banking should be recommended.
  - Template dissection can also be considered.
  - Oncologic efficacy should never be compromised for the maintenance of ejaculation.
- Careful evaluation of pre- and post-chemotherapy imaging to ascertain any vascular anomalies or anatomic variants that many complicate surgery should be performed.
- Strategies to facilitate enhanced recovery are encouraged (eg, regional anesthesia, peripherally acting μ-opioid receptor antagonists).

Primary RPLND

- The goal is long-term curative intent and may include intraoperatively expanding the planned field of resection based on intraoperative confirmation of cancer.
- Minimally invasive approaches (laparoscopic or robotic) can be considered in select cases at high-volume centers.
  - Oncologic principles should not be compromised and should be identical to the open approach.

Post-Chemotherapy RPLND

- Indicated in patients with metastatic NSGCT with a residual retroperitoneal mass (>1 on axial imaging) following systemic chemotherapy and normalized postchemotherapy serum tumor markers.
  - Additional procedures and resection of adjacent structures may be required.
  - Multidisciplinary surgical teams may be required.
- A full bilateral template should be strongly considered in all patients with the boundaries being the renal hilar vessels (superiorly), ureters (laterally), and the common iliac arteries (inferiorly).
  - Modified templates may be an option in select patients with International Germ-Cell Cancer Collaborative Group (IGCCCG) good-risk disease confined to the primary landing zones.
- Minimally invasive laparoscopic or robotic approaches to RPLND have limited long-term data; they can be considered in highly select cases at high-volume centers.
- In the setting of reoperation, late relapse, malignant transformation, or after second-line therapy, RPLND can be extraordinarily complex and requisite experience is needed to optimize outcome. Evaluation by an experienced multidisciplinary team is strongly encouraged.

Note: All recommendations are category 2A unless otherwise indicated.

Version 1.2026, 10/15/2025 © 2025 National Comprehensive Cancer Network® (NCCN®), All rights reserved. NCCN Guidelines® and this illustration may not be reproduced in any form without the express written permission of NCCN.

PLEASE NOTE that use of this NCCN Content is governed by the End-User License Agreement, and you MAY NOT distribute this Content or use it with any artificial intelligence model or tool.
Printed by Máximo López Chenlo on 5/4/2026 6:31:34 PM. Copyright © 2026 National Comprehensive Cancer Network, Inc. All Rights Reserved.

PRINCIPLES OF IMAGING

Staging

Pure Seminoma and Nonseminoma

- **Abdomen/pelvis CT scan with contrast (or abdomen/pelvis MRI with and without contrast) and chest x-ray are recommended within 4 weeks prior to the initiation of chemotherapy, RPLND, or RT to confirm staging, even if scan was performed previously (SEM-2 and NSEM-2).**
  - **Chest CT should be performed if abdomen/pelvis CT or chest x-ray is abnormal.**

Treatment Response Assessment

Pure Seminoma

- **Consider FDG-PET/CT scan (skull base to mid-thigh) for a residual mass >3 cm post primary chemotherapy (SEM-5).**
- **FDG-PET/CT scan should be performed at least 6 weeks following completion of chemotherapy.**
  - **A negative FDG-PET/CT following chemotherapy is very reassuring. If FDG-PET/CT scan is positive, resection or interventional radiology-guided biopsy should be considered. An alternative is to wait an additional 6–12 weeks and repeat imaging to assess for changes. If the mass is persistently positive then resection or biopsy is recommended.**

Surveillance

Pure Seminoma and Nonseminoma (TEST-A and TEST-B)

- **MRI with and without contrast can be considered in place of an abdomen/pelvis CT.**
  - **MRI protocol should include visualization of retroperitoneal and pelvic nodes.**
- **Use the same imaging modality (CT or MRI) throughout surveillance.**
- **In stage I seminoma and nonseminoma, chest x-rays should be obtained when abdomen/pelvis CT scans are performed. Additional chest imaging is not indicated under normal circumstances. In a retrospective review of nearly 560 patients, 76 patients relapsed with only four patients having disease in the chest, one of whom had an abnormal chest x-ray (but also in the setting of an elevated AFP).[1] Similar data from Daugaard et al showed no role for chest x-ray in detecting relapse.[2] Other series have also called into question the value of chest x-rays in this and other surveillance settings for germ cell tumors.[3,4]**

[1] De La Pena H, Sharma A, Glicksman C, et al. No longer any role for routine follow-up chest x-rays in men with stage I germ cell cancer. Eur J Cancer 2017;84:354-359.
[2] Daugaard G, Gundgaard MG, Mortensen MS, et al. Surveillance for stage I nonseminoma testicular cancer: outcomes and long-term follow-up in a population-based cohort. J Clin Oncol 2014;32:3817-3823.
[3] Tolan S, Vesprini D, Jewett MA, et al. No role for routine chest radiography in stage I seminoma surveillance. Eur Urol 2010;57:474-479.
[4] Gietema JA, Meinardi MT, Sleijfer DT, et al. Routine chest X-rays have no additional value in the detection of relapse during routine follow-up of patients treated with chemotherapy for disseminated non-seminomatous testicular cancer. Ann Oncol 2002;13:1616-1620.

Note: All recommendations are category 2A unless otherwise indicated.

Version 1.2026, 10/15/2025 © 2025 National Comprehensive Cancer Network® (NCCN®), All rights reserved. NCCN Guidelines® and this illustration may not be reproduced in any form without the express written permission of NCCN.

PLEASE NOTE that use of this NCCN Content is governed by the End-User License Agreement, and you MAY NOT distribute this Content or use it with any artificial intelligence model or tool.
Printed by Máximo López Chenlo on 5/4/2026 6:31:34 PM. Copyright © 2026 National Comprehensive Cancer Network, Inc. All Rights Reserved.

American Joint Committee on Cancer (AJCC)
TNM Staging Classification for Testis Cancer 8th ed., 2017

Table 1. **Definitions for T, N, M**

Clinical T	Primary Tumor
cTX	Primary tumor cannot be assessed
cT0	No evidence of primary tumor
cTis	Germ cell neoplasia *in situ*
cT4	Tumor invades scrotum with or without vascular/lymphatic invasion

Note: Except for Tis confirmed by biopsy and T4, the extent of the primary tumor is classified by radical orchiectomy. TX may be used for other categories for clinical staging.

Pathological T	Primary Tumor
pTX	Primary tumor cannot be assessed
pT0	No evidence of primary tumor
pTis	Germ cell neoplasia *in situ*
pT1	Tumor limited to testis (including rete testis invasion) without lymphovascular invasion
pT1a*	Tumor smaller than 3 cm in size
pT1b*	Tumor 3 cm or larger in size
pT2	Tumor limited to testis (including rete testis invasion) with lymphovascular invasion OR Tumor invading hilar soft tissue or epididymis or penetrating visceral mesothelial layer covering the external surface of tunica albuginea with or without lymphovascular invasion
pT3	Tumor directly invades spermatic cord soft tissue with or without lymphovascular invasion
pT4	Tumor invades scrotum with or without lymphovascular invasion

Subclassification of pT1 applies to only pure seminoma.

Continued

Used with permission of the American College of Surgeons, Chicago, Illinois. The original source for this information is the AJCC Cancer Staging Manual, Eighth Edition (2017) published by Springer International Publishing.

Version 1.2026, 10/15/2025 © 2025 National Comprehensive Cancer Network® (NCCN®), All rights reserved. NCCN Guidelines® and this illustration may not be reproduced in any form without the express written permission of NCCN.

PLEASE NOTE that use of this NCCN Content is governed by the End-User License Agreement, and you MAY NOT distribute this Content or use it with any artificial intelligence model or tool.
Printed by Máximo López Chenlo on 5/4/2026 6:31:34 PM. Copyright © 2026 National Comprehensive Cancer Network, Inc. All Rights Reserved.

American Joint Committee on Cancer (AJCC)
TNM Staging Classification for Testis Cancer 8th ed., 2017

***Table 1* (continued)**

Clinical N	Regional Lymph Nodes
cNX	Regional lymph nodes cannot be assessed
cN0	No regional lymph node metastasis
cN1	Metastasis with a lymph node mass 2 cm or smaller in greatest dimension OR Multiple lymph nodes, none larger than 2 cm in greatest dimension
cN2	Metastasis with a lymph node mass larger than 2 cm but not larger than 5 cm in greatest dimension OR Multiple lymph nodes, any one mass larger than 2 cm but not larger than 5 cm in greatest dimension
cN3	Metastasis with a lymph node mass larger than 5 cm in greatest dimension

Pathological N	Regional Lymph Nodes
pNX	Regional lymph nodes cannot be assessed
pN0	No regional lymph node metastasis
pN1	Metastasis with a lymph node mass 2 cm or smaller in greatest dimension and less than or equal to five nodes positive, none larger than 2 cm in greatest dimension
pN2	Metastasis with a lymph node mass larger than 2 cm but not larger than 5 cm in greatest dimension; or more than five nodes positive, none larger than 5 cm; or evidence of extranodal extension of tumor
pN3	Metastasis with a lymph node mass larger than 5 cm in greatest dimension

M		Distant Metastasis
M0		No distant metastases
M1		Distant metastases
	M1a	Non-retroperitoneal nodal or pulmonary metastases
	M1b	Non-pulmonary visceral metastases

S	Serum Markers
SX	Marker studies not available or not performed
S0	Marker study levels within normal limits
S1	LDH <1.5 x N* and hCG (mIU/mL) <5,000 *and* AFP (ng/mL) <1,000
S2	LDH 1.5–10 x N* or hCG (mIU/mL) 5,000–50,000 *or* AFP (ng/mL) 1,000–10,000
S3	LDH >10 x N* or hCG (mIU/mL) >50,000 *or* AFP (ng/mL) >10,000

Continued

* N indicates the upper limit of normal for the LDH assay.
Used with permission of the American College of Surgeons, Chicago, Illinois. The original source for this information is the AJCC Cancer Staging Manual, Eighth Edition (2017) published by Springer International Publishing.

Version 1.2026, 10/15/2025 © 2025 National Comprehensive Cancer Network® (NCCN®), All rights reserved. NCCN Guidelines® and this illustration may not be reproduced in any form without the express written permission of NCCN.

PLEASE NOTE that use of this NCCN Content is governed by the End-User License Agreement, and you MAY NOT distribute this Content or use it with any artificial intelligence model or tool.
Printed by Máximo López Chenlo on 5/4/2026 6:31:34 PM. Copyright © 2026 National Comprehensive Cancer Network, Inc. All Rights Reserved.

American Joint Committee on Cancer (AJCC)
TNM Staging Classification for Testis Cancer 8th ed., 2017

Table 2. **AJCC Prognostic Stage Groups**

	T	N	M	S
Stage 0	pTis	N0	M0	S0
Stage I	pT1-T4	N0	M0	SX
Stage IA	pT1	N0	M0	S0
Stage IB	pT2	N0	M0	S0
	pT3	N0	M0	S0
	pT4	N0	M0	S0
Stage IS	Any pT/TX	N0	M0	S1-3
Stage II	Any pT/TX	N1-3	M0	SX
Stage IIA	Any pT/TX	N1	M0	S0
	Any pT/TX	N1	M0	S1
Stage IIB	Any pT/TX	N2	M0	S0
	Any pT/TX	N2	M0	S1
Stage IIC	Any pT/TX	N3	M0	S0
	Any pT/TX	N3	M0	S1
Stage III	Any pT/TX	Any N	M1	SX
Stage IIIA	Any pT/TX	Any N	M1a	S0
	Any pT/TX	Any N	M1a	S1
Stage IIIB	Any pT/TX	N1-3	M0	S2
	Any pT/TX	Any N	M1a	S2
Stage IIIC	Any pT/TX	N1-3	M0	S3
	Any pT/TX	Any N	M1a	S3
	Any pT/TX	Any N	M1b	Any S

Histologic Grade (G)

- **Germ cell tumors are not graded**

Used with permission of the American College of Surgeons, Chicago, Illinois. The original source for this information is the AJCC Cancer Staging Manual, Eighth Edition (2017) published by Springer International Publishing.

Version 1.2026, 10/15/2025 © 2025 National Comprehensive Cancer Network® (NCCN®), All rights reserved. NCCN Guidelines® and this illustration may not be reproduced in any form without the express written permission of NCCN.

PLEASE NOTE that use of this NCCN Content is governed by the End-User License Agreement, and you MAY NOT distribute this Content or use it with any artificial intelligence model or tool.
Printed by Máximo López Chenlo on 5/4/2026 6:31:34 PM. Copyright © 2026 National Comprehensive Cancer Network, Inc. All Rights Reserved.

ABBREVIATIONS

3D-CRT	three-dimensional conformal radiation therapy
AFP	alpha-fetoprotein
AP-PA	anteroposterior-posteroanterior
AUC	area under the curve
beta-hCG	beta-human chorionic gonadotropin
C/A/P	chest, abdomen, pelvis
D50%	dose delivered to 50% of the volume
G-CSF	granulocyte colony-stimulating factor
GFR	glomerular filtration rate
H&P	history and physical
hCG	human chorionic gonadotropin
IGCCCG	International Germ-Cell Cancer Collaborative Group
IMRT	intensity-modulated radiation therapy
IVC	inferior vena cava
LDH	lactate dehydrogenase
NSGCT	nonseminomatous germ cell tumor
OncoTESE	Onco-Testicular Sperm Extraction
RPLND	retroperitoneal lymph node dissection
TSS	testis sparing surgery
ULN	upper limit of normal

Version 1.2026, 10/15/2025 © 2025 National Comprehensive Cancer Network® (NCCN®), All rights reserved. NCCN Guidelines® and this illustration may not be reproduced in any form without the express written permission of NCCN.

PLEASE NOTE that use of this NCCN Content is governed by the End-User License Agreement, and you MAY NOT distribute this Content or use it with any artificial intelligence model or tool.
Printed by Máximo López Chenlo on 5/4/2026 6:31:34 PM. Copyright © 2026 National Comprehensive Cancer Network, Inc. All Rights Reserved.

NCCN Categories of Evidence and Consensus	
Category 1	Based upon high-level evidence (≥1 randomized phase 3 trials or high-quality, robust meta-analyses), there is uniform NCCN consensus (≥85% support of the Panel) that the intervention is appropriate.
Category 2A	Based upon lower-level evidence, there is uniform NCCN consensus (≥85% support of the Panel) that the intervention is appropriate.
Category 2B	Based upon lower-level evidence, there is NCCN consensus (≥50%, but <85% support of the Panel) that the intervention is appropriate.
Category 3	Based upon any level of evidence, there is major NCCN disagreement that the intervention is appropriate.

All recommendations are category 2A unless otherwise indicated.

NCCN Categories of Preference	
Preferred intervention	Interventions that are based on superior efficacy, safety, and evidence; and, when appropriate, affordability.
Other recommended intervention	Other interventions that may be somewhat less efficacious, more toxic, or based on less mature data; or significantly less affordable for similar outcomes.
Useful in certain circumstances	Other interventions that may be used for selected patient populations (defined with recommendation).

All recommendations are considered appropriate.

Note: All recommendations are category 2A unless otherwise indicated.

Version 1.2026, 10/15/2025 © 2025 National Comprehensive Cancer Network® (NCCN®), All rights reserved. NCCN Guidelines® and this illustration may not be reproduced in any form without the express written permission of NCCN.

PLEASE NOTE that use of this NCCN Content is governed by the End-User License Agreement, and you MAY NOT distribute this Content or use it with any artificial intelligence model or tool.
Printed by Máximo López Chenlo on 5/4/2026 6:31:34 PM. Copyright © 2026 National Comprehensive Cancer Network, Inc. All Rights Reserved.

Discussion

This discussion corresponds to the NCCN Guidelines for Testicular Cancer. Last updated on March 25, 2025.

Table of Contents

Overview **MS-2**

Guidelines Update Methodology **MS-2**

Literature Search Criteria **MS-2**

Sensitive/Inclusive Language Usage **MS-3**

Clinical Presentation, Workup, and Primary Treatment **MS-3**

Clinical Presentation MS-3

Workup MS-3

Primary Treatment MS-5

Staging **MS-5**

Risk Classification for Advanced Disease MS-7

Pure Seminoma **MS-7**

Pure Seminoma Stages IA and IB MS-8

Pure Seminoma Stage IS MS-12

Pure Seminoma Stages IIA and IIB MS-12

Pure Seminoma Stages IIC and III MS-15

Nonseminoma **MS-17**

Nonseminoma Stage I With and Without Risk Factors MS-17

Nonseminoma Stage IS MS-19

Nonseminoma Stage IIA and IIB MS-20

Advanced Metastatic Nonseminoma MS-22

Second-Line and Subsequent Therapy for Metastatic Germ Cell Tumors **MS-24**

Second-Line Therapy MS-24

Third-Line Therapy MS-26

Treatment of Brain Metastases **MS-27**

Malignant Transformation of Teratoma **MS-27**

Summary **MS-28**

References **MS-29**

Discussion update in progress

Version 1.2026 © 2025 National Comprehensive Cancer Network® (NCCN©), All rights reserved. NCCN Guidelines® and this illustration may not be reproduced in any form without the express written permission of NCCN.

PLEASE NOTE that use of this NCCN Content is governed by the End-User License Agreement, and you MAY NOT distribute this Content or use it with any artificial intelligence model or tool.
Printed by Máximo López Chenlo on 5/4/2026 6:31:34 PM. Copyright © 2026 National Comprehensive Cancer Network, Inc. All Rights Reserved.

Overview

Testicular cancer accounts for <1% of new cancer cases with a majority of patients being diagnosed between the ages of 20 and 34 years.[1,2] The global incidence of this disease has been steadily rising over the past several decades with an estimated 9720 new cases of testicular cancer projected to be diagnosed in the United States in 2025.[3-10] An estimated 600 deaths will occur from testicular cancer in the United States in 2025, reflecting the excellent 5-year relative survival rate for this disease (~94%).[2,3,11] Several risk factors for testicular cancer have been identified, including personal or family history of testicular cancer and cryptorchidism.[4,12,13]

Germ cell tumors (GCTs) comprise 95% of malignant tumors arising in the testes and are broadly categorized into two main histologic subtypes: seminoma and nonseminoma.[4,14,15] Seminomas and nonseminomas typically occur at about the same rate, but nonseminomas tend to be more aggressive and often include multiple cell types. When both seminoma and elements of nonseminoma are present, management follows that of a nonseminoma. The four types of nonseminomas are embryonal carcinoma, choriocarcinoma, yolk sac tumor, and teratoma.[14] Most nonseminomas are mixed tumors of these four subtypes. Teratomas can be classified as either mature or immature, but this does not affect treatment in these patients. Rarely, a teratoma may contain elements of a somatic cancer, such as a sarcoma or adenocarcinoma, and is then referred to as a teratoma with somatic-type malignancy. Teratomas with somatic-type malignancy are managed differently from other GCTs. Prepubertal teratomas, which are biologically different from the much more common post-pubertal teratomas, are occasionally diagnosed in adults and are less aggressive and managed differently.[16,17]

Together, these guidelines pertain to all stages of testicular GCTs and should be closely followed to maximize the potential for cure and to avoid unnecessary side effects, complications, and late toxicities. It is important to note that pediatric GCTs are managed differently from adult GCTs and are not covered in these guidelines. Testicular tumors arising from the stroma (eg, Leydig cell tumors and Sertoli cell tumors) are also not covered in these guidelines as they account for <5% of cases and have a different biology and natural history.

Guidelines Update Methodology

The complete details of the development and update of the NCCN Guidelines are available at www.NCCN.org.

Literature Search Criteria

Prior to the update of this version of the NCCN Clinical Practice Guidelines in Oncology (NCCN Guidelines®) for Testicular Cancer, an electronic search of the PubMed database was performed using the following search terms: 'testicular cancer' and 'germ cell tumor.' The PubMed database was chosen as it remains the most widely used resource for medical literature and indexes peer-reviewed biomedical literature.

The search results were narrowed by selecting studies in humans published in English. Results were confined to the following article types: Clinical Trial, Phase II; Clinical Trial, Phase III; Clinical Trial, Phase IV; Guideline; Randomized Controlled Trial; Meta-Analysis; Systematic Reviews; and Validation Studies.

The data from key PubMed articles as well as articles from additional sources deemed as relevant to these Guidelines and/or discussed by the Panel have been included in this version of the Discussion section (eg, e-publications ahead of print, meeting abstracts). Any recommendations for which high-level evidence is lacking are based on the Panel's review of lower-level evidence and expert opinion.

Discussion update in progress

Version 1.2026 © 2025 National Comprehensive Cancer Network© (NCCN©), All rights reserved. NCCN Guidelines® and this illustration may not be reproduced in any form without the express written permission of NCCN.

PLEASE NOTE that use of this NCCN Content is governed by the End-User License Agreement, and you MAY NOT distribute this Content or use it with any artificial intelligence model or tool.
Printed by Máximo López Chenlo on 5/4/2026 6:31:34 PM. Copyright © 2026 National Comprehensive Cancer Network, Inc. All Rights Reserved.

Sensitive/Inclusive Language Usage

NCCN Guidelines® strive to use language that advances the goals of equity, inclusion, and representation. NCCN Guidelines endeavor to use language that is person-first; not stigmatizing; anti-racist, anti-classist, anti-misogynist, anti-ageist, anti-ableist, and anti-weight-biased; and inclusive of individuals of all sexual orientations and gender identities. NCCN Guidelines incorporate non-gendered language, instead focusing on organ-specific recommendations. This language is both more accurate and more inclusive and can help fully address the needs of individuals of all sexual orientations and gender identities. NCCN Guidelines will continue to use the terms men, women, female, and male when citing statistics, recommendations, or data from organizations or sources that do not use inclusive terms. Most studies do not report how sex and gender data are collected and use these terms interchangeably or inconsistently. If sources do not differentiate gender from sex assigned at birth or organs present, the information is presumed to predominantly represent cisgender individuals. NCCN encourages researchers to collect more specific data in future studies and organizations to use more inclusive and accurate language in their future analyses.

Clinical Presentation, Workup, and Primary Treatment

Clinical Presentation

Testicular cancer most often presents as a painless or painful testicular nodule, mass, enlargement, or induration (hardening). Often, patients will present with testicular discomfort or swelling suggestive of epididymitis or orchitis. A trial of antibiotics is never warranted in the treatment of a mass suspicious for GCT but can be considered in patients with pain without a mass on further workup. Other patients may present with enlarged lymph nodes of the lower neck or upper chest (supraclavicular), a retroperitoneal mass, gynecomastia, venous thrombosis, or pulmonary embolism.

Workup

If testicular cancer is being considered as a possibility, then a transscrotal ultrasound with Doppler should be performed. Testicular ultrasound can confirm the presence of a testicular mass, determine whether a mass is intra- or extratesticular, and explore the contralateral testis.[18] Testicular GCTs are typically heterogeneous, hypoechoic, and vascular on ultrasound. If the ultrasound findings show a mass suspicious for malignancy, then a radical inguinal orchiectomy is generally performed to make a diagnosis. Testis-sparing surgery (TSS) (ie, partial orchiectomy) may be considered in select patients (See *Principles of Surgery for Germ Cell Tumors* in the algorithm). Unique clinical settings that warrant consideration for TSS include synchronous bilateral tumors, a solitary testicle with a mass suspicious for GCT, or a functionally solitary testicle with adequate gonadal function with respect to androgen production or sperm production (eg, history of contralateral testicular atrophy).[19-21] Transscrotal biopsies of the testes should not be performed because violating the scrotum increases the risk of local or atypical regional recurrence and can complicate management. In addition, a thorough history and physical examination should be performed. Serum tumor markers (alpha-fetoprotein [AFP], beta-human chorionic gonadotropin [beta-hCG], and lactate dehydrogenase [LDH]) also need to be assessed both before and after orchiectomy as they are used for prognosis and staging (see *Serum Tumor Markers* below).[15] Elevated levels of beta-hCG, LDH, or AFP should be followed up with repeated tests to allow for precise staging. Given the higher rates of hypogonadism in the testicular cancer population, measuring baseline levels of gonadal function can also be considered. It should be noted that in cases of advanced disease, systemic therapy may be initiated if there is an unequivocable diagnosis of GCT with marker elevation or after percutaneous biopsy of a metastatic site.

Discussion update in progress

Version 1.2026 © 2025 National Comprehensive Cancer Network© (NCCN©), All rights reserved. NCCN Guidelines® and this illustration may not be reproduced in any form without the express written permission of NCCN.

PLEASE NOTE that use of this NCCN Content is governed by the End-User License Agreement, and you MAY NOT distribute this Content or use it with any artificial intelligence model or tool.
Printed by Máximo López Chenlo on 5/4/2026 6:31:34 PM. Copyright © 2026 National Comprehensive Cancer Network, Inc. All Rights Reserved.

Serum Tumor Markers

The serum tumor markers, LDH, AFP, and beta-hCG, are used to aid in determining stage as well as prognosis of testicular GCTs. AFP and beta-hCG are also used for assessing treatment outcomes. For risk stratification in patients with metastatic disease, levels of AFP, beta-hCG, and LDH should all be measured on Day 1 of cycle one of first-line chemotherapy. In addition, levels of AFP and beta-hCG should be determined before and after treatment and throughout the follow-up period. Elevated markers after orchiectomy may be the only indication of occult metastatic disease (ie, in patients with stage IS disease), and elevated marker levels are often the earliest sign of relapse after treatment or during surveillance. LDH is not generally used to monitor for relapse or response to treatment because false-positive elevations are common, but it is useful for risk stratification when starting first-line chemotherapy. When interpreting marker levels, caution should be taken when mild elevation of only one marker is observed due to the occurrence of false positives.

AFP is most associated with yolk sac tumors but can also be elevated in patients with embryonal carcinoma or teratoma. Seminomas do not produce AFP; thus, an elevated serum AFP can be diagnostic of a mixed GCT (nonseminoma) in patients whose histology has been read as pure seminoma.[22-25] Therefore, the diagnosis of a seminoma is restricted to pure seminoma histology and normal serum AFP levels. However, mildly elevated, non-rising levels of AFP do not always indicate the presence of a GCT as a small number of people have a chronically elevated serum AFP level and clinicians should be cautious in interpreting mildly elevated but stable AFP.[26] In general, AFP levels <20 ng/mL should not be assumed to be related to a GCT in a patient and should not be the sole basis for decisions about treatment. If an elevated serum AFP is due to a metastatic nonseminomatous GCT, then the AFP typically will be steadily rising. In addition, other tumors, such as hepatocellular carcinomas and gastric carcinomas, can cause AFP elevation.

Beta-hCG is the most commonly elevated serum tumor marker in testicular cancer. Elevated serum concentrations of beta-hCG may be present with both seminomatous and nonseminomatous tumors. However, in patients with seminoma with beta-hCG levels >1000 IU/L, the possibility of nonseminoma should be considered and the surgical specimen with pathology should be re-reviewed. Referral to a high-volume center experienced in the treatment of these patients is encouraged. Additionally, patients with post-orchiectomy beta-hCG levels >5000 IU/L should receive a brain MRI since they are at an increased risk of having brain metastases. Further workup should be considered before initiating treatment for mildly elevated beta-hCG (generally <20 IU/L), since other factors such as hypogonadism, hyperthyroidism, and cannabis use can cause elevations of beta-hCG.[27-29] Intramuscular injection of 300 mg of testosterone cypionate may be administered in cases of mild beta-hCG elevations of unclear etiology to exclude hypogonadism as a cause. Elevated beta-hCG has also been reported in other tumors, such as lymphoma, bladder cancer, and adenocarcinomas, and is thus not specific for GCTs.[30] Additionally, heterophile antibodies have been reported to result in substantially elevated false-positive beta-hCG results (>400 IU/L); therefore, clinicians should consider repeating the test using a different assay if a false positive is suspected due to the absence of radiographic evidence of disease.[31-33]

LDH is important for determining prognosis and is used to help risk stratify patients starting first-line chemotherapy for disseminated nonseminomatous tumors.[24] There are also data indicating that in patients receiving chemotherapy for stage II or III seminoma, an elevation of LDH >2.5 times the upper limit of normal (ULN) is an adverse prognostic sign in patients with otherwise good-risk disease.[34] While serum LDH concentrations are elevated in approximately 50% of patients with

Discussion update in progress

Version 1.2026 © 2025 National Comprehensive Cancer Network© (NCCN©), All rights reserved. NCCN Guidelines® and this illustration may not be reproduced in any form without the express written permission of NCCN.

PLEASE NOTE that use of this NCCN Content is governed by the End-User License Agreement, and you MAY NOT distribute this Content or use it with any artificial intelligence model or tool.
Printed by Máximo López Chenlo on 5/4/2026 6:31:34 PM. Copyright © 2026 National Comprehensive Cancer Network, Inc. All Rights Reserved.

advanced testicular cancer, LDH is a less specific marker for testicular cancer compared to AFP and beta-hCG. Therefore, decisions regarding treatment should not be made based on mildly elevated (<2.5 times the ULN) LDH alone.

Primary Treatment

Radical inguinal orchiectomy is the primary treatment for most patients who present with a testicular mass that is suspicious for malignancy on ultrasound.[35] A CT scan of the abdomen/pelvis with contrast or MRI with and without contrast should be considered prior to orchiectomy if they can be done without delaying surgery as postoperative changes can occasionally complicate the interpretation of scans completed after orchiectomy. However, this is a minor concern and should not lead clinicians to delay orchiectomy. Concurrent insertion of testicular prosthesis may be considered during radical inguinal orchiectomy if desired by the patient.[36-38] In cases where the ultrasound shows an ambiguous abnormality that is inconclusive for malignancy, an open inguinal biopsy (TSS or partial orchiectomy) with intraoperative frozen section analysis can be performed, but such cases are extremely rare.[39] Additionally, inguinal exploration of the contralateral testis with direct observation and partial orchiectomy can be considered if a patient has bilateral testicular abnormalities or if the testis is cryptorchid or shows marked atrophy.[40] However, biopsies are not recommended for testicular microcalcifications alone.

Sperm banking should be discussed with patients of reproductive age, if clinically indicated, before undergoing any therapeutic intervention that may compromise fertility, including surgery, radiation therapy (RT), chemotherapy, or retroperitoneal lymph node dissection (RPLND).[41-44] If sperm banking is desired, it should be performed before orchiectomy in patients with a single testicle, those undergoing bilateral orchiectomy, and those with risk factors for infertility (atrophic contralateral testicle, history of infertility).

Further disease management is dictated by histology, stage, and whether the cancer is a pure seminoma or a nonseminoma (nonseminomas include mixed GCTs that are partially comprised of seminoma and tumors that are histopathologically described as pure seminomas in patients with persistently elevated serum AFP). Although rare, when a patient presents with: 1) markedly elevated beta-hCG or AFP levels; 2) a testicular mass and/or disease distribution typical for a testicular, retroperitoneal, or mediastinal GCT; and 3) a clinical scenario where, due to the bulk, signs, or symptoms of disease, the risk of delaying systemic therapy outweighs the benefit of a tissue diagnosis, chemotherapy may be initiated immediately without waiting for a biopsy diagnosis or performing orchiectomy. Orchiectomy should be performed after completion of chemotherapy, oftentimes at the time of RPLND or other adjunctive surgical procedures.

Staging

Staging of testicular GCTs is based on determination of the extent of disease and assessment of post-orchiectomy levels of serum tumor markers.[15] The tumor (T), node (N), and metastasis (M) staging system used by the AJCC is the internationally accepted standard for cancer staging and is a major factor influencing prognosis and treatment decisions. The AJCC TNM staging system incorporates serum tumor marker elevation as a distinct category (S), which is unique to this organ site. The extent of the primary tumor is classified after orchiectomy; therefore, pathologic (p) staging is assigned to the primary tumor (T).

The 8th edition of the AJCC Cancer Staging Manual introduced invasion of the epididymis and hilar soft tissue as new pathologic criteria used for T classification of stage I testicular GCTs.[15,45] Due to the excellent clinical outcomes seen in testicular cancer, large-scale follow-up studies have historically used tumor relapse rather than tumor-specific survival to validate the relevance of pathologic parameters used for staging.[15]

Discussion update in progress

Version 1.2026 © 2025 National Comprehensive Cancer Network© (NCCN©), All rights reserved. NCCN Guidelines® and this illustration may not be reproduced in any form without the express written permission of NCCN.

PLEASE NOTE that use of this NCCN Content is governed by the End-User License Agreement, and you MAY NOT distribute this Content or use it with any artificial intelligence model or tool.
Printed by Máximo López Chenlo on 5/4/2026 6:31:34 PM. Copyright © 2026 National Comprehensive Cancer Network, Inc. All Rights Reserved.

However, the association of hilar soft tissue and epididymal invasion with relapse of stage I disease has not been validated. Current data only support their association with having advanced-stage disease at the time of diagnosis.[46,47] Therefore, it is the opinion of the Panel that these factors should not be used for clinical decision-making in the treatment of these patients. Instead, the NCCN Guidelines for Testicular Cancer recommend treating patients with stage I nonseminoma based on the presence or absence of lymphovascular invasion (LVI), invasion of the spermatic cord, or invasion of the scrotum, which are risk factors known to be associated with an increased risk of relapse.[48-57] Predominance of embryonal carcinoma has also been proposed as a prognostic indicator of relapse in stage I nonseminoma, with several studies showing that a high proportion of embryonal carcinoma in the primary tumor (>50%) is associated with an increased risk of relapse.[50,58-65] However, very few patients have a high volume of embryonal carcinoma without also having LVI, and the value of embryonal carcinoma predominance in predicting relapse in the absence of LVI is unclear.[50,58,61,65] Therefore, predominance of embryonal carcinoma is not used by the NCCN Guidelines for Testicular Cancer to risk stratify patients with stage I nonseminoma. Patients with stage I nonseminoma with a high volume of embryonal carcinoma and no evidence of LVI are neither high risk nor low risk and could be considered for adjuvant therapy. The NCCN Guidelines do not recommend risk-adapted treatment for stage I pure seminoma.

The 8th edition of the AJCC Cancer Staging Manual also introduced changes to pathologic staging based on the type of spermatic cord involvement. Currently, continuous involvement of the spermatic cord soft tissue by the primary tumor is staged as pT3, whereas discontinuous spermatic cord involvement by invasion of lymphovascular spaces is now considered as a metastatic deposit (pM1).[15] This significant change results in patients with discontinuous spermatic cord involvement being upstaged from high risk stage I to stage III disease independent of radiologic or serologic assessment, which the Panel is concerned may lead to overtreatment. The evidence used to support this change is unclear; presently, there are no persuasive data showing differences in clinical outcomes between patients with discontinuous spermatic cord involvment compared to patients with continuous involvement. A recent retrospective analysis assessing the impact of different patterns of spermatic cord involvement on clinical stage and patient outcomes found no significant differences in either clinical stage at presentation or risk of recurrence based on the type of spermatic cord involvement (continuous vs. discontinuous).[66] Therefore, for management decisions, the Panel recommends staging GCTs with discontinuous invasion of the spermatic cord as pT3 (high-risk stage I) and not as pM1 (stage III) as is recommended by the AJCC. If surveillance is elected as primary treatment for such patients, clinicians should remember that there is a higher risk of pelvis relapses in these patients.

To assess for metastatic disease, imaging studies of the chest, abdomen, and pelvis should be performed. Such studies typically include CT scans of the abdomen and pelvis and CT scan or x-ray of the chest. Fluorodeoxyglucose (FDG)-PET scans should not be used to stage testicular GCTs. In select patients, brain MRI should also be performed; these patients include those with neurologic symptoms, post-orchiectomy serum beta-hCG >5000 IU/L, non-pulmonary visceral metastases, or extensive lung metastases. In patients who had elevated serum tumor markers prior to orchiectomy, it is important to obtain the half-life kinetics of the tumor markers after orchiectomy if the markers are declining, because a slower-than-expected decline often indicates the presence of metastatic disease.

In 2016, the World Health Organization (WHO) tumor classification scheme was significantly modified to contain new entities for GCTs.[67] Major changes include a pathogenetically derived classification using germ cell neoplasia in situ (GCNIS) of the testis as the new WHO-

Discussion update in progress

Version 1.2026 © 2025 National Comprehensive Cancer Network© (NCCN©), All rights reserved. NCCN Guidelines® and this illustration may not be reproduced in any form without the express written permission of NCCN.

PLEASE NOTE that use of this NCCN Content is governed by the End-User License Agreement, and you MAY NOT distribute this Content or use it with any artificial intelligence model or tool.
Printed by Máximo López Chenlo on 5/4/2026 6:31:34 PM. Copyright © 2026 National Comprehensive Cancer Network, Inc. All Rights Reserved.

recommended term for precursor lesions of invasive GCTs, and the distinction between testicular GCTs derived from GCNIS (postpubertal) and those unrelated to GCNIS (prepubertal).[67,68] Additionally, spermatocytic seminoma has been renamed as spermatocytic tumor, to avoid potential confusion with the unrelated usual seminoma. Presently, reporting of anaplasia (seminoma or spermatocytic tumor) or distinguishing mature from immature teratoma is not required, since these do not have demonstrable prognostic importance. Conversely, the presence of somatic-type malignancy arising in teratomas indicates more aggressive behavior and should therefore be reported.

Risk Classification for Advanced Disease

In 1997, the International Germ Cell Cancer Consensus Group (IGCCCG) defined a classification system based on identification of clinically independent prognostic features such as extent of disease and post-orchiectomy levels of serum tumor markers. This classification system categorizes patients with testicular GCTs into good-, intermediate-, or poor-risk groups.[69] When determining a patient's risk classification, the relevant serum tumor marker value is the value on Day 1 of cycle one of first-line chemotherapy. Definitions of stage and risk classification in these guidelines are done according to the IGCCCG classifications.

The IGCCCG classification system plays a pivotal role in the management of metastatic GCTs but relies on old data of patients treated between 1975 and 1990. The IGCCCG Update Model, published in 2021, included data from 9728 males with metastatic nonseminomatous GCTs treated with etoposide and cisplatin (EP)-based first-line chemotherapy between 1990 and 2013 at institutions in Europe, North America, and Australia.[70] Compared with the original IGCCCG publication, 5-year progression-free survival (PFS) remained similar in patients with good or intermediate risk (89% vs. 90% and 75% vs. 78%, respectively), but the 5-year overall survival (OS) increased from 92% to 96% in patients with good risk and from 80% to 89% in patients with intermediate risk. In patients with poor risk, the 5-year PFS increased from 41% to 54% and the OS from 48% to 67%. Furthermore, a novel prognostic model for PFS was developed in 3543 patients and validated in an independent dataset. This more granular prognostic model identified a new cutoff of LDH at 2.5 times the ULN, increasing age, and presence of lung metastases as additional adverse prognostic factors. An online calculator is provided (https://www.eortc.org/IGCCCG-Update). It should be noted that patients with good risk disseminated seminoma with an LDH >2.5 times the ULN have a worse prognosis than other patients with good risk. However, currently there are insufficient data to recommend treating these patients differently based on LDH level (see discussion below).

Pure Seminoma

If a pure seminoma is detected, an abdomen/pelvis CT scan with contrast or MRI with and without contrast should be performed unless performed prior to orchiectomy to assess the retroperitoneal lymph nodes. A chest x-ray is also recommended. A chest CT is indicated if the abdomen/pelvis CT/MRI or the chest x-ray shows evidence of metastatic disease. Measurement of beta-hCG, LDH, and AFP levels should be repeated since TNM staging is based on post-orchiectomy levels. For patients with elevated pre-orchiectomy beta-hCG levels, beta-hCG levels should be followed with repeated determinations after orchiectomy to determine their trajectory and, if declining, their nadir. The expected half-life for beta-hCG is ≤3 days. Beta-hCG and LDH may be elevated in patients with seminoma. Mild to moderate elevations of beta-hCG (S1) are not used to risk stratify pure seminomas, but a level of 5000 IU/L, which is the cutoff for S2, is not generally thought to be compatible with a pure seminoma. Therefore, patients with a histopathologic diagnosis of pure seminoma and a beta-hCG of ≥5000 would be treated as an intermediate- or poor-risk nonseminoma, depending on the extent of beta-hCG levels. Whether an elevated LDH should be used to stage or risk stratify patients with pure

Discussion update in progress

Version 1.2026 © 2025 National Comprehensive Cancer Network© (NCCN©), All rights reserved. NCCN Guidelines® and this illustration may not be reproduced in any form without the express written permission of NCCN.

PLEASE NOTE that use of this NCCN Content is governed by the End-User License Agreement, and you MAY NOT distribute this Content or use it with any artificial intelligence model or tool.
Printed by Máximo López Chenlo on 5/4/2026 6:31:34 PM. Copyright © 2026 National Comprehensive Cancer Network, Inc. All Rights Reserved.

seminoma is controversial and practice patterns vary. For patients with otherwise good-risk disseminated seminoma (stage II–III), an LDH >2.5 times the ULN is associated with a worse prognosis, but there is no consensus as to whether treatment for such patients should therefore be intensified.[37] Some Panel members advocate treating them as other patients with good risk while others advocate a more aggressive approach (such as three cycles of bleomycin, etoposide, and cisplatin [BEP] plus a fourth cycle using EP).

For patients with normal imaging (ie, stage I), rising or persistently elevated beta-hCG levels generally indicate the presence of metastatic disease (stage IS). Beta-hCG levels >1000 IU/L post-orchiectomy may indicate the presence of nonseminomatous tumor elements. An elevated AFP pre- or post-orchiectomy indicates the presence of nonseminomatous elements unless another cause of the elevated AFP (such as liver disease) is identified. It should be noted that if mild elevations in AFP are observed that are stable, patients can be treated as seminoma as this typically does not connote nonseminoma. Patients with seminoma arising from an extragonadal site, like the mediastinum, are usually diagnosed via biopsy and treated with standard chemotherapy regimens (EP for 4 cycles or BEP for 3 cycles) according to risk classification. Brain MRI is recommended if beta-hCG levels exceed 5000 IU/L (as noted above, a beta-hCG >1000 IU/L is rare in seminoma and a value >5000 IU/L is generally indicative of a nonseminomatous GCT), if there is extensive metastatic disease in the lungs, or if non-pulmonary visceral metastases or neurologic symptoms are present. Sperm banking should be recommended, if clinically indicated, to patients who will be undergoing chemotherapy, RT, or RPLND if they wish to preserve fertility.

Pure Seminoma Stages IA and IB

Primary Treatment for Pure Seminoma Stages IA and IB

Since 80% to 85% of patients with stage I pure seminoma are cured by orchiectomy alone, the NCCN Panel strongly prefers surveillance for pT1–pT3 tumors as the standard post-orchiectomy treatment option for these patients due to the low risk of relapse, especially when considered in relation to the potential harms of adjuvant therapy. For patients who decline surveillance or for whom surveillance is not a reliably good option, the Panel recommends chemotherapy with one or two cycles of single-agent carboplatin (with imaging recommended within 4 weeks prior to initiation, even if scans have been performed previously), or RT (20 Gy preferred) as alternative options to decrease the risk of relapse in certain patients. Disease-specific survival for stage I disease approaches 100% irrespective of the management strategy used.[71]

Surveillance

Several studies evaluating surveillance for the management of stage I seminoma have been conducted.[72-77] The relapse rates seen in these studies have ranged from 15% to 20%, with most disease relapse detected in the infradiaphragmatic lymph nodes. The best established risk factor for relapse of pure seminoma is larger size of the primary tumor.[78] As the tumor size increases, the risk of relapse also increases, but any cutoff point is arbitrary.[72,74,79-82] Although the 8th edition of the AJCC Cancer Staging Manual uses a cutoff point of 3 cm to subclassify stage IA pure seminoma into pT1a and pT1b, this small cutoff size was chosen in an effort to be conservative due to the large variability in size cutoffs reported in the literature.[15] Additionally, some studies have reported that rete testis invasion is an independent risk factor for relapse in stage I pure seminoma while others have reported that it is not.[72,74,78-80,83] Due to these concerns, the NCCN Panel discourages risk-adapted management in stage I pure seminoma and instead strongly recommends surveillance for

Discussion update in progress

Version 1.2026 © 2025 National Comprehensive Cancer Network© (NCCN©), All rights reserved. NCCN Guidelines® and this illustration may not be reproduced in any form without the express written permission of NCCN.

PLEASE NOTE that use of this NCCN Content is governed by the End-User License Agreement, and you MAY NOT distribute this Content or use it with any artificial intelligence model or tool.
Printed by Máximo López Chenlo on 5/4/2026 6:31:34 PM. Copyright © 2026 National Comprehensive Cancer Network, Inc. All Rights Reserved.

all patients who are able to adhere to the surveillance schedule. If surveillance is not applicable, alternative options are either adjuvant chemotherapy with single-agent carboplatin or adjuvant RT as described below. Each approach has distinct advantages and disadvantages that should be discussed with patients and their families to select the best individual treatment plan.

Adjuvant Chemotherapy

As noted, chemotherapy or RT are potential therapeutic options for those patients with stage I seminoma for whom surveillance is not a suitable option. Oliver et al reported the initial results of a trial that randomized 1477 patients with stage I seminoma to receive either RT (n = 885) or one cycle of intravenous carboplatin (n = 560) at the dose area under the curve (AUC) x 7 (ie, based on the formula 7 x [glomerular filtration rate (GFR, mL/min) + 25 mg]).[84] At a follow-up of 3 years, the relapse-free survival rates for both groups were similar (95.9% for the RT group and 94.8% for the carboplatin group), which established the noninferiority of carboplatin compared to RT.[84] The mature results of this trial confirmed the noninferiority of single-dose carboplatin versus RT in terms of relapse-free survival.[85] In an intent-to-treat analysis, the relapse-free survival rates at 5 years were 96% in the RT arm and 94.7% in the carboplatin arm (hazard ratio [HR], 1.25; P = .37). One seminoma-related death occurred after RT and none occurred after carboplatin. Additionally, patients given carboplatin were less lethargic and less likely to take time off from work than patients receiving RT. Therefore, the authors concluded that a single dose of carboplatin is less toxic and as effective in preventing disease relapse as adjuvant RT in patients with stage I pure seminoma after orchiectomy.[85] However, it should be noted that there are limited long-term follow-up data regarding the toxicity and efficacy of carboplatin.[72,86] Moreover, a non-randomized population-based study of 897 patients with stage I seminoma suggested that patients with tumor size >4 cm, rete testis invasion, or both derive a smaller reduction in relapse rate with one cycle of carboplatin than previously reported.[72,74,86] After a median follow-up of 5.6 years, the relapse rate in patients with one or both risk factors was 15.5% for patients treated with surveillance versus 9.3% for patients who received one cycle of carboplatin.[72] Given the toxicity, an absolute reduction in the risk of relapse by only 6.2% may not be sufficient to justify the use of single-cycle adjuvant carboplatin.[86] Platinum-based chemotherapy has also been associated with cardiac toxicity and an increased risk for secondary cancers as well as a 23% higher risk of death from causes other than testis cancer.[87-90] However, most of the data on late effects of platinum-based chemotherapy in survivors of testis cancer is derived from those receiving multi-agent cisplatin-based chemotherapy; thus, whether such long-term risks ensue from single-agent carboplatin as dosed for stage I seminoma remains unknown. Therefore, more data are needed to assess the value of one cycle of carboplatin in treating patients with stage I seminoma.

Use of two cycles of adjuvant carboplatin in this setting has also been studied. The Spanish Germ Cell Cancer Cooperative Group reported that among 412 males treated with two cycles of adjuvant carboplatin for high-risk stage I seminoma, the 10-year relapse-free survival rate was 97% and 10-year OS was 100%.[91-93] The efficacy of two cycles of adjuvant carboplatin was confirmed in a study by the Hellenic Cooperative Oncology Group, which reported a 5-year relapse-free survival rate of 96.8% among 138 patients with stage I seminoma treated with this regimen.[94] Additionally, a prospective study reported the treatment outcomes of 725 patients with stage I seminoma treated with surveillance, one cycle of carboplatin, or two cycles of carboplatin.[95] Although disease-specific survival was 100% for all three strategies, crude relapse rates were significantly higher with the one-cycle regimen (5%) compared to the two-cycle regimen (1.5%) after a median follow-up of 30 months. Furthermore, one cycle of carboplatin demonstrated low efficacy to control large tumors. In the absence of randomized data comparing one versus

Discussion update in progress

Version 1.2026 © 2025 National Comprehensive Cancer Network© (NCCN©), All rights reserved. NCCN Guidelines® and this illustration may not be reproduced in any form without the express written permission of NCCN.

PLEASE NOTE that use of this NCCN Content is governed by the End-User License Agreement, and you MAY NOT distribute this Content or use it with any artificial intelligence model or tool.
Printed by Máximo López Chenlo on 5/4/2026 6:31:34 PM. Copyright © 2026 National Comprehensive Cancer Network, Inc. All Rights Reserved.

two doses of carboplatin, as well as the lack of long-term data, the Panel does not recommend one dose over the other. Regardless of the regimen used, imaging is recommended within 4 weeks prior to the initiation of chemotherapy to confirm staging, even if scans were previously performed.

Adjuvant Radiation Therapy

Numerous studies have found an increased risk for late toxicities in patients with seminoma treated with RT, including development of secondary malignancies and an increased risk of death from causes other than testis cancer.[90,96,97] A population-based study of over 5700 survivors of testis cancer, including 1500 treated with RT, reported that RT for stage I seminoma was associated with a 28% increase in the risk of death from non-testis cancer-related causes.[90] The increased risk of death was seen specifically for secondary malignancies and diseases of the digestive system. However, most of these patients were treated with larger treatment fields and higher radiation doses than currently recommended for stage I seminoma. Another population-based study reported that RT for stage I seminoma was associated with an 80% increase in the risk of death from secondary cancers.[98] Similarly, it has been reported that moderate-dose infradiaphragmatic RT for stage I seminoma was associated with an increased risk for secondary cancers in organs within the radiation field.[99] Another multicenter cohort study also reached similar conclusions.[89] Additionally, one study reported that RT might increase the risk of a subsequent cardiac event,[87] but other analyses have not confirmed this risk.[98]

Nodal mapping studies suggest that treatment fields for RT should target the retroperitoneal lymph nodes but not necessarily the ipsilateral renal hilar nodes.[100,101] Special circumstances, such as ipsilateral pelvis surgery, may alter the lymphatic drainage of the testis. Therefore, irradiation of the ipsilateral iliac and inguinal lymph nodes has been advocated in such patients.[100,102,103] It should be noted that patients treated with para-aortic RT have a slightly higher rate of pelvis relapse compared with those treated with “dog-leg” RT.[103-106] Prophylaxis to the mediastinum is not provided, because relapse rarely occurs at this site and mediastinal radiotherapy introduces additional toxicities and late effects.

The NCCN Panel prefers surveillance to the routine use of adjuvant therapy for patients with stage I seminoma because the risk of relapse is low when considered in relation to the potential harms of adjuvant therapy. However, if adjuvant RT is delivered, the Panel recommends a total dose of 20 Gy be administered in 10 fractions of 2.0 Gy each.[107] Alternatively, a total dose of 25.5 Gy can be given in 17 fractions of 1.5 Gy each.[108] Other RT dose schedules are listed in Table 1 in *Principles of Radiotherapy for Pure Testicular Seminoma* in the algorithm. Patients at higher risk for morbidity from RT, such as those with a history of inflammatory bowel disease or prior RT, are generally not given primary RT.

Follow-up for Pure Seminoma Stages IA and IB After Primary Treatment

Although no single follow-up plan is applicable to all patients, the NCCN Panel has provided guidance for the follow-up of patients with testicular GCTs for the first 5 years after the completion of therapy. These recommendations may be individualized and extended beyond 5 years at the discretion of the physician. Follow-up strategies for patients with stage I seminoma vary according to the treatment modality received by the patient (surveillance vs. adjuvant treatment). An analysis of >5000 patients with stage I seminoma from various trials reported that the 5-year relapse rate was higher with surveillance (18.6%) compared to RT (4.8% with extended-field RT and 3.6% with para-aortic RT) or chemotherapy (6.1% with one cycle of carboplatin and 2.3% with two cycles of carboplatin).[105] An analysis of data from the Danish Testicular Cancer database reached similar conclusions, reporting that the 10-year cumulative incidence of disease recurrence was 32% for patients with high-risk (tumor size ≥6 cm)

Discussion update in progress

Version 1.2026 © 2025 National Comprehensive Cancer Network© (NCCN©), All rights reserved. NCCN Guidelines® and this illustration may not be reproduced in any form without the express written permission of NCCN.

PLEASE NOTE that use of this NCCN Content is governed by the End-User License Agreement, and you MAY NOT distribute this Content or use it with any artificial intelligence model or tool.
Printed by Máximo López Chenlo on 5/4/2026 6:31:34 PM. Copyright © 2026 National Comprehensive Cancer Network, Inc. All Rights Reserved.

stage I seminoma given surveillance versus 2.8% for those given adjuvant RT.[109] An analysis of data from the National Cancer Database examined the survival outcomes of 33,094 patients with stage I seminoma who received surveillance, chemotherapy, or RT as primary treatment after orchiectomy.[110] Although OS was high for all strategies, results showed a small absolute survival advantage for adjuvant therapy (RT or chemotherapy) over surveillance at 10 years (95% vs. 93.4%; HR, 0.58; $P < .0005$). However, in this study, surveillance was defined as not having undergone radiation or chemotherapy, meaning that no distinction was made between patients who underwent surveillance and patients who never followed up. Thus, patients for whom active treatment was recommended but who never came in for treatment would have been considered to have undergone surveillance even if they never had any surveillance visits or tests. Independent of the treatment modality received by the patient, the risk of relapse is highest in the first 2 years following treatment.[105] In the event of relapse, clinicians should keep in mind the potential for development of a second primary tumor in the contralateral testis. Reassessment of disease activity should be performed in patients with new or worsening signs or symptoms of disease, and patients experiencing relapse should be treated according to the extent of the disease. However, patients should not be treated based upon an elevated LDH alone for reasons discussed previously. Additionally, those previously on surveillance can be treated with RT or chemotherapy, depending on extent of disease, and those who previously received carboplatin or RT can be treated with first-line cisplatin-based chemotherapy (see *First-Line Chemotherapy Regimens for Germ Cell Tumors* in the algorithm).

Follow-up During Surveillance

Follow-up for patients with stage I seminoma treated with surveillance after orchiectomy is outlined in Table 1 on TEST-A 1 of 3 in the algorithm and includes a history and physical examination with optional measurement of serum tumor markers. The measurement of serum tumor markers is optional due to the rarity of marker-only relapse, since most patients with elevated markers will also have evidence of relapse on imaging. Additionally, in one of the largest prospectively maintained databases of patients with stage I seminoma treated with surveillance, it was reported that routine measurement of serum tumor markers did not aid in the early diagnosis of relapse.[111] Therefore, routine measurement of serum tumor markers can be safely omitted from stage I seminoma surveillance schedules.

There is controversy regarding how many imaging studies should be performed in patients on surveillance. A phase III clinical trial in the United Kingdom entitled TRISST (MRC TE24/Trial of Imaging and Schedule in Seminoma Testis) investigated whether MRI or a reduced CT schedule could be used as a safe and effective alternative to standard CT-based surveillance in the management of stage I seminoma.[112] The trial randomized 669 patients with stage I seminoma post-orchiectomy to receive 7 CTs, 7 MRIs, 3 CTs, or 3 MRIs at selected intervals. After a median follow-up of 72 months, 12% of patients had relapsed. In all groups, most relapses were detected at scheduled imaging with very few occurring beyond 3 years. Relapse treatment outcomes were good, with 81% of patients experiencing a complete response with no tumor-related deaths. Five-year disease-free survival (DFS) and OS were also similar across groups, suggesting non-inferiority of MRI or reduced CT schedule to standard CT schedule for surveillance of patients with stage I seminoma. Thus, MRI is an appropriate option that can be considered to replace abdomen/pelvis CT. The MRI protocol should include visualization of all the nodes that need to be assessed, including retroperitoneal and pelvis nodes.

Several studies have suggested that relapses in the lung are rarely detected by chest x-ray alone in patients with stage I seminoma treated with surveillance.[113-115] In a recent retrospective analysis of 886 patients with stage I seminoma, 83 patients experienced relapse.[114] All relapses

Discussion update in progress

Version 1.2026 © 2025 National Comprehensive Cancer Network© (NCCN©), All rights reserved. NCCN Guidelines® and this illustration may not be reproduced in any form without the express written permission of NCCN.

PLEASE NOTE that use of this NCCN Content is governed by the End-User License Agreement, and you MAY NOT distribute this Content or use it with any artificial intelligence model or tool.
Printed by Máximo López Chenlo on 5/4/2026 6:31:34 PM. Copyright © 2026 National Comprehensive Cancer Network, Inc. All Rights Reserved.

were detected by either rising tumor markers and/or follow-up CT scan; not a single relapse was detected by routine chest x-ray alone. Other studies have reported similar results, calling into question the value of chest x-rays in surveillance settings for stage I seminomatous GCTs.[113,115] Therefore, routine chest imaging, including chest x-ray and chest CT with contrast, should be reserved for patients with thoracic symptoms.

Follow-up After Adjuvant Treatment

Follow-up of patients treated with adjuvant therapy (chemotherapy or RT) is outlined in Table 2 on TEST-A 1 of 3 in the algorithm and includes a history and physical examination with testicular ultrasound performed for any equivocal exam, with optional measurement of post-orchiectomy serum tumor markers. A meta-analysis of 2466 patients reported that relapse rarely occurred >3 years after treatment with RT or carboplatin (0.2% of patients).[71] Since the rate of relapse beyond 3 years is very low for patients treated with chemotherapy or RT, the NCCN Panel recommends performing an abdomen/pelvis CT scan or MRI with or without contrast annually for the first 3 years only. The MRI protocol should include visualization of the retroperitoneal and pelvis nodes. Chest x-rays should be obtained only when clinically indicated, and chest CT scans with contrast should be considered for patients who are symptomatic. CT is not recommended beyond 5 years, unless clinically indicated. Relapses are treated according to the stage at relapse.[71] However, patients should not be treated based on an elevated LDH level alone.

Pure Seminoma Stage IS

Primary Treatment for Pure Seminoma Stage IS

Stage IS pure seminoma is very uncommon and requires persistent elevation of serum tumor markers following orchiectomy in the absence of radiologic evidence of metastatic disease. Elevated tumor markers increase the risk of disease outside the retroperitoneum; therefore, systemic therapy should be encouraged (see *First-Line Chemotherapy Regimens for Germ Cell Tumors* in the algorithm). However, physicians are cautioned against treating a patient based on mildly elevated LDH or beta-hCG alone, as other causes may be responsible for elevation of these markers. Persistent and progressive elevation of serum markers, notably beta-hCG, is usually evidence of metastatic disease, which will show up radiographically if doubt exists in the diagnosis.

Follow-up for Pure Seminoma Stage IS

The NCCN Panel recommends repeating measurements of serum tumor markers and performing imaging studies (chest/abdomen/pelvis CT with contrast or MRI with and without contrast) to scan for evaluable disease.

Pure Seminoma Stages IIA and IIB

Primary Treatment for Pure Seminoma Stages IIA and IIB

Stage IIA pure seminoma is defined as metastatic disease to lymph nodes, with a lymph node mass measuring ≤2 cm in greatest diameter.[15] A lymph node mass measuring 2 to 5 cm in greatest diameter is classified as stage IIB disease.[15] Clinically, patients are often categorized as having “non-bulky” clinical stage II disease (largest node <3 cm on the transaxial long axis) or “bulky” clinical stage II disease (largest node >3 cm on the transaxial long axis). Providers should engage in shared decision-making for stage IIA seminoma that includes informing patients of the recurrence rates and potential for dual therapy with each treatment option. Moreover, to confirm staging before initiating treatment in select cases of stage IIA disease with borderline retroperitoneal lymph nodes, waiting 4 to 8 weeks after initial imaging assessment and repeating imaging (CT or MRI) may be considered.

Options for the primary treatment of stage IIA and IIB seminomas are based on lymph node mass measurements with the options for non-bulky clinical stage II disease being RT first-line chemotherapy with three cycles

Discussion update in progress

Version 1.2026 © 2025 National Comprehensive Cancer Network© (NCCN©), All rights reserved. NCCN Guidelines® and this illustration may not be reproduced in any form without the express written permission of NCCN.

PLEASE NOTE that use of this NCCN Content is governed by the End-User License Agreement, and you MAY NOT distribute this Content or use it with any artificial intelligence model or tool.
Printed by Máximo López Chenlo on 5/4/2026 6:31:34 PM. Copyright © 2026 National Comprehensive Cancer Network, Inc. All Rights Reserved.

of BEP or four cycles of EP, carboplatin plus RT, or nerve-sparing RPLND.[116-118] If disease is between 3 to 5 cm, then first-line chemotherapy should be given with both EP and BEP being preferred regimens in this setting. However, a bleomycin-free regimen should be considered in patients at risk for bleomycin-related toxicity, such as those with reduced GFR or older age (age >50). The presence of chronic obstructive pulmonary disease (COPD) or other lung disease resulting in reduced pulmonary function are also risk factors for bleomycin-related toxicity. Different studies have reported different outcomes with regard to whether chemotherapy or RT is more effective in this setting. A study that used data from the National Cancer Database to assess survival outcomes according to treatment strategy in patients with stage IIA/B seminoma showed that when RT was compared with multi-agent chemotherapy in 1772 patients with stage IIA–C seminoma treated with orchiectomy, 5-year OS was significantly higher with RT compared to chemotherapy in patients with stage IIA seminoma (99% vs. 93%; HR, 0.28; 95% CI, 0.09–0.86; P = .027) after a median follow-up of 65 months.[119] Conversely, in this study, no significant difference in 5-year OS was seen in patients with stage IIB seminoma treated with post-orchiectomy RT or chemotherapy (95.2% vs. 92.4%). A similar study by Paly et al, which also evaluated data from the same database during the same time period, reached similar conclusions with receipt of chemotherapy being associated with decreased 5-year OS in patients with stage IIA seminoma (HR, 13.33; P < .01), but not in patients with stage IIB seminoma (HR, 1.39; P = .45).[120] However, these studies were not randomized trials and treatment decisions were based on the treating physician's clinical judgment, which presumably was influenced by the specific characteristics of each patient. Therefore, it is possible that patients with more extensive disease were selected for chemotherapy. Nevertheless, these studies provide some support for the use of RT over chemotherapy to treat stage IIA seminoma. In contrast, a study by Mortensen et al evaluating 363 patients with stage II–III seminoma reported that the relapse rate was 6% among patients treated with chemotherapy compared to 12.6% among those treated with RT. It should be noted that chemotherapy was used for more advanced stage disease than RT in this study.[82] This has led some physicians to prefer chemotherapy for patients with stage II seminoma; however, these results must be interpreted with caution since this study was not a randomized trial and did not specifically compare the two treatment modalities for stage IIA disease. Therefore, the Panel recommends first-line chemotherapy as a primary treatment option for both stage IIA and IIB seminoma but suggests that RT should be reserved for select patients with non-bulky (<3 cm in transaxial long axis) disease.[116]

The target fields for RT for stage IIA/B disease should include the para-aortic and proximal ipsilateral iliac lymph nodes. Treatment is delivered in two consecutive anteroposterior-posteroanterior (AP/PA) phases with no break in between. The initial phase consists of treatment of modified dog-leg fields at a dose of 20 Gy delivered in 10 fractions of 2.0 Gy each or 25.5 Gy delivered in 17 fractions of 1.5 Gy each. The Panel prefers modified dog-leg fields as described by Classen et al.[116] The second phase (cone down) consists of daily 1.8- to 2-Gy fractions to a cumulative total dose of 30 Gy for patients with stage IIA seminoma and 36 Gy for patients with stage IIB seminoma.[116] Prophylactic mediastinal RT is not indicated for the management of stage II disease.[121] For details on field arrangement, see *Principles of Radiotherapy for Pure Testicular Seminoma* in the algorithm.

Although primary treatment with RT or first-line chemotherapy results in favorable survival outcomes, they bear the risks of acute and late toxic effects. Therefore, evaluation and development of alternative strategies is of interest in order to mitigate toxicity while maintaining efficacy. Prospective and retrospective studies have reported the use of primary RPLND in clinical stage II seminoma with curative intent and demonstrated that RPLND can cure many clinical stage II seminomas with a 2-year recurrence-free survival of 72% to 90%, allowing patients to avoid

Discussion update in progress

Version 1.2026 © 2025 National Comprehensive Cancer Network© (NCCN©), All rights reserved. NCCN Guidelines® and this illustration may not be reproduced in any form without the express written permission of NCCN.

PLEASE NOTE that use of this NCCN Content is governed by the End-User License Agreement, and you MAY NOT distribute this Content or use it with any artificial intelligence model or tool.
Printed by Máximo López Chenlo on 5/4/2026 6:31:34 PM. Copyright © 2026 National Comprehensive Cancer Network, Inc. All Rights Reserved.

chemotherapy and radiotherapy.[122-125] Due to these promising results, the Panel recommends RPLND as a treatment option for stage IIA disease and stage IIB non-bulky disease within 4 weeks of CT or MRI and within 2 weeks of confirmation of normal tumor markers. However, for stage IIB non-bulky disease (2–3 cm) this is a category 2B recommendation as some Panel members expressed concern regarding the potential for higher disease recurrence rates in these patients as compared to chemotherapy along with the limited number of patients with this extent of disease included in these trials. RPLND is not recommended for bulky (>3 cm) stage IIB disease due to very limited data for those patients and the higher relapse rates observed with increasing node size. Referral to a high-volume center with extensive experience in the performance of this procedure is recommended.

Furthermore, the recent single-arm phase II SAKK (01/10) trial investigated whether one cycle of single-agent carboplatin followed by involved-node RT was effective in treating patients with stage IIA or IIB seminoma (N = 116) with minimal toxicity.[126] After a median follow-up of 4.5 years, the 3-year PFS was 93.7%, which was short of the target 3-year PFS of 95%. Although the study did not meet its primary endpoint, survival was favorable and toxic effects were minimal with this treatment strategy. Grade 3–4 treatment-related adverse events included neutropenia, thrombocytopenia, and vomiting, which occurred in 4%, 3%, and 1% of patients, respectively. No treatment-related deaths and no late toxic effects were reported. Serious adverse events were reported in only 4% of patients. Based on the promising efficacy of the regimen presented in this trial, the Panel has added this regimen as an option for patients with involved lymph nodes measuring <3 cm. However, due to the lack of evaluation of late toxicities beyond 3 years, this is included as a category 2B option for this patient population.

Follow-up for Pure Seminoma Stages IIA and Non-bulky IIB After Radiotherapy, Chemotherapy, or Both

The recommended follow-up schedule for patients with stage IIA and non-bulky stage IIB seminoma after RT or chemotherapy, assuming no residual mass or residual mass <3 cm and normal tumor markers, is outlined in Table 3 on TEST-A 2 of 3 in the algorithm and includes a history and physical examination with optional measurement of post-orchiectomy serum tumor markers and imaging (abdomen/pelvis CT scan with contrast or MRI with and without contrast). The MRI protocol should include visualization of the retroperitoneal and pelvic nodes as well as all other nodes that need to be assessed. CT or MRI is not recommended beyond 5 years, unless clinically indicated. Chest x-ray is recommended and may be used for routine follow-up, but chest CT with contrast is preferred in the presence of thoracic symptoms.

Follow-up for Pure Seminoma Stage II Post-primary RPLND and NOT Treated with Adjuvant Chemotherapy

The recommended follow-up schedule for patients with stage IIA seminoma after RPLND not treated with adjuvant chemotherapy is outlined in Table 4 on TEST-A 2 of 3 in the algorithm and includes a history and physical examination with optional measurement of serum tumor markers as well as imaging with abdomen/pelvis CT scan with contrast or MRI with and without contrast. The MRI protocol should include visualization of the retroperitoneal and pelvis nodes as well as all other nodes that need to be assessed. CT or MRI are not recommended beyond 5 years unless clinically indicated. Chest x-ray may be used for routine follow-up, but a chest CT with contrast is preferred in the presence of thoracic symptoms.

Follow-up for Pure Seminoma Stage II After Primary RPLND and Adjuvant Chemotherapy

The recommended follow-up schedule for patients with stage II seminoma after primary RPLND and adjuvant chemotherapy treatment is outlined in

Discussion update in progress

Version 1.2026 © 2025 National Comprehensive Cancer Network© (NCCN©), All rights reserved. NCCN Guidelines® and this illustration may not be reproduced in any form without the express written permission of NCCN.

PLEASE NOTE that use of this NCCN Content is governed by the End-User License Agreement, and you MAY NOT distribute this Content or use it with any artificial intelligence model or tool.
Printed by Máximo López Chenlo on 5/4/2026 6:31:34 PM. Copyright © 2026 National Comprehensive Cancer Network, Inc. All Rights Reserved.

Table 5 on TEST-A 3 of 3 in the algorithm and includes a history and physical examination and optional tumor marker assessment. Abdomen/pelvis CT with contrast or MRI with and without contrast is recommended, and the MRI protocol should include all nodes that need to be assessed. CT or MRI are not recommended beyond 5 years, unless clinically indicated. Chest x-ray is recommended, and while chest x-ray may be used for routine follow-up, a chest CT with contrast is preferred in patients demonstrating thoracic symptoms.

Pure Seminoma Stages IIC and III

Primary Treatment for Pure Seminoma Stages IIC and III

Patients with stage IIC or stage III seminomas are classified as either good or intermediate risk. All stage IIC and stage III seminomas are considered good risk except for stage IIIC disease, which involves non-pulmonary visceral metastases (eg, bone, liver, brain) and is considered intermediate risk. Stage IIIB does not apply to pure seminomas. Standard first-line chemotherapy is used for both groups of patients.

For patients with good risk, three cycles of BEP or four cycles of EP are recommended (both preferred).[127-129] The two regimens have not been compared head-to-head in patients with seminoma, so the Panel recommends that a number of factors be considered in choosing between the two. The specific schedule of the two regimens is different (9 weeks for three cycles of BEP compared to 12 weeks for four cycles of EP), which may make one more convenient for certain patients. While etoposide and cisplatin are associated with a dose-dependent increased risk of secondary cancers, there are no data addressing whether the risk is significantly higher with four cycles than with three. Bleomycin, which is cleared by the kidneys, is associated with a risk of pneumonitis and diminished pulmonary function. Therefore, four cycles of EP are generally preferable in patients with a reduced GFR (who would be expected to clear bleomycin more slowly), in patients >50 years of age (since renal function decreases with age), and in patients with COPD or other lung disease resulting in significantly diminished pulmonary function. Some oncologists prefer four cycles of EP for patients who smoke heavily regardless of lung function. The different risks associated with each regimen may lead individual patients to prefer one regimen over the other. The physician and patient should make a shared decision informed by patient clinical characteristics and preferences. Intensification of therapy should be considered for patients with good risk disease and an LDH >2.5 times the ULN.

For patients with intermediate-risk disease, more intensive chemotherapy with four cycles of BEP (preferred) or four cycles of etoposide, mesna, ifosfamide, and cisplatin (VIP) is recommended.[130-135] VIP should be reserved for patients with a contraindication to bleomycin (ie, a reduced or borderline GFR, aged >50 years, COPD, or other lung disease), but it should be kept in mind that this regimen is high risk for febrile neutropenia and granulocyte colony-stimulating factors (G-CSFs) should be used (see the NCCN Guidelines for Hematopoietic Growth Factors at www.NCCN.org). All of these chemotherapy options are category 1 recommendations except for VIP, which is a category 2A recommendation.

Management of Pure Seminoma Stages IIA, IIB, IIC, and III After Chemotherapy

After primary treatment with first-line chemotherapy, patients with stage IIA, IIB, IIC, or III seminoma should be evaluated by CT scan with contrast or MRI with and without contrast of the chest, abdomen, and pelvis as well as measurement of serum tumor markers. Patients with normal serum AFP and beta-hCG levels and either no residual mass or a residual mass ≤3 cm should undergo surveillance. Surveillance is also recommended for patients with a residual mass >3 cm and normal serum AFP and beta-hCG levels. A FDG-PET/CT from skull base to mid-thigh can be considered to assess for the presence of viable residual tumor since CT alone cannot

Discussion update in progress

Version 1.2026 © 2025 National Comprehensive Cancer Network© (NCCN©), All rights reserved. NCCN Guidelines® and this illustration may not be reproduced in any form without the express written permission of NCCN.

PLEASE NOTE that use of this NCCN Content is governed by the End-User License Agreement, and you MAY NOT distribute this Content or use it with any artificial intelligence model or tool.
Printed by Máximo López Chenlo on 5/4/2026 6:31:34 PM. Copyright © 2026 National Comprehensive Cancer Network, Inc. All Rights Reserved.

discriminate between residual neoplastic lesions and necrotic or fibrotic tissue.[136-140] FDG-PET can provide useful metabolic information on these lesions, which may aid in the early detection of recurrent disease in patients with normal CT findings, since functional abnormalities usually precede morphologic ones.[140] However, testicular GCTs are typically slow-growing and have low uptake of FDG on PET scans, often resulting in unclear images of testicular lesions.[141] Additionally, the abdomen and retroperitoneal space are sites of non-specific FDG uptake, which can lead to false-positive results.[141] Possible sources of false-negative results include small malignant lesions (<3 cm) and lesions with low proliferative indices.[140] Therefore, accurate interpretation of FDG-PET scans is paramount and possible positive findings should not be based on FDG-PET positivity alone due to its relatively low positive predictive value in residual lesions after chemotherapy.[142] FDG-PET/CT is not indicated for residual masses ≤3 cm due to its low diagnostic accuracy in small tumors.[140] To reduce the incidence of false-positive results due to inflammation, the FDG-PET/CT scan should be performed at least 6 weeks after the completion of the last cycle of chemotherapy in patients with a residual mass >3 cm and normal serum tumor marker levels.[140,143] A negative FDG-PET/CT following chemotherapy is very reassuring. If the FDG-PET/CT is negative or indeterminate, surveillance is recommended. If results are positive, imaging can be repeated in 6 to 8 weeks or resection or interventional radiology (IR)-guided biopsy of the residual mass should be performed. If imaging was repeated and the results are persistently positive, proceeding with resection or biopsy is recommended. For patients with a positive FDG-PET/CT, referral to a high-volume center should also be considered.

If the residual disease is completely resected and histopathology shows viable seminoma, two cycles of adjuvant chemotherapy can be considered with the following regimens: EP, TIP (paclitaxel, ifosfamide, cisplatin),[144] VIP, or VeIP (vinblastine, mesna, ifosfamide, cisplatin).[145,146] If the resection is incomplete and the pathology shows viable seminoma, or if there is progressive disease (growing mass or rising markers), a full course of second-line chemotherapy (four cycles of TIP or four cycles of VeIP; both preferred) is recommended.[144-147] More information on second-line therapy can be found later in this discussion. In rare cases, nonseminomatous elements may be identified in the biopsy specimen. If these elements are non-teratomatous, then management should proceed in the same fashion as for viable seminoma. Following adjuvant or second-line chemotherapy, patients should undergo follow-up as discussed in the upcoming sections. Patients should also adhere to this follow-up schedule if their biopsy results are negative for viable seminoma.

Follow-up for Pure Seminoma Bulky Stage IIB, IIC, and Stage III After Chemotherapy

The recommended follow-up schedule for patients with bulky clinical stage IIB, IIC, or stage III seminoma after treatment with chemotherapy is outlined in Table 6 on TEST-A 3 of 3 in the algorithm and includes more frequent history and physical examination as well as optional measurement of serum tumor marker levels. Abdomen/pelvis CT scans with contrast or MRI with and without contrast are recommended, and the MRI protocol should include all nodes that need to be assessed. CT or MRI is not recommended beyond 5 years unless clinically indicated. Chest x-ray is recommended for routine follow-up; however, chest CT with contrast is preferred for patients with thoracic symptoms or residual masses or nodules in the chest. A chest CT with contrast should also be added in years 1 and 2 along with chest x-ray if supradiaphragmatic disease is present at diagnosis. Patients with residual masses may require more frequent imaging based on clinical judgment. An FDG-PET/CT scan of the skull base to mid-thigh can be conducted if clinically indicated. Since viable tumor cells have been found in tumors >3 cm with a negative post-chemotherapy FDG-PET scan,[148] the NCCN Panel recommends that patients with a residual mass measuring >3 cm and negative FDG-PET

Discussion update in progress

Version 1.2026 © 2025 National Comprehensive Cancer Network© (NCCN©), All rights reserved. NCCN Guidelines® and this illustration may not be reproduced in any form without the express written permission of NCCN.

PLEASE NOTE that use of this NCCN Content is governed by the End-User License Agreement, and you MAY NOT distribute this Content or use it with any artificial intelligence model or tool.
Printed by Máximo López Chenlo on 5/4/2026 6:31:34 PM. Copyright © 2026 National Comprehensive Cancer Network, Inc. All Rights Reserved.

results after chemotherapy should undergo an MRI with and without contrast or abdomen/pelvis CT scan with contrast every 6 months for the first year and then annually for 5 years.

Nonseminoma

Nonseminomatous GCTs include nonseminoma tumors, mixed seminoma/nonseminoma tumors, and seminoma tumors in patients with elevated and continually rising serum AFP levels. To assess for metastatic disease, a CT scan with contrast or MRI with and without contrast of the chest, abdomen, and pelvis should be performed unless performed prior to orchiectomy. Use of FDG-PET/CT scan is not clinically indicated for nonseminoma.[149,150] In select patients, brain MRI should also be performed; these patients include those with neurologic symptoms, post-orchiectomy serum beta-hCG >5000 IU/L or AFP >10,000 ng/mL, predominance of choriocarcinoma, non-pulmonary visceral metastasis, or extensive lung metastases. Elevated levels of serum beta-hCG, LDH, or AFP should be followed up with repeated tests as TNM staging is based on post-orchiectomy values. In patients who had elevated serum tumor markers prior to orchiectomy, it is important to obtain the half-life kinetics of the tumor markers after orchiectomy if the markers are declining, because a slower-than-expected decline often indicates the presence of metastatic disease. The NCCN Panel emphasizes that mildly elevated, non-rising AFP levels may not indicate the presence of a GCT and that decisions to treat should not be based solely on AFP levels <20 ng/mL. Similarly, further workup should be considered before initiating treatment for mildly elevated beta-hCG (generally <20 IU/L) as other factors such as hypogonadism and cannabis use can cause false-positive results. Elevations of AFP either pre- or post-orchiectomy indicate the presence of nonseminomatous elements. For patients with elevated beta-hCG levels pre-orchiectomy, beta-hCG levels should be followed with repeated determinations after orchiectomy to determine their trajectory and, if declining, their nadir. The expected half-life for beta-hCG is ≤3 days. For patients with normal imaging (ie, stage I), rising or persistently elevated beta-hCG levels generally indicate the presence of metastatic disease (stage IS). For patients with metastatic disease to the retroperitoneum or beyond (stage II and III), highly elevated beta-hCG levels (>1000 IU/L) may indicate the presence of non-seminomatous tumor elements. Sperm banking should be recommended to patients of reproductive age, if clinically indicated, before undergoing any therapeutic intervention that may compromise fertility.[41-44]

It should be noted that the Panel recommends staging tumors with discontinuous invasions of the spermatic cord as pT3 (high-risk stage I) and not as M1 (stage III) as is recommended in the 8th edition of the AJCC Cancer Staging Manual. It is critical to remember that risk of relapse to the pelvis is higher in these patients; thus, the pelvis should be included in imaging. Additionally, if a patient presents with mediastinal primary nonseminoma, this is considered poor-risk disease and should be treated with either VIP or BEP along with careful pulmonary functioning monitoring.[151]

Discussion update in progress

Nonseminoma Stage I With and Without Risk Factors

Primary Treatment for Nonseminoma Stage I With and Without Risk Factors

The NCCN Panel recommends treating patients with stage I nonseminoma based on the presence or absence of risk factors known to be associated with an increased risk of relapse (LVI, invasion of the spermatic cord, or invasion of the scrotum).[48-56] Some centers also consider predominance of embryonal carcinoma as an additional risk factor for relapse. However, regardless of risk factors, patients with stage I nonseminoma with normal post-orchiectomy serum AFP and beta-hCG levels have three management options for primary treatment after orchiectomy: surveillance,[53,61,152,153] nerve-sparing RPLND,[154] or adjuvant chemotherapy with one cycle of BEP.[155,156] The major difference in the

Version 1.2026 © 2025 National Comprehensive Cancer Network© (NCCN©), All rights reserved. NCCN Guidelines® and this illustration may not be reproduced in any form without the express written permission of NCCN.

PLEASE NOTE that use of this NCCN Content is governed by the End-User License Agreement, and you MAY NOT distribute this Content or use it with any artificial intelligence model or tool.
Printed by Máximo López Chenlo on 5/4/2026 6:31:34 PM. Copyright © 2026 National Comprehensive Cancer Network, Inc. All Rights Reserved.

treatment of patients at low risk and high risk is that surveillance is preferred for patients with stage I nonseminoma without risk factors, as it has been shown that the presence of risk factors, such as LVI, is a significant predictor of relapse when orchiectomy is followed by surveillance alone,[35] whereas all three management options should be carefully considered when risk factors are present. It should be noted that surveillance or RPLND are also recommended options for patients with stage I pure teratoma and normal markers. The survival rates for stage I nonseminoma managed with surveillance, nerve-sparing RPLND, or one cycle of BEP chemotherapy exceed 98%. However, the high survival rate associated with surveillance depends on adherence to periodic follow-up examinations and subsequent chemotherapy for the 20% to 30% of patients who relapse. Therefore, patients who choose surveillance should adhere to the follow-up schedule.

If nerve-sparing RPLND is chosen as primary treatment, it should be done within 4 weeks of a CT or MRI and within 2 weeks of repeat serum marker testing to ensure accurate presurgical staging.[157] A template dissection or nerve-sparing approach to minimize the risk of ejaculatory disorders should be considered in patients undergoing primary RPLND for stage I nonseminoma. The “split and roll” technique in which lumbar vessels are identified and sequentially ligated allows resection of all lymphatic tissue around and behind the great vessels (ie, aorta, inferior vena cava) and minimizes the risk of an in-field recurrence. Limited data suggest increased frequency of aberrant recurrences with the use of minimally invasive laparoscopic or robotic approaches to RPLND. A recent case study of recurrence patterns in patients following robotic RPLND found that recurrences were highly variable, were in unusual locations, and were associated with a high treatment burden.[158] However, two retrospective reviews on robotic RPLND done at experienced centers showed that this technique can be performed safely with low complication rates and similar oncologic outcomes to an open approach.[159,160] Therefore, minimally invasive RPLND is not currently recommended as standard management, but can be considered in highly selected cases. Referral to a high-volume center is recommended for patients undergoing RPLND. For patients electing one cycle of BEP, imaging is also recommended within 4 weeks prior to the initiation of chemotherapy to confirm staging, even if scans were done previously. In a prospective trial by SWENOTECA, patients with stage I nonseminoma with or without LVI received one course of adjuvant BEP.[156] The relapse rate at 5 years was 3.2% for patients with LVI and 1.6% for patients without LVI. Five-year OS was 100% in both groups.[48] The results after a median follow-up of 7.9 years confirmed the low relapse rate with one course of adjuvant BEP, especially in patients with LVI.[48] Several other studies using two cycles of BEP as primary treatment for patients with stage I nonseminoma have similarly reported relapse-free survival rates of >95%.[153,161-165] However, late consequences of cisplatin-based chemotherapy, such as hearing damage and loss, cardiovascular conditions, hypertension, and neuropathy, have been reported during long-term follow-up.[166-174] Therefore, one cycle of BEP is recommended due to its lower toxicity.

Follow-up for Nonseminoma Stage I With and Without Risk Factors

There is no single follow-up plan that is appropriate for patients with nonseminoma; however, the Panel has provided guidance for the first 5 years after completion of therapy. Modifications for individual patients based on the biology of the disease as well as the length of time on treatment should be considered along with an extension beyond 5 years at the discretion of the treating physician. Follow-up strategies for stage I nonseminoma are dependent on the presence or absence of risk factors as well as the treatment modality received.

Discussion update in progress

Version 1.2026 © 2025 National Comprehensive Cancer Network© (NCCN©), All rights reserved. NCCN Guidelines® and this illustration may not be reproduced in any form without the express written permission of NCCN.

PLEASE NOTE that use of this NCCN Content is governed by the End-User License Agreement, and you MAY NOT distribute this Content or use it with any artificial intelligence model or tool.
Printed by Máximo López Chenlo on 5/4/2026 6:31:34 PM. Copyright © 2026 National Comprehensive Cancer Network, Inc. All Rights Reserved.

Follow-Up During Surveillance

Long-term follow-up for patients with stage I nonseminoma without risk factors and for those with risk factors are outlined in Table 7 and 8 on TEST-B 1 of 3 in the algorithm. Both include a history and physical examination, serum tumor marker assessment, abdomen/pelvis CT scan with contrast or MRI with and without contrast, and chest x-ray at different intervals. These tests are more frequent in patients with risk factors. The MRI protocol should include visualization of the retroperitoneal and pelvis nodes as well as all other nodes that need to be assessed. Chest CT with contrast is preferred over chest x-ray in the presence of thoracic symptoms for patients regardless of treatment type as routine chest x-ray may have limited value for detecting relapse in patients with stage I nonseminoma. In a recent retrospective study, a total of 76 relapses were detected among 561 patients with stage I nonseminoma treated with surveillance following orchiectomy.[114] All relapses were detected by either rising serum tumor markers and/or abnormal routine follow-up CT scans; no single relapse was detected by chest x-ray alone. Similar results have been reported in other studies, calling into question the value of chest x-rays in surveillance settings for stage I nonseminomatous GCTs.[61,115,175]

Follow-Up After 1 Cycle of Adjuvant BEP or Primary RPLND

Follow-up of patients treated with either 1 cycle of adjuvant BEP or with primary RPLND is outlined in Table 9 on TEST-B 2 of 3 in the algorithm and includes history and physical examination with testicular ultrasound for any equivocal exam, evaluation of serum makers, CT/MRI of the abdomen and pelvis, and a chest x-ray. While the chest x-ray can be used for routine follow-up, chest CT with contrast is preferred in patients with thoracic symptoms.

Nonseminoma Stage IS

Patients with stage IS nonseminoma exhibit highly elevated or persistently rising serum tumor markers post-orchiectomy, but no radiographic evidence of disease. However, mildly elevated levels of AFP or beta-hCG after orchiectomy must be interpreted with caution. Mildly elevated, non-rising AFP levels (<20 ng/mL) may not indicate the presence of a GCT and should not be used to guide treatment decisions. In addition, hyperthyroidism, cannabis use, hypogonadism, and heterophile antibodies can result in significant elevations of beta-hCG.[27-29,31,32] Elevated beta-hCG due to metastatic disease typically rises steadily on serial measurements. In patients with mildly elevated but stable beta-hCG and no other evidence of metastatic disease, repeating the test using a different assay should be considered. Furthermore, many different conditions can result in an elevation of LDH, including many benign conditions. Therefore, patients should not be treated with chemotherapy for systemic disease if the only evidence of systemic disease is an elevation of LDH.

Primary Treatment for Nonseminoma Stage IS

The NCCN Panel recommends that patients with stage IS nonseminoma be treated with first-line chemotherapy (see *First-Line Chemotherapy Regimens for Germ Cell Tumors* [TEST-E] in the algorithm) if the elevated marker is AFP or beta-hCG. For the purposes of this guideline, the NCCN Panel assumes that patients with stage IS disease have markers in the S1 range. It would be extraordinarily rare for a patient to have an AFP >1000 ng/mL or a beta-hCG >5000 IU/L and yet have no evidence of metastatic disease on imaging studies. These guidelines cannot address every possible situation, and the treatment of those rare patients with T any, N0, M0, S2–3 disease should be individualized; referral to a high-volume center is recommended. The vast majority of patients with stage IS have serum tumor markers in the S1 range, and they should receive first-line chemotherapy for good-risk disease: either three cycles of BEP or four cycles of EP (both preferred). Both regimens are category 1 recommendations, and either is preferable to initial RPLND as these patients nearly always have disseminated disease.[176,177]

Discussion update in progress

Version 1.2026 © 2025 National Comprehensive Cancer Network© (NCCN©), All rights reserved. NCCN Guidelines® and this illustration may not be reproduced in any form without the express written permission of NCCN.

PLEASE NOTE that use of this NCCN Content is governed by the End-User License Agreement, and you MAY NOT distribute this Content or use it with any artificial intelligence model or tool.
Printed by Máximo López Chenlo on 5/4/2026 6:31:34 PM. Copyright © 2026 National Comprehensive Cancer Network, Inc. All Rights Reserved.

Management of Nonseminoma Stage IS After Primary Treatment

The treatment of patients with stage IS nonseminoma after primary treatment with chemotherapy is described below in *Advanced Metastatic Nonseminoma* (see *Management of Good-, Intermediate-, and Poor-Risk Nonseminoma After Chemotherapy*).

Nonseminoma Stage IIA and IIB

Primary Treatment for Nonseminoma Stage IIA

Primary treatment for patients with stage IIA nonseminoma depends on post-orchiectomy serum tumor marker levels. For patients with normal post-orchiectomy levels of AFP and beta-hCG, the NCCN Panel recommends either nerve-sparing RPLND or chemotherapy with three cycles of BEP or four cycles of EP as primary treatment options (both BEP and EP are preferred regimens).[178,179] Chemotherapy is considered particularly appropriate if the patient has multifocal disease. RPLND is preferred as primary treatment for stage II tumors with somatic type malignancy (previously referred to as transformed teratoma). Referral to a high-volume center is recommended for those patients who undergo nerve-sparing RPLND. For patients with stage IIA seminoma with persistently elevated AFP and/or beta-hCG levels, the NCCN Panel recommends first-line chemotherapy with three cycles of BEP or four cycles of EP (both category 1; both preferred).[154,180] For more information on these regimens, see *Primary Treatment for Good-Risk Nonseminoma* below. A bleomycin-free regimen should be given to patients at higher risk for bleomycin-related complications (eg, patients aged >50 years, those with diminished renal function, those with underlying lung disease). It should be noted that for select cases of clinical stage IIA disease with borderline retroperitoneal lymph nodes, waiting 4 to 8 weeks and repeating imaging to confirm staging before initiating treatment can be considered.

Primary Treatment for Nonseminoma Stage IIB

Primary treatment for patients with stage IIB nonseminoma also depends on post-orchiectomy tumor marker levels as well as on radiographic findings. When tumor marker levels are normal, the CT/MRI findings determine the proper course of treatment. If abnormal radiographic findings are limited to lymph node metastases within lymphatic drainage sites in the retroperitoneum (ie, the landing zone), patients may receive first-line chemotherapy with either three cycles of BEP or four cycles of EP (both preferred) or primary nerve-sparing RPLND (reserved for highly selected cases; ie, stage II tumors with teratoma predominance in patients with normal markers). RPLND is also recommended for stage II tumors with somatic type malignancy (previously referred to as transformed teratoma). Referral to a high-volume center is recommended for nerve-sparing RPLND. Both options of first-line chemotherapy or primary nerve-sparing RPLND are comparable in terms of outcome, but side effects and toxicity are different.[179] The reported relapse-free survival with either approach is close to 98%.[181-185] If metastatic disease (based on radiographic findings) is not confined to within the lymphatic drainage sites (ie, multifocal or symptomatic lymph node metastases with aberrant lymphatic drainage sites), first-line chemotherapy (three cycles of BEP or four cycles of EP; both preferred) is recommended. For patients with stage IIB nonseminoma with persistent marker elevation, the recommended treatment option is also first-line chemotherapy with either three cycles of BEP or four cycles of EP (both category 1; both preferred). For more information on these regimens, see *Primary Treatment for Good-Risk Nonseminoma* below. A bleomycin-free regimen should be given to patients at higher risk for bleomycin-related complications (ie, patients aged >50 years, those with diminished renal function, and those with underlying lung disease).

Discussion update in progress

Version 1.2026 © 2025 National Comprehensive Cancer Network© (NCCN©), All rights reserved. NCCN Guidelines® and this illustration may not be reproduced in any form without the express written permission of NCCN.

PLEASE NOTE that use of this NCCN Content is governed by the End-User License Agreement, and you MAY NOT distribute this Content or use it with any artificial intelligence model or tool.
Printed by Máximo López Chenlo on 5/4/2026 6:31:34 PM. Copyright © 2026 National Comprehensive Cancer Network, Inc. All Rights Reserved.

Management of Nonseminoma Stage IA, IB With and Without Risk Factors, IIA, IIB Treated with Primary Nerve-Sparing RPLND

Treatment options following primary nerve-sparing RPLND include either surveillance or chemotherapy, depending on the number of positive lymph nodes identified. Since RPLND is likely a curative procedure in patients with pN0 disease, surveillance is recommended for this group. Surveillance is also the preferred option for patients with pN1 disease, although chemotherapy with two cycles of EP can also be considered.[154,186] The risk of relapse in clinical stage IIA nonseminoma patients with pN2 or pN3 disease after RPLND is >50%.[154,184] This risk is reduced to <1% with two cycles of adjuvant cisplatin-based chemotherapy.[154,181,183] Therefore, the NCCN Panel prefers two cycles of adjuvant chemotherapy with EP to surveillance for pN2 disease and recommends either 2 to 3 cycles of BEP or 2 to 4 cycles of EP for pN3 disease. As pN3 disease is a rare circumstance, the Panel could not reach a consensus as to the optimal regimen due to the limited data available. Surveillance may also be an option for patients with pN2 and pN3 disease and, if chosen for pN3 disease, a CT/MRI of the abdomen/pelvis or a chest x-ray should be conducted 2 to 3 months post-RPLND.[187] Surveillance is preferred for patients with pure teratoma.

Follow-up for Pathologic Stage IIA/B/C Nonseminoma Undergoing Surveillance After Primary RPLND and Treated with Adjuvant Chemotherapy

Follow-up for patients after RPLND and adjuvant chemotherapy is outlined in Table 11 on TEST-B 3 of 3 in the algorithm and consists of a medical history and physical examination, serum tumor marker assessment, CT with contrast or MRI with and without contrast of the abdomen/pelvis, and chest x-ray. The MRI protocol should include visualization of the retroperitoneal and pelvis nodes as well as all other nodes that need to be assessed. Chest CT with contrast is preferred over chest x-ray in the presence of thoracic symptoms. It should be noted that patients who undergo RPLND and are found to have pN0 disease or pN1 pure teratoma need only 1 CT scan at postoperative month 3 to 4 and then as clinically indicated.

Follow-up for Pathologic Stage IIA/B Nonseminoma Undergoing Surveillance After Primary RPLND and NOT Treated with Adjuvant Chemotherapy

Follow-up for patients after RPLND and adjuvant chemotherapy is outlined in Table 12 on TEST-B 3 of 3 in the algorithm and consists of a medical history and physical examination, serum tumor marker assessment, CT with contrast or MRI with and without contrast of the abdomen/pelvis, and chest x-ray. There is an increase in frequency of these tests as compared to the schedule for patients who received adjuvant chemotherapy due to the increase in relapse rates.[188] The MRI protocol should include visualization of the retroperitoneal and pelvis nodes as well as all other nodes that need to be assessed. Chest CT with contrast is preferred over chest x-ray in the presence of thoracic symptoms. It should be noted that in patients who have pathologic stage IIC disease, more frequent imaging is recommended.

Management of Nonseminoma Stage IIA and IIB Treated with First-Line Chemotherapy

Subsequent management after first-line chemotherapy depends on the size of the residual mass on CT or MRI. Patients should thus undergo abdomen/pelvis CT scan with contrast or MRI with and without contrast within 1 month of completing chemotherapy; chest CT, MRI, or chest x-ray may also be considered. FDG-PET/CT scan is not clinically indicated for nonseminoma. Masses should be measured along the transaxial long axis (not the craniocaudal axis). If markers are negative and the residual mass is ≥1 cm after chemotherapy, nerve-sparing bilateral RPLND is recommended within 4 weeks of CT/MRI and within 2 weeks of confirmation of normal tumor markers. A bilateral RPLND involves removal of lymphatic tissue between both ureters, spanning from the diaphragmatic

Discussion update in progress

Version 1.2026 © 2025 National Comprehensive Cancer Network© (NCCN©), All rights reserved. NCCN Guidelines® and this illustration may not be reproduced in any form without the express written permission of NCCN.

PLEASE NOTE that use of this NCCN Content is governed by the End-User License Agreement, and you MAY NOT distribute this Content or use it with any artificial intelligence model or tool.
Printed by Máximo López Chenlo on 5/4/2026 6:31:34 PM. Copyright © 2026 National Comprehensive Cancer Network, Inc. All Rights Reserved.

crus to the bifurcation of the common iliac arteries. The rationale for this extended region of dissection is the greater likelihood of bilateral disease with greater tumor burden.[188] Modified template RPLND may be an option in select patients with initial stage IIA/B disease within the primary landing zones. The major morbidity associated with bilateral RPLND is retrograde ejaculation, resulting in infertility. Nerve-sparing dissection techniques preserve antegrade ejaculation in 90% of cases.[189] Therefore, nerve-sparing RPLND is recommended. For patients with negative markers and no residual mass or a residual mass <1 cm, surveillance is recommended; nerve-sparing bilateral RPLND is a category 2B recommendation in this setting and may be performed in selected cases, including in patients with subcentimeter residual nodes who have teratoma or yolk sac tumor in their primary tumors. Referral to a high-volume center is recommended for surgical resection of masses post-chemotherapy. If only necrotic debris or teratoma is present in the resected tissue, the patient should be put under surveillance. If embryonal, yolk sac, choriocarcinoma, or seminoma elements are found in the residual mass, then two cycles of chemotherapy with either TIP, VIP, VelP, or EP is preferred. Surveillance could be considered as a reasonable alternative to chemotherapy for patients with residual masses that have been completely resected if all the residual masses have <10% viable cancer cells in the resected tissue.

Follow-up for Nonseminoma Stage II–III Surveillance After Chemotherapy With or Without Surgery

The 5-year follow-up for patients with stage II–III nonseminoma treated with chemotherapy with or without RPLND can be found in Table 10 on TEST-B 2 of 3 in the algorithm and includes history and physical examinations, serum tumor marker assessments, chest x-rays, and abdomen/pelvis CT scans with contrast. An MRI with and without can be considered to replace an abdomen/pelvis CT with the protocol including visualization of the retroperitoneal and pelvis nodes. Chest x-ray may be used for routine follow-up, but chest CT with contrast is preferred in patients with thoracic symptoms. Annual measurement of serum tumor markers can be considered for years 5 through 10 following complete response to first-line chemotherapy in patients with metastatic disease.[190] Additionally, patients with clinical stage II disease treated with chemotherapy who undergo postchemotherapy RPLND and are found to have pN0 disease or pN1 pure teratoma need only 1 CT scan at postoperative month 3 or 4 and then as clinically indicated while patients who only have a partial response to chemotherapy who are not surgical candidates may require more frequent imaging.

Advanced Metastatic Nonseminoma

The first-line chemotherapy options for patients with advanced metastatic nonseminoma are based on the IGCCCG risk classification, which categorizes patients as good, intermediate, or poor risk based on identification of clinically independent prognostic features such as extent of disease and post-orchiectomy levels of serum tumor markers.[69] When determining a patient's risk classification, the relevant serum tumor marker value is the value on Day 1 of cycle one of first-line chemotherapy.

Primary Treatment for Good-Risk Nonseminoma

The IGCCCG good-risk group includes patients with stages IS, IIA (S1), IIB (S1), IIC, and IIIA disease. The treatment goal for good-risk disease is to limit toxicity while maintaining maximal efficacy. Presently, two regimens are recommended by the NCCN Panel: three cycles of BEP[127,129,191] or four cycles of EP[128,129,191] (both category 1; both preferred). Both regimens are well tolerated and cure approximately 90% of patients with good-risk disease.[191,192] The only trial that directly compared these two regimens found no statistically significant difference in OS (96% in the BEP x 3 arm vs. 92% in the EP x 4 arm; $P = .096$) or event-free survival (91% with BEP x 3 vs. 86% with EP x 4; $P = .135$).[191] Factors that should be considered when choosing between three cycles of BEP and four cycles of EP include the duration of treatment (9 weeks compared to 12

Discussion update in progress

Version 1.2026 © 2025 National Comprehensive Cancer Network© (NCCN©), All rights reserved. NCCN Guidelines® and this illustration may not be reproduced in any form without the express written permission of NCCN.

PLEASE NOTE that use of this NCCN Content is governed by the End-User License Agreement, and you MAY NOT distribute this Content or use it with any artificial intelligence model or tool.
Printed by Máximo López Chenlo on 5/4/2026 6:31:34 PM. Copyright © 2026 National Comprehensive Cancer Network, Inc. All Rights Reserved.

weeks) and regimen-specific toxicities (bleomycin is associated with reduced pulmonary function while cisplatin is associated with peripheral neuropathy and hearing loss). The physician and patient should make a shared informed decision based on patient clinical characteristics and preferences. A bleomycin-free regimen should be given to patients at higher risk for bleomycin-related complications (ie, patients aged >50 years, those with diminished renal function, those with underlying lung disease). Some oncologists prefer four cycles of EP for patients who smoke heavily regardless of lung function.

Primary Treatment for Intermediate-Risk (Stage IIIB) Nonseminoma

For patients with intermediate-risk disease, the cure rate is approximately 70% with the standard chemotherapy regimen of four cycles of BEP.[193,194] Therefore, the NCCN Panel recommends four cycles of BEP (preferred), or four cycles of VIP[193,195] for patients who are at higher risk for bleomycin-related complications, for the treatment of intermediate-risk (stage IIIB) nonseminoma. Both regimens are category 1 recommendations. However, if intermediate-risk status is based solely on LDH levels 1.5 to 3 × ULN, then three cycles of BEP or four cycles of EP[196] can be considered.

Primary Treatment for Poor-Risk (Stage IIIC) Nonseminoma

The standard chemotherapy regimen for poor-risk disease is four cycles of BEP (preferred). Alternatively, four cycles of VIP can be used to treat patients who are at higher risk for bleomycin-related complications.[195] Both regimens are category 1 recommendations. However, <50% of patients with poor-risk nonseminoma experience a durable complete response to four cycles of BEP, and up to 50% die of their disease.[69,197] Therefore, referral to a high-volume center is recommended for the treatment of patients with poor-risk nonseminoma.[192] It should be noted that, while a rare circumstance, patients with poor-risk disease with choriocarcinoma-predominant histology, very high beta-hCG, and large lung or brain metastases may experience hemorrhaging after initiation of chemotherapy. These patients should be more closely monitored and may require more support.

A randomized phase II trial compared the efficacy of four cycles of BEP to a more intensive regimen (carboplatin, bleomycin, vincristine, and cisplatin/BEP [CBOP/BEP]) in 89 patients with poor-risk nonseminoma.[198] At a median follow-up of 63 months, 3-year PFS was 56% for CBOP/BEP and 39% for BEP (HR, 0.59; $P = .079$). Three-year OS was 65% and 59%, respectively (HR, 0.79; $P = .49$), and there were no differences in toxicity between arms. The CBOP/BEP met response targets (74% complete response or partial response with negative markers) and warrants further study in a phase III trial.

Management of Good-, Intermediate-, and Poor-Risk Nonseminoma After Chemotherapy

At the conclusion of first-line chemotherapy, chest/abdomen/pelvis CT scan with contrast/MRI with and without contrast and measurement of serum tumor marker levels are indicated to assess treatment response. FDG-PET scan has no role in assessing treatment response and residual masses following chemotherapy in patients with nonseminoma. If no mass or a residual mass <1 cm on the transaxial long axis is found by radiographic imaging and the tumor marker levels are normal, the Panel recommends surveillance. Nerve-sparing bilateral RPLND can be considered in select cases for patients with disease that is any T, N1–3, and M0–1 as well as in patients with subcentimeter residual nodes who have teratoma or yolk sac tumor in their primary tumor (category 2B).[199] RPLND is recommended within 4 weeks of the CT scan and 2 weeks of marker measurement. Referral to high-volume centers is recommended for surgical resection of residual masses following chemotherapy.

If there is a partial radiographic response to chemotherapy (as indicated by the presence of residual masses) and tumor marker levels are normal, then surgical resection of all residual masses is recommended.[200-203] As

Discussion update in progress

Version 1.2026 © 2025 National Comprehensive Cancer Network© (NCCN©), All rights reserved. NCCN Guidelines® and this illustration may not be reproduced in any form without the express written permission of NCCN.

PLEASE NOTE that use of this NCCN Content is governed by the End-User License Agreement, and you MAY NOT distribute this Content or use it with any artificial intelligence model or tool.
Printed by Máximo López Chenlo on 5/4/2026 6:31:34 PM. Copyright © 2026 National Comprehensive Cancer Network, Inc. All Rights Reserved.

previously stated, referral to high-volume centers is recommended for surgical resection of masses post-chemotherapy. If only necrotic debris or teratoma is present in the resected tissue, the patient should be put under surveillance. If embryonal, yolk sac, choriocarcinoma, or seminoma elements are found in the residual mass, then two cycles of chemotherapy with either EP, TIP, VIP, or VelP should be administered. All regimens are preferred in this setting, although EP should be considered for patients with low-volume residual disease. If there is a teratoma with somatic-type malignancy, consider histology-directed therapy and referral to a high-volume center. Surveillance can also be considered for patients with residual masses that have been completely resected if all the residual masses have <10% viable tumor cells in the resected tissue.

Further treatment for patients who experience a partial radiographic response to chemotherapy (residual masses) with abnormal tumor marker levels is guided by the kinetics of the tumor markers. If tumor marker levels are elevated and persistently rising, the Panel recommends a full course of second-line chemotherapy (see *Second-Line Therapy* below). Brain imaging and testicular ultrasound should be considered in patients with elevated or rising markers following first-line or second-line chemotherapy to evaluate for occult brain metastases or contralateral primary disease. Patients with elevated but stable marker levels should be closely surveilled. Patients with mildly elevated and normalizing markers should be considered for surgical resection of residual masses with subsequent post-surgical treatment as discussed above. The Panel recommends referral to a high-volume center for the treatment of patients with a partial response to first-line chemotherapy and abnormal marker levels.

Follow-up for Good-, Intermediate-, and Poor-Risk Nonseminoma

The 5-year follow-up for patients with good-, intermediate-, and poor-risk nonseminoma after chemotherapy (with or without post-chemotherapy RPLND) includes history and physical examination, serum tumor marker assessment, chest x-ray, and abdomen/pelvis CT with contrast or MRI with and without contrast. The frequency of these tests is outlined in Table 10 on TEST-B 2 of 3 in the algorithm. Annual measurement of serum tumor markers can be considered for years 5 through 10 and as clinically indicated thereafter following complete response to first-line chemotherapy in patients with metastatic disease.[190] Patients who have an incomplete response to chemotherapy require more frequent imaging than is outlined in the table. Patients who undergo RPLND and are found to have pN0 disease or pN1 pure teratoma need only one CT scan at postoperative months 3 to 4 and then as clinically indicated. The MRI protocol should include all the nodes that need to be assessed, and chest x-ray may be used for routine follow-up. However, a chest CT with contrast is preferred in patients with thoracic symptoms, and a chest CT with contrast should be performed at baseline if supradiaphragmatic disease is present.

Second-Line and Subsequent Therapy for Metastatic Germ Cell Tumors

Second-Line Therapy

Patients with disease relapse following first-line therapy, or those who do not experience a durable complete response to first-line therapy, should receive second-line therapy. Patients with recurrent disease who have not been treated with prior chemotherapy should be treated per their risk status, as described in the preceding sections. Additionally, if a patient received prior adjuvant therapy (ie, one cycle of BEP only), first-line chemotherapy as previously discussed is recommended. It is preferred by the Panel that patients with recurrent seminoma or nonseminoma be treated at centers with expertise in the management of this disease. Sperm banking is also recommended if not already performed. While more data are still needed in this space, the Panel recommends that a patient should wait at least 6 months post-chemotherapy to conceive a child or up to 2 years if using extreme caution. Second-line therapy options for

Discussion update in progress

Version 1.2026 © 2025 National Comprehensive Cancer Network© (NCCN©), All rights reserved. NCCN Guidelines® and this illustration may not be reproduced in any form without the express written permission of NCCN.

PLEASE NOTE that use of this NCCN Content is governed by the End-User License Agreement, and you MAY NOT distribute this Content or use it with any artificial intelligence model or tool.
Printed by Máximo López Chenlo on 5/4/2026 6:31:34 PM. Copyright © 2026 National Comprehensive Cancer Network, Inc. All Rights Reserved.

patients with relapsed seminoma or early relapses (within ≤2 years of the completion of primary therapy) of nonseminoma include enrollment in a clinical trial (preferred), conventional-dose chemotherapy, or high-dose chemotherapy. If chemotherapy is given, the conventional-dose regimens that are preferred in this setting are TIP or VeIP, both of which are high risk for febrile neutropenia so G-CSFs should be used.[144,204-206] The preferred high-dose regimens include high-dose carboplatin plus etoposide followed by peripheral blood stem cell infusion,[207] or paclitaxel plus ifosfamide followed by high-dose carboplatin plus etoposide with stem cell support.[208] Alternatively, surgery may be considered for nonseminoma if the recurrent mass is in a solitary resectable site and markers are normal or only mildly elevated.[209] Late relapses of nonseminoma (>2 years after completion of first-line therapy) occur in 2% to 3% of testicular cancer survivors.[210,211] The Panel prefers surgical treatment for these patients, if the recurrent mass is resectable, regardless of marker levels.[209] Clinical trial enrollment or chemotherapy (conventional-dose or high-dose using the same regimens noted above) are options for patients with unresectable late relapses.

An ongoing, randomized, international, phase III trial (TIGER) will compare second-line conventional-dose chemotherapy with high-dose chemotherapy in patients with relapsed GCTs.[212] The foundation of the TIGER trial was formed based on the results of a large retrospective analysis by Lorch et al, which demonstrated the superiority of carboplatin-based high-dose chemotherapy compared to cisplatin-based conventional-dose chemotherapy with respect to 2-year PFS (50% vs. 28%; $P < .001$) and 5-year OS (53% vs. 41%; $P < .001$).[213,214] The TIGER trial will randomize patients with unequivocal disease progression following cisplatin-based first-line chemotherapy to receive conventional-dose TIP or high-dose paclitaxel plus ifosfamide followed by high-dose carboplatin plus etoposide with stem cell support. OS is the primary endpoint. Secondary endpoints include PFS, response rate, toxicity, quality of life, and biological correlates.[212,213] This trial has completed patient recruitment and results are expected sometime in the near future (Clinical Trial ID: NCT02375204).

Management of Metastatic Germ Cell Tumors After Second-Line Therapy

To assess response after second-line therapy, a CT scan with contrast or MRI with and without contrast of the chest, abdomen, pelvis, and any other sites of disease is recommended. FDG-PET/CT scan has no role in assessing treatment response and residual masses following chemotherapy in patients with nonseminoma but could be considered in assessing treatment response and residual masses following chemotherapy in patients with seminoma. Levels of serum tumor markers should also be measured. For patients with seminoma, follow-up is similar to post first-line chemotherapy treatment discussed above. Patients with nonseminoma that demonstrate a complete response to second-line therapy with normal marker levels should be put under surveillance. Alternatively, select patients with nonseminoma may receive nerve-sparing bilateral RPLND (category 2B), followed by surveillance. Referral to a high-volume center is recommended for nerve-sparing RPLND. For patients with nonseminoma and a partial response to second-line therapy (as indicated by residual masses on CT scan) and normal marker levels, surgical resection of all residual masses is recommended followed by surveillance. If there is a teratoma with somatic-type malignancy, consider histology-directed therapy and referral to a high-volume center. Patients with a partial response to second-line therapy (residual masses) and abnormal marker levels should be treated according to the kinetics of the tumor markers. If tumor marker levels are elevated and persistently rising, the Panel recommends third-line therapy (see *Third-Line Therapy* below). Patients with elevated but stable tumor marker levels should be closely surveilled. Patients with mildly elevated and normalizing markers should be considered for surgical resection of residual masses followed by

Discussion update in progress

Version 1.2026 © 2025 National Comprehensive Cancer Network© (NCCN©), All rights reserved. NCCN Guidelines® and this illustration may not be reproduced in any form without the express written permission of NCCN.

PLEASE NOTE that use of this NCCN Content is governed by the End-User License Agreement, and you MAY NOT distribute this Content or use it with any artificial intelligence model or tool.
Printed by Máximo López Chenlo on 5/4/2026 6:31:34 PM. Copyright © 2026 National Comprehensive Cancer Network, Inc. All Rights Reserved.

surveillance. Referral to high-volume centers is recommended for surgical resection of residual masses following chemotherapy.

Third-Line Therapy

Third-line therapy is recommended for patients with progressive disease (growing mass or rising markers) or recurrent disease following second-line therapy. Participation in a clinical trial is the preferred treatment option for patients who experience relapse and have received prior high-dose chemotherapy. Alternatively, for patients previously treated with conventional-dose chemotherapy, high-dose regimens are preferred. For those patients with seminoma, conventional-dose third-line chemotherapy can be considered regardless of previous treatment and RT can be considered in select patients. Alternative options for patients with nonseminoma previously treated with either high-dose or conventional-dose regimens also includes surgical treatment (if solitary resectable site). Molecular testing, including microsatellite instability/mismatch repair (MSI/MMR) or tumor mutational burden (TMB) testing, is also recommended to determine eligibility for pan-cancer, tumor-agnostic biomarker-directed therapies. The preferred treatment option for patients with nonseminoma who experience a late relapse (>2 years after completion of second-line therapy) is surgery if the recurrent mass is resectable. Conventional-dose or high-dose chemotherapy (if not previously received) are also options for patients with late relapse.

In order to maintain optimal efficacy and limit treatment-related toxicities, the chemotherapy regimens previously received by the patient should be considered when deciding on third-line therapy options. High-dose chemotherapy is the preferred third-line option if it has not been previously received. If high-dose chemotherapy was previously received by the patient, then palliative chemotherapy is the preferred third-line treatment option. Additionally, the Panel considers pembrolizumab immunotherapy to be useful in certain circumstances (ie, in patients with MSI-high/MMR-deficient [MSI-H/dMMR] or TMB-high [TMB-H, ≥10 mutations/megabase] tumors as determined by a validated and/or U.S. Food and Drug Administration [FDA]-approved comprehensive genomic profiling [CGP] assay).[215-218]

The recommended third-line palliative chemotherapy options for patients with intensively pretreated, cisplatin-resistant, or refractory GCTs are combinations of gemcitabine with paclitaxel and/or oxaliplatin,[219-225] or oral etoposide.[226] The recommendation for gemcitabine and oxaliplatin (GEMOX) is based on data from phase II studies investigating the efficacy and toxicity of GEMOX in patients with relapsed or cisplatin-resistant GCTs.[220,222,224] These studies showed that GEMOX is safe for patients with cisplatin-resistant testicular GCTs and may offer a chance of long-term survival.[220,222,224] Gemcitabine plus paclitaxel is another option that has shown promising results in a phase II study.[221] Follow-up results showed long-term DFS in patients who progressed after high-dose chemotherapy and had not received prior paclitaxel or gemcitabine.[223] A phase II study of patients with treatment-resistant GCTs also found the combination of gemcitabine, oxaliplatin, and paclitaxel to be effective with acceptable toxicity.[219] The overall response rate was 51% with 5% of patients achieving a complete response. A second study reported similar results.[225] Additionally, high-dose single-agent oral etoposide was shown to be effective in a phase II study involving patients who had previous treatment with cisplatin/etoposide combination regimens.[226]

Pembrolizumab, an anti-programmed cell death protein 1 (PD-1) antibody, is approved by the FDA for the treatment of patients with unresectable or metastatic MSI-H/dMMR or TMB-H solid tumors that have progressed following prior treatment and who have no satisfactory alternative treatment options.[215,216,218,227,228] In the only trial (phase II) investigating the efficacy of immunotherapy in testicular cancer, 12 patients with nonseminomatous GCTs who progressed after first-line cisplatin-based therapy and ≥1 additional regimen (high-dose or conventional-dose

Discussion update in progress

Version 1.2026 © 2025 National Comprehensive Cancer Network© (NCCN©), All rights reserved. NCCN Guidelines® and this illustration may not be reproduced in any form without the express written permission of NCCN.

PLEASE NOTE that use of this NCCN Content is governed by the End-User License Agreement, and you MAY NOT distribute this Content or use it with any artificial intelligence model or tool.
Printed by Máximo López Chenlo on 5/4/2026 6:31:34 PM. Copyright © 2026 National Comprehensive Cancer Network, Inc. All Rights Reserved.

chemotherapy) were treated with pembrolizumab.[229] Two patients achieved stable disease for 28 and 19 weeks, respectively, but no partial or complete responses were observed. There were six grade 3 adverse events, but no immune-related adverse events were reported. Therefore, pembrolizumab was well tolerated but appears to have limited single-agent activity in refractory GCTs. However, larger phase II and phase III trials of pembrolizumab in patients with metastatic or refractory testicular cancers are needed to fully assess the value of this therapy, especially in treating MSI-H/dMMR or TMB-H testicular GCTs.

Treatment of Brain Metastases

Brain metastases from testicular GCTs are relatively rare and occur almost exclusively in patients with nonseminoma histology.[230] The development of brain metastases may be more common in patients with a higher burden of systemic disease; lung, liver, and/or bone metastases; high levels of serum beta-hCG (>5000 IU/L); in those with neurologic symptoms; and in those who experience relapse after cisplatin-based chemotherapy. The prognosis of patients with brain metastases from testicular GCTs is poor, with >50% of patients dying within 1 year of diagnosis.[230,231] Patients with additional adverse prognostic factors, especially those with metachronous brain metastases, have even worse outcomes.[230,232,233]

In a retrospective analysis, Loriot et al reported on the pattern of relapse among patients with poor-risk nonseminomatous GCTs previously treated with chemotherapy.[234] After a median follow-up of 4.1 years, 32% were found to have radiographic evidence of brain metastases. The brain was the only site of progression in 54% of these patients and 19% experienced progression in the brain as the first progression event. Furthermore, involvement of the brain was more common among patients who were previously treated with high-dose chemotherapy (29%) compared to BEP (12%). These data suggest that brain metastases from testicular GCTs may occur more frequently than previously thought, often as the only site of progression, and may be more likely to occur in patients at poor risk previously treated with high-dose chemotherapy. However, it is unknown whether this effect was due to the lower cerebral drug penetrance of the high-dose regimen.

The optimal management of brain metastases from testicular GCTs is controversial, with a lack of evidence from prospective trials to guide treatment decisions.[230,232] Therefore, management decisions are usually based on institutional preferences, which may in part explain the large variation in treatment modalities received by these patients. The NCCN Guidelines recommend first-line cisplatin-based chemotherapy (chemotherapy for poor-risk disease) for patients with brain metastases. The addition of RT to chemotherapy regimens can also be considered.[235] Surgical resection of metastatic brain lesions should be performed if clinically indicated and feasible. A recent retrospective analysis reported the treatment of 25 patients with relapsed GCTs and progressive brain metastases who received multimodality therapy, which included high-dose chemotherapy with stem cell support alone or combined with surgery and/or stereotactic or whole-brain RT.[236] At a median follow-up of 24.5 months, 44% of patients were alive with no evidence of disease, suggesting that this subset of patients with historically poor prognosis can potentially be cured with this approach.

Malignant Transformation of Teratoma

Teratoma is a pluripotent tissue that has the capacity to dedifferentiate into somatic malignancies. Sarcomas or carcinomas arising from teratoma are generally resistant to chemotherapy and are associated with poor prognosis.[57,237-239] Somatic transformation of teratoma is most frequently seen in patients with metastatic disease who have been treated with chemotherapy. However, this can occasionally be seen in patients who have not received chemotherapy as well. Given the insensitivity of these

Discussion update in progress

Version 1.2026 © 2025 National Comprehensive Cancer Network© (NCCN©), All rights reserved. NCCN Guidelines® and this illustration may not be reproduced in any form without the express written permission of NCCN.

PLEASE NOTE that use of this NCCN Content is governed by the End-User License Agreement, and you MAY NOT distribute this Content or use it with any artificial intelligence model or tool.
Printed by Máximo López Chenlo on 5/4/2026 6:31:34 PM. Copyright © 2026 National Comprehensive Cancer Network, Inc. All Rights Reserved.

tumors to systemic chemotherapy, surgical resection is the preferred treatment if feasible. RPLND should be considered in patients with stage I disease who have teratoma with malignant transformation in their primary tumor in order to eradicate any microscopic retroperitoneal metastases and reduce the risk of relapse. For patients with more advanced disease (stage II or III), complete surgical resection if feasible is preferred. For patients with unresectable disease, histology-specific chemotherapy should be considered.

Malignant transformation of teratoma along mesodermal lines results in a primitive small round blue cell tumor referred to as embryonic-type neuroectodermal tumor (ENT).[240] This was previously termed primitive neuroectodermal tumor (PNET) arising from teratoma. The preferred modality of therapy for malignant transformation of teratoma to ENT is also surgical resection. ENT transformed from teratoma is resistant to cisplatin-based chemotherapy. Chemotherapy directed to ENT histology is associated with objective response. The preferred regimen consists of cyclophosphamide, doxorubicin, and vincristine (CAV) alternating with ifosfamide plus etoposide (IE).[241] For patients with stage I disease with ENT histology, RPLND should be considered. If ENT histology is present in surgical resection specimen, adjuvant chemotherapy with CAV alternating with IE for a total of four cycles should be considered. [241,242] Rarely, GCTs may originate in extragonadal sites (usually the retroperitoneum or mediastinum). Patients with an extragonadal primary site are treated similarly to patients with testicular GCTs regarding systemic therapies and management of residual masses.[243] However, due to their rarity, the NCCN Panel recommends that patients with extragonadal GCTs be referred to high-volume centers with experience in managing these tumors.

Summary

The NCCN Guidelines for Testicular Cancer provide an evidence- and consensus-based treatment approach for the treatment of adult patients with seminomatous and nonseminomatous testicular GCTs. Testicular GCTs are sensitive to platinum-based chemotherapy and patients have high cure rates even with metastatic disease. Although the majority of metastatic testicular GCTs are cured with chemotherapy, 20% to 30% of patients will relapse after first-line chemotherapy and require additional treatment strategies. The ongoing international phase III TIGER trial aims to determine whether high-dose or conventional-dose chemotherapy is more effective in the second-line setting for patients with relapsed disease. Patients with platinum-refractory or relapsing tumors after second-line therapy have very poor outcomes despite subsequent-line treatments with no effective alternative therapies. Targeted therapies appear to have limited activity in this setting, although more robust clinical trials are needed to assess their value in treating testicular GCTs. Prognosis for patients with brain metastases remains poor, with a lack of evidence from prospective trials to guide treatment decisions. Therefore, the NCCN Panel encourages patients with metastatic, recurrent, or platinum-refractory testicular GCTs to participate in well-designed clinical trials investigating novel therapeutic strategies to enable further advances for the management of this disease.

Discussion update in progress

Version 1.2026 © 2025 National Comprehensive Cancer Network© (NCCN©), All rights reserved. NCCN Guidelines® and this illustration may not be reproduced in any form without the express written permission of NCCN.

PLEASE NOTE that use of this NCCN Content is governed by the End-User License Agreement, and you MAY NOT distribute this Content or use it with any artificial intelligence model or tool.
Printed by Máximo López Chenlo on 5/4/2026 6:31:34 PM. Copyright © 2026 National Comprehensive Cancer Network, Inc. All Rights Reserved.

References

1. Siegel RL, Giaquinto AN, Jemal A. Cancer statistics, 2024. CA Cancer J Clin 2024;74:12-49. Available at: https://www.ncbi.nlm.nih.gov/pubmed/38230766.

2. SEER Cancer Statistics Factsheets: Testicular Cancer. National Cancer Institute. Bethesda, MD. 2024. Available at: https://seer.cancer.gov/statfacts/html/testis.html. Accessed June 12, 2024.

3. Siegel RL, Kratzer TB, Giaquinto AN, et al. Cancer statistics, 2025. CA Cancer J Clin 2025. Available at: https://www.ncbi.nlm.nih.gov/pubmed/39817679.

4. Sarici H, Telli O, Eroglu M. Bilateral testicular germ cell tumors. Turk J Urol 2013;39:249-252. Available at: https://www.ncbi.nlm.nih.gov/pubmed/26328119.

5. Huyghe E, Matsuda T, Thonneau P. Increasing incidence of testicular cancer worldwide: a review. J Urol 2003;170:5-11. Available at: https://www.ncbi.nlm.nih.gov/pubmed/12796635.

6. Shanmugalingam T, Soultati A, Chowdhury S, et al. Global incidence and outcome of testicular cancer. Clin Epidemiol 2013;5:417-427. Available at: https://www.ncbi.nlm.nih.gov/pubmed/24204171.

7. Verhoeven RHA, Gondos A, Janssen-Heijnen MLG, et al. Testicular cancer in Europe and the USA: survival still rising among older patients. Ann Oncol 2013;24:508-513. Available at: https://www.ncbi.nlm.nih.gov/pubmed/23110807.

8. Chia VM, Quraishi SM, Devesa SS, et al. International trends in the incidence of testicular cancer, 1973-2002. Cancer Epidemiol Biomarkers Prev 2010;19:1151-1159. Available at: https://www.ncbi.nlm.nih.gov/pubmed/20447912.

9. Pishgar F, Haj-Mirzaian A, Ebrahimi H, et al. Global, regional and national burden of testicular cancer, 1990-2016: results from the Global Burden of Disease Study 2016. BJU Int 2019;124:386-394. Available at: https://www.ncbi.nlm.nih.gov/pubmed/30953597.

10. Ghazarian AA, McGlynn KA. Increasing Incidence of Testicular Germ Cell Tumors among Racial/Ethnic Minorities in the United States. Cancer Epidemiol Biomarkers Prev 2020;29:1237-1245. Available at: https://www.ncbi.nlm.nih.gov/pubmed/32385118.

11. Siegel RL, Miller KD, Fuchs HE, Jemal A. Cancer Statistics, 2021. CA Cancer J Clin 2021;71:7-33. Available at: https://www.ncbi.nlm.nih.gov/pubmed/33433946.

12. Turnbull C, Rahman N. Genome-wide association studies provide new insights into the genetic basis of testicular germ-cell tumour. Int J Androl 2011;34:e86-96; discussion e96-87. Available at: https://www.ncbi.nlm.nih.gov/pubmed/21623831.

13. Greene MH, Kratz CP, Mai PL, et al. Familial testicular germ cell tumors in adults: 2010 summary of genetic risk factors and clinical phenotype. Endocr Relat Cancer 2010;17:R109-121. Available at: https://www.ncbi.nlm.nih.gov/pubmed/20228134.

14. Vasdev N, Moon A, Thorpe AC. Classification, epidemiology and therapies for testicular germ cell tumours. Int J Dev Biol 2013;57:133-139. Available at: https://www.ncbi.nlm.nih.gov/pubmed/23784823.

15. Amin MB, Edge SB, Greene F, et al., eds. AJCC Cancer Staging Manual, 8th ed. New York: Springer International Publishing; 2017.

16. Pierce JL, Frazier AL, Amatruda JF. Pediatric Germ Cell Tumors: A Developmental Perspective. Adv Urol 2018;2018:9059382. Available at: https://www.ncbi.nlm.nih.gov/pubmed/29515628.

17. Wagner T, Scandura G, Roe A, et al. Prospective molecular and morphological assessment of testicular prepubertal-type teratomas in postpubertal men. Mod Pathol 2020;33:713-721. Available at: https://www.ncbi.nlm.nih.gov/pubmed/31695156.

18. Kim W, Rosen MA, Langer JE, et al. US MR imaging correlation in pathologic conditions of the scrotum. Radiographics 2007;27:1239-1253. Available at: https://www.ncbi.nlm.nih.gov/pubmed/17848688.

19. Egan J, Cheaib JG, Biles MJ, et al. Testis-sparing Surgery: A Single Institution Experience. Urology 2021;147:192-198. Available at: https://www.ncbi.nlm.nih.gov/pubmed/33137349.

Discussion update in progress

Version 1.2026 © 2025 National Comprehensive Cancer Network© (NCCN©), All rights reserved. NCCN Guidelines® and this illustration may not be reproduced in any form without the express written permission of NCCN.

PLEASE NOTE that use of this NCCN Content is governed by the End-User License Agreement, and you MAY NOT distribute this Content or use it with any artificial intelligence model or tool.
Printed by Máximo López Chenlo on 5/4/2026 6:31:34 PM. Copyright © 2026 National Comprehensive Cancer Network, Inc. All Rights Reserved.

20. Nason GJ, Aditya I, Leao R, et al. Partial orchiectomy: The Princess Margaret cancer centre experience. Urol Oncol 2020;38:605 e619-605 e624. Available at: https://www.ncbi.nlm.nih.gov/pubmed/32284257.

21. Scandura G, Verrill C, Protheroe A, et al. Incidentally detected testicular lesions <10 mm in diameter: can orchidectomy be avoided? BJU Int 2018;121:575-582. Available at: https://www.ncbi.nlm.nih.gov/pubmed/29032579.

22. Nazeer T, Ro JY, Amato RJ, et al. Histologically pure seminoma with elevated alpha-fetoprotein: a clinicopathologic study of ten cases. Oncol Rep 1998;5:1425-1429. Available at: https://www.ncbi.nlm.nih.gov/pubmed/9769381.

23. Kundu SD, Carver BS, Sheinfeld J. Retroperitoneal histologic findings of patients with elevated serum alpha-fetoprotein and pure seminoma at orchiectomy. Urology 2011;78:844-847. Available at: https://www.ncbi.nlm.nih.gov/pubmed/21782217.

24. Gilligan TD, Seidenfeld J, Basch EM, et al. American Society of Clinical Oncology Clinical Practice Guideline on uses of serum tumor markers in adult males with germ cell tumors. J Clin Oncol 2010;28:3388-3404. Available at: https://www.ncbi.nlm.nih.gov/pubmed/20530278.

25. Salem M, Gilligan T. Serum tumor markers and their utilization in the management of germ-cell tumors in adult males. Expert Rev Anticancer Ther 2011;11:1-4. Available at: https://www.ncbi.nlm.nih.gov/pubmed/21166503.

26. Albany C, Einhorn L. Pitfalls in management of patients with germ cell tumors and slight elevation of serum alpha-fetoprotein. J Clin Oncol 2014;32:2114-2115. Available at: https://www.ncbi.nlm.nih.gov/pubmed/24841979.

27. Ferraro S, Trevisiol C, Gion M, Panteghini M. Human Chorionic Gonadotropin Assays for Testicular Tumors: Closing the Gap between Clinical and Laboratory Practice. Clin Chem 2018;64:270-278. Available at: https://www.ncbi.nlm.nih.gov/pubmed/29021329.

28. Lempiainen A, Hotakainen K, Blomqvist C, et al. Increased human chorionic gonadotropin due to hypogonadism after treatment of a testicular seminoma. Clin Chem 2007;53:1560-1561. Available at: https://www.ncbi.nlm.nih.gov/pubmed/17644799.

29. Morris MJ, Bosl GJ. Recognizing abnormal marker results that do not reflect disease in patients with germ cell tumors. J Urol 2000;163:796-801. Available at: https://www.ncbi.nlm.nih.gov/pubmed/10687980.

30. Michalski W, Poniatowska G, Jońska-Gmyrek J, et al. hCG-secreting malignancies — diagnostic pitfalls. Oncol Clin Pract 2019;15:331-335. Available at: https://journals.viamedica.pl/oncology_in_clinical_practice/article/view/65834.

31. Trojan A, Joller-Jemelka H, Stahel RA, et al. False-positive human serum chorionic gonadotropin in a patient with a history of germ cell cancer. Oncology 2004;66:336-338. Available at: https://www.ncbi.nlm.nih.gov/pubmed/15218303.

32. Ballieux BE, Weijl NI, Gelderblom H, et al. False-positive serum human chorionic gonadotropin (HCG) in a male patient with a malignant germ cell tumor of the testis: a case report and review of the literature. Oncologist 2008;13:1149-1154. Available at: https://www.ncbi.nlm.nih.gov/pubmed/18984875.

33. Soares DG, Millot F, Lacroix I, Lotz JP. Heterophile Antibody Interference led to Unneeded Chemotherapy in a Testicular Cancer Patient. Urol Case Rep 2016;9:1-3. Available at: https://www.ncbi.nlm.nih.gov/pubmed/27617210.

34. Beyer J, Collette L, Sauve N, et al. Survival and New Prognosticators in Metastatic Seminoma: Results From the IGCCCG-Update Consortium. J Clin Oncol 2021;39:1553-1562. Available at: https://www.ncbi.nlm.nih.gov/pubmed/33729863.

35. Jones RH, Vasey PA. Part I: testicular cancer--management of early disease. Lancet Oncol 2003;4:730-737. Available at: https://www.ncbi.nlm.nih.gov/pubmed/14662429.

36. Dieckmann KP, Anheuser P, Schmidt S, et al. Testicular prostheses in patients with testicular cancer - acceptance rate and patient satisfaction. BMC Urol 2015;15:16. Available at: https://www.ncbi.nlm.nih.gov/pubmed/25887552.

Discussion update in progress

Version 1.2026 © 2025 National Comprehensive Cancer Network© (NCCN©), All rights reserved. NCCN Guidelines® and this illustration may not be reproduced in any form without the express written permission of NCCN.

PLEASE NOTE that use of this NCCN Content is governed by the End-User License Agreement, and you MAY NOT distribute this Content or use it with any artificial intelligence model or tool.
Printed by Máximo López Chenlo on 5/4/2026 6:31:34 PM. Copyright © 2026 National Comprehensive Cancer Network, Inc. All Rights Reserved.

37. Robinson R, Tait CD, Clarke NW, Ramani VA. Is it safe to insert a testicular prosthesis at the time of radical orchidectomy for testis cancer: an audit of 904 men undergoing radical orchidectomy. BJU Int 2016;117:249-252. Available at: https://www.ncbi.nlm.nih.gov/pubmed/25168859.

38. Yossepowitch O, Aviv D, Wainchwaig L, Baniel J. Testicular prostheses for testis cancer survivors: patient perspectives and predictors of long-term satisfaction. J Urol 2011;186:2249-2252. Available at: https://www.ncbi.nlm.nih.gov/pubmed/22014806.

39. Fankhauser CD, Roth L, Kranzbuhler B, et al. The Role of Frozen Section Examination During Inguinal Exploration in Men with Inconclusive Testicular Tumors: A Systematic Review and Meta-analysis. Eur Urol Focus 2021;7:1400-1402. Available at: https://www.ncbi.nlm.nih.gov/pubmed/32684510.

40. Fossa SD, Chen J, Schonfeld SJ, et al. Risk of contralateral testicular cancer: a population-based study of 29,515 U.S. men. J Natl Cancer Inst 2005;97:1056-1066. Available at: https://www.ncbi.nlm.nih.gov/pubmed/16030303.

41. Ragni G, Somigliana E, Restelli L, et al. Sperm banking and rate of assisted reproduction treatment: insights from a 15-year cryopreservation program for male cancer patients. Cancer 2003;97:1624-1629. Available at: https://www.ncbi.nlm.nih.gov/pubmed/12655518.

42. Saito K, Suzuki K, Iwasaki A, et al. Sperm cryopreservation before cancer chemotherapy helps in the emotional battle against cancer. Cancer 2005;104:521-524. Available at: https://www.ncbi.nlm.nih.gov/pubmed/15968690.

43. Brydoy M, Fossa SD, Klepp O, et al. Paternity following treatment for testicular cancer. J Natl Cancer Inst 2005;97:1580-1588. Available at: https://www.ncbi.nlm.nih.gov/pubmed/16264178.

44. Huyghe E, Matsuda T, Daudin M, et al. Fertility after testicular cancer treatments: results of a large multicenter study. Cancer 2004;100:732-737. Available at: https://www.ncbi.nlm.nih.gov/pubmed/14770428.

45. Paner GP, Stadler WM, Hansel DE, et al. Updates in the Eighth Edition of the Tumor-Node-Metastasis Staging Classification for Urologic Cancers. Eur Urol 2018;73:560-569. Available at: https://www.ncbi.nlm.nih.gov/pubmed/29325693.

46. Yilmaz A, Cheng T, Zhang J, Trpkov K. Testicular hilum and vascular invasion predict advanced clinical stage in nonseminomatous germ cell tumors. Mod Pathol 2013;26:579-586. Available at: https://www.ncbi.nlm.nih.gov/pubmed/23238629.

47. Trevino KE, Esmaeili-Shandiz A, Saeed O, et al. Pathological risk factors for higher clinical stage in testicular seminomas. Histopathology 2018;73:741-747. Available at: https://www.ncbi.nlm.nih.gov/pubmed/29858564.

48. Tandstad T, Stahl O, Hakansson U, et al. One course of adjuvant BEP in clinical stage I nonseminoma mature and expanded results from the SWENOTECA group. Ann Oncol 2014;25:2167-2172. Available at: https://www.ncbi.nlm.nih.gov/pubmed/25114021.

49. Ernst DS, Brasher P, Venner PM, et al. Compliance and outcome of patients with stage 1 non-seminomatous germ cell tumors (NSGCT) managed with surveillance programs in seven Canadian centres. Can J Urol 2005;12:2575-2580. Available at: https://www.ncbi.nlm.nih.gov/pubmed/15877938.

50. Lago-Hernandez CA, Feldman H, O'Donnell E, et al. A refined risk stratification scheme for clinical stage 1 NSGCT based on evaluation of both embryonal predominance and lymphovascular invasion. Ann Oncol 2015;26:1396-1401. Available at: https://www.ncbi.nlm.nih.gov/pubmed/25888612.

51. Kobayashi K, Saito T, Kitamura Y, et al. Oncological outcomes in patients with stage I testicular seminoma and nonseminoma: pathological risk factors for relapse and feasibility of surveillance after orchiectomy. Diagn Pathol 2013;8:57. Available at: https://www.ncbi.nlm.nih.gov/pubmed/23566361.

52. Soper MS, Hastings JR, Cosmatos HA, et al. Observation versus adjuvant radiation or chemotherapy in the management of stage I seminoma: clinical outcomes and prognostic factors for relapse in a large US cohort. Am J Clin Oncol 2014;37:356-359. Available at: https://www.ncbi.nlm.nih.gov/pubmed/23275274.

Discussion update progress

Version 1.2026 © 2025 National Comprehensive Cancer Network© (NCCN©), All rights reserved. NCCN Guidelines® and this illustration may not be reproduced in any form without the express written permission of NCCN.

PLEASE NOTE that use of this NCCN Content is governed by the End-User License Agreement, and you MAY NOT distribute this Content or use it with any artificial intelligence model or tool.
Printed by Máximo López Chenlo on 5/4/2026 6:31:34 PM. Copyright © 2026 National Comprehensive Cancer Network, Inc. All Rights Reserved.

53. Sturgeon JF, Moore MJ, Kakiashvili DM, et al. Non-risk-adapted surveillance in clinical stage I nonseminomatous germ cell tumors: the Princess Margaret Hospital's experience. Eur Urol 2011;59:556-562. Available at: https://www.ncbi.nlm.nih.gov/pubmed/21190791.

54. Leman ES, Gonzalgo ML. Prognostic features and markers for testicular cancer management. Indian J Urol 2010;26:76-81. Available at: https://www.ncbi.nlm.nih.gov/pubmed/20535291.

55. Gordetsky J, Sanfrancesco J, Epstein JI, et al. Do Nonseminomatous Germ Cell Tumors of the Testis With Lymphovascular Invasion of the Spermatic Cord Merit Staging as pT3? Am J Surg Pathol 2017;41:1397-1402. Available at: https://www.ncbi.nlm.nih.gov/pubmed/28719463.

56. Nazeer T, Ro JY, Kee KH, Ayala AG. Spermatic cord contamination in testicular cancer. Mod Pathol 1996;9:762-766. Available at: https://www.ncbi.nlm.nih.gov/pubmed/8832559.

57. Blok JM, Pluim I, Daugaard G, et al. Lymphovascular invasion and presence of embryonal carcinoma as risk factors for occult metastatic disease in clinical stage I nonseminomatous germ cell tumour: a systematic review and meta-analysis. BJU Int 2020;125:355-368. Available at: https://www.ncbi.nlm.nih.gov/pubmed/31797520.

58. Divrik RT, Akdogan B, Ozen H, Zorlu F. Outcomes of surveillance protocol of clinical stage I nonseminomatous germ cell tumors-is shift to risk adapted policy justified? J Urol 2006;176:1424-1429; discussion 1429-1430. Available at: https://www.ncbi.nlm.nih.gov/pubmed/16952649.

59. Gilbert DC, Al-Saadi R, Thway K, et al. Defining a New Prognostic Index for Stage I Nonseminomatous Germ Cell Tumors Using CXCL12 Expression and Proportion of Embryonal Carcinoma. Clin Cancer Res 2016;22:1265-1273. Available at: https://www.ncbi.nlm.nih.gov/pubmed/26453693.

60. Vergouwe Y, Steyerberg EW, Eijkemans MJ, et al. Predictors of occult metastasis in clinical stage I nonseminoma: a systematic review. J Clin Oncol 2003;21:4092-4099. Available at: https://www.ncbi.nlm.nih.gov/pubmed/14559885.

61. Daugaard G, Gundgaard MG, Mortensen MS, et al. Surveillance for stage I nonseminoma testicular cancer: outcomes and long-term follow-up in a population-based cohort. J Clin Oncol 2014;32:3817-3823. Available at: https://www.ncbi.nlm.nih.gov/pubmed/25267754.

62. Heidenreich A, Sesterhenn IA, Mostofi FK, Moul JW. Prognostic risk factors that identify patients with clinical stage I nonseminomatous germ cell tumors at low risk and high risk for metastasis. Cancer 1998;83:1002-1011. Available at: https://www.ncbi.nlm.nih.gov/pubmed/9731905.

63. Alexandre J, Fizazi K, Mahe C, et al. Stage I non-seminomatous germ-cell tumours of the testis: identification of a subgroup of patients with a very low risk of relapse. Eur J Cancer 2001;37:576-582. Available at: https://www.ncbi.nlm.nih.gov/pubmed/11290432.

64. Sweeney CJ, Hermans BP, Heilman DK, et al. Results and outcome of retroperitoneal lymph node dissection for clinical stage I embryonal carcinoma--predominant testis cancer. J Clin Oncol 2000;18:358-362. Available at: https://www.ncbi.nlm.nih.gov/pubmed/10637250.

65. Albers P, Siener R, Kliesch S, et al. Risk factors for relapse in clinical stage I nonseminomatous testicular germ cell tumors: results of the German Testicular Cancer Study Group Trial. J Clin Oncol 2003;21:1505-1512. Available at: https://www.ncbi.nlm.nih.gov/pubmed/12697874.

66. Sanfrancesco JM, Trevino KE, Xu H, et al. The Significance of Spermatic Cord Involvement by Testicular Germ Cell Tumors: Should We Be Staging Discontinuous Invasion From Involved Lymphovascular Spaces Differently From Direct Extension? Am J Surg Pathol 2018;42:306-311. Available at: https://www.ncbi.nlm.nih.gov/pubmed/29309304.

67. Moch H, Cubilla AL, Humphrey PA, et al. The 2016 WHO Classification of Tumours of the Urinary System and Male Genital Organs-Part A: Renal, Penile, and Testicular Tumours. Eur Urol 2016;70:93-105. Available at: https://www.ncbi.nlm.nih.gov/pubmed/26935559.

68. Williamson SR, Delahunt B, Magi-Galluzzi C, et al. The World Health Organization 2016 classification of testicular germ cell tumours: a review and update from the International Society of Urological Pathology Testis Consultation Panel. Histopathology 2017;70:335-346. Available at: https://www.ncbi.nlm.nih.gov/pubmed/27747907.

Discussion Update in Progress

Version 1.2026 © 2025 National Comprehensive Cancer Network© (NCCN©), All rights reserved. NCCN Guidelines® and this illustration may not be reproduced in any form without the express written permission of NCCN.

PLEASE NOTE that use of this NCCN Content is governed by the End-User License Agreement, and you MAY NOT distribute this Content or use it with any artificial intelligence model or tool.
Printed by Máximo López Chenlo on 5/4/2026 6:31:34 PM. Copyright © 2026 National Comprehensive Cancer Network, Inc. All Rights Reserved.

69. International Germ Cell Consensus Classification: a prognostic factor-based staging system for metastatic germ cell cancers. International Germ Cell Cancer Collaborative Group. J Clin Oncol 1997;15:594-603. Available at: https://www.ncbi.nlm.nih.gov/pubmed/9053482.

70. Gillessen S, Sauve N, Collette L, et al. Predicting Outcomes in Men With Metastatic Nonseminomatous Germ Cell Tumors (NSGCT): Results From the IGCCCG Update Consortium. J Clin Oncol 2021;39:1563-1574. Available at: https://www.ncbi.nlm.nih.gov/pubmed/33822655.

71. Mead GM, Fossa SD, Oliver RT, et al. Randomized trials in 2466 patients with stage I seminoma: patterns of relapse and follow-up. J Natl Cancer Inst 2011;103:241-249. Available at: https://www.ncbi.nlm.nih.gov/pubmed/21212385.

72. Tandstad T, Stahl O, Dahl O, et al. Treatment of stage I seminoma, with one course of adjuvant carboplatin or surveillance, risk-adapted recommendations implementing patient autonomy: a report from the Swedish and Norwegian Testicular Cancer Group (SWENOTECA). Ann Oncol 2016;27:1299-1304. Available at: https://www.ncbi.nlm.nih.gov/pubmed/27052649.

73. Aparicio J, Garcia del Muro X, Maroto P, et al. Multicenter study evaluating a dual policy of postorchiectomy surveillance and selective adjuvant single-agent carboplatin for patients with clinical stage I seminoma. Ann Oncol 2003;14:867-872. Available at: https://www.ncbi.nlm.nih.gov/pubmed/12796024.

74. Warde P, Specht L, Horwich A, et al. Prognostic factors for relapse in stage I seminoma managed by surveillance: a pooled analysis. J Clin Oncol 2002;20:4448-4452. Available at: https://www.ncbi.nlm.nih.gov/pubmed/12431967.

75. Chung P, Parker C, Panzarella T, et al. Surveillance in stage I testicular seminoma - risk of late relapse. Can J Urol 2002;9:1637-1640. Available at: https://www.ncbi.nlm.nih.gov/pubmed/12431325.

76. Groll RJ, Warde P, Jewett MA. A comprehensive systematic review of testicular germ cell tumor surveillance. Crit Rev Oncol Hematol 2007;64:182-197. Available at: https://www.ncbi.nlm.nih.gov/pubmed/17644403.

77. Escudero-Avila R, Rodriguez-Castano JD, Osman I, et al. Active surveillance as a successful management strategy for patients with clinical stage I germ cell testicular cancer. Clin Transl Oncol 2019;21:796-804. Available at: https://www.ncbi.nlm.nih.gov/pubmed/30470992.

78. Zengerling F, Kunath F, Jensen K, et al. Prognostic factors for tumor recurrence in patients with clinical stage I seminoma undergoing surveillance-A systematic review. Urol Oncol 2018;36:448-458. Available at: https://www.ncbi.nlm.nih.gov/pubmed/28712790.

79. Aparicio J, Maroto P, Garcia Del Muro X, et al. Prognostic factors for relapse in stage I seminoma: a new nomogram derived from three consecutive, risk-adapted studies from the Spanish Germ Cell Cancer Group (SGCCG). Ann Oncol 2014;25:2173-2178. Available at: https://www.ncbi.nlm.nih.gov/pubmed/25210015.

80. Chung P, Daugaard G, Tyldesley S, et al. Evaluation of a prognostic model for risk of relapse in stage I seminoma surveillance. Cancer Med 2015;4:155-160. Available at: https://www.ncbi.nlm.nih.gov/pubmed/25236854.

81. Chung P, Warde P. Stage I seminoma: adjuvant treatment is effective but is it necessary? J Natl Cancer Inst 2011;103:194-196. Available at: https://www.ncbi.nlm.nih.gov/pubmed/21212383.

82. Mortensen MS, Lauritsen J, Gundgaard MG, et al. A nationwide cohort study of stage I seminoma patients followed on a surveillance program. Eur Urol 2014;66:1172-1178. Available at: https://www.ncbi.nlm.nih.gov/pubmed/25064686.

83. Boormans JL, Mayor de Castro J, Marconi L, et al. Testicular Tumour Size and Rete Testis Invasion as Prognostic Factors for the Risk of Relapse of Clinical Stage I Seminoma Testis Patients Under Surveillance: a Systematic Review by the Testicular Cancer Guidelines Panel. Eur Urol 2018;73:394-405. Available at: https://www.ncbi.nlm.nih.gov/pubmed/29100813.

84. Oliver RT, Mason MD, Mead GM, et al. Radiotherapy versus single-dose carboplatin in adjuvant treatment of stage I seminoma: a randomised trial. Lancet 2005;366:293-300. Available at: https://www.ncbi.nlm.nih.gov/pubmed/16039331.

Discussion update in progress

Version 1.2026 © 2025 National Comprehensive Cancer Network© (NCCN©), All rights reserved. NCCN Guidelines® and this illustration may not be reproduced in any form without the express written permission of NCCN.

PLEASE NOTE that use of this NCCN Content is governed by the End-User License Agreement, and you MAY NOT distribute this Content or use it with any artificial intelligence model or tool.
Printed by Máximo López Chenlo on 5/4/2026 6:31:34 PM. Copyright © 2026 National Comprehensive Cancer Network, Inc. All Rights Reserved.

85. Oliver RT, Mead GM, Rustin GJ, et al. Randomized trial of carboplatin versus radiotherapy for stage I seminoma: mature results on relapse and contralateral testis cancer rates in MRC TE19/EORTC 30982 study (ISRCTN27163214). J Clin Oncol 2011;29:957-962. Available at: https://www.ncbi.nlm.nih.gov/pubmed/21282539.

86. van de Wetering RAW, Sleijfer S, Feldman DR, et al. Controversies in the Management of Clinical Stage I Seminoma: Carboplatin a Decade in-Time to Start Backing Out. J Clin Oncol 2018;36:837-840. Available at: https://www.ncbi.nlm.nih.gov/pubmed/29389229.

87. Huddart RA, Norman A, Shahidi M, et al. Cardiovascular disease as a long-term complication of treatment for testicular cancer. J Clin Oncol 2003;21:1513-1523. Available at: https://www.ncbi.nlm.nih.gov/pubmed/12697875.

88. van den Belt-Dusebout AW, de Wit R, Gietema JA, et al. Treatment-specific risks of second malignancies and cardiovascular disease in 5-year survivors of testicular cancer. J Clin Oncol 2007;25:4370-4378. Available at: https://www.ncbi.nlm.nih.gov/pubmed/17906202.

89. Groot HJ, Lubberts S, de Wit R, et al. Risk of Solid Cancer After Treatment of Testicular Germ Cell Cancer in the Platinum Era. J Clin Oncol 2018;36:2504-2513. Available at: https://www.ncbi.nlm.nih.gov/pubmed/29989856.

90. Hellesnes R, Myklebust TA, Fossa SD, et al. Testicular Cancer in the Cisplatin Era: Causes of Death and Mortality Rates in a Population-Based Cohort. J Clin Oncol 2021;39:3561-3573. Available at: https://www.ncbi.nlm.nih.gov/pubmed/34388002.

91. Aparicio J, Garcia Del Muro X, Maroto P, et al. Patterns of relapse and treatment outcome after active surveillance or adjuvant carboplatin for stage I seminoma: a retrospective study of the Spanish Germ Cell Cancer Group. Clin Transl Oncol 2021;23:58-64. Available at: https://www.ncbi.nlm.nih.gov/pubmed/32462393.

92. Aparicio J, Germa JR, Garcia del Muro X, et al. Risk-adapted management for patients with clinical stage I seminoma: the Second Spanish Germ Cell Cancer Cooperative Group study. J Clin Oncol 2005;23:8717-8723. Available at: https://www.ncbi.nlm.nih.gov/pubmed/16260698.

93. Aparicio J, Maroto P, del Muro XG, et al. Risk-adapted treatment in clinical stage I testicular seminoma: the third Spanish Germ Cell Cancer Group study. J Clin Oncol 2011;29:4677-4681. Available at: https://www.ncbi.nlm.nih.gov/pubmed/22042940.

94. Koutsoukos K, Tzannis K, Christodoulou C, et al. Two cycles of adjuvant carboplatin in stage I seminoma: 8-year experience by the Hellenic Cooperative Oncology Group (HECOG). World J Urol 2016;34:853-857. Available at: https://www.ncbi.nlm.nih.gov/pubmed/26410826.

95. Dieckmann KP, Dralle-Filiz I, Matthies C, et al. Testicular seminoma clinical stage 1: treatment outcome on a routine care level. J Cancer Res Clin Oncol 2016;142:1599-1607. Available at: https://www.ncbi.nlm.nih.gov/pubmed/27116691.

96. Travis LB, Curtis RE, Storm H, et al. Risk of second malignant neoplasms among long-term survivors of testicular cancer. J Natl Cancer Inst 1997;89:1429-1439. Available at: https://www.ncbi.nlm.nih.gov/pubmed/9326912.

97. Travis LB, Fossa SD, Schonfeld SJ, et al. Second cancers among 40,576 testicular cancer patients: focus on long-term survivors. J Natl Cancer Inst 2005;97:1354-1365. Available at: https://www.ncbi.nlm.nih.gov/pubmed/16174857.

98. Beard CJ, Travis LB, Chen MH, et al. Outcomes in stage I testicular seminoma: a population-based study of 9193 patients. Cancer 2013;119:2771-2777. Available at: https://www.ncbi.nlm.nih.gov/pubmed/23633409.

99. Horwich A, Fossa SD, Huddart R, et al. Second cancer risk and mortality in men treated with radiotherapy for stage I seminoma. Br J Cancer 2014;110:256-263. Available at: https://www.ncbi.nlm.nih.gov/pubmed/24263066.

100. McMahon CJ, Rofsky NM, Pedrosa I. Lymphatic metastases from pelvic tumors: anatomic classification, characterization, and staging. Radiology 2010;254:31-46. Available at: https://www.ncbi.nlm.nih.gov/pubmed/20032141.

Discussion update in progress

Version 1.2026 © 2025 National Comprehensive Cancer Network© (NCCN©), All rights reserved. NCCN Guidelines® and this illustration may not be reproduced in any form without the express written permission of NCCN.

PLEASE NOTE that use of this NCCN Content is governed by the End-User License Agreement, and you MAY NOT distribute this Content or use it with any artificial intelligence model or tool.
Printed by Máximo López Chenlo on 5/4/2026 6:31:34 PM. Copyright © 2026 National Comprehensive Cancer Network, Inc. All Rights Reserved.

101. Dinniwell R, Chan P, Czarnota G, et al. Pelvic lymph node topography for radiotherapy treatment planning from ferumoxtran-10 contrast-enhanced magnetic resonance imaging. Int J Radiat Oncol Biol Phys 2009;74:844-851. Available at: https://www.ncbi.nlm.nih.gov/pubmed/19095369.

102. Jones WG, Fossa SD, Mead GM, et al. Randomized trial of 30 versus 20 Gy in the adjuvant treatment of stage I Testicular Seminoma: a report on Medical Research Council Trial TE18, European Organisation for the Research and Treatment of Cancer Trial 30942 (ISRCTN18525328). J Clin Oncol 2005;23:1200-1208. Available at: https://www.ncbi.nlm.nih.gov/pubmed/15718317.

103. Fossa SD, Horwich A, Russell JM, et al. Optimal planning target volume for stage I testicular seminoma: A Medical Research Council randomized trial. Medical Research Council Testicular Tumor Working Group. J Clin Oncol 1999;17:1146. Available at: https://www.ncbi.nlm.nih.gov/pubmed/10561173.

104. Livsey JE, Taylor B, Mobarek N, et al. Patterns of relapse following radiotherapy for stage I seminoma of the testis: implications for follow-up. Clin Oncol (R Coll Radiol) 2001;13:296-300. Available at: https://www.ncbi.nlm.nih.gov/pubmed/11554630.

105. Martin JM, Panzarella T, Zwahlen DR, et al. Evidence-based guidelines for following stage 1 seminoma. Cancer 2007;109:2248-2256. Available at: https://www.ncbi.nlm.nih.gov/pubmed/17437287.

106. van As NJ, Gilbert DC, Money-Kyrle J, et al. Evidence-based pragmatic guidelines for the follow-up of testicular cancer: optimising the detection of relapse. Br J Cancer 2008;98:1894-1902. Available at: https://www.ncbi.nlm.nih.gov/pubmed/18542063.

107. Garmezy B, Pagliaro LC. Choosing treatment for stage I seminoma: who should get what? Oncology (Williston Park) 2009;23:753, 759. Available at: https://www.ncbi.nlm.nih.gov/pubmed/19777759.

108. Choo R, Sandler H, Warde P, et al. Survey of radiation oncologists: practice patterns of the management of stage I seminoma of testis in Canada and a selected group in the United States. Can J Urol 2002;9:1479-1485. Available at: https://www.ncbi.nlm.nih.gov/pubmed/12010592.

109. Mortensen MS, Bandak M, Kier MG, et al. Surveillance versus adjuvant radiotherapy for patients with high-risk stage I seminoma. Cancer 2017;123:1212-1218. Available at: https://www.ncbi.nlm.nih.gov/pubmed/27893934.

110. Glaser SM, Vargo JA, Balasubramani GK, Beriwal S. Surveillance and Radiation Therapy for Stage I Seminoma--Have We Learned From the Evidence? Int J Radiat Oncol Biol Phys 2016;94:75-84. Available at: https://www.ncbi.nlm.nih.gov/pubmed/26700704.

111. Vesprini D, Chung P, Tolan S, et al. Utility of serum tumor markers during surveillance for stage I seminoma. Cancer 2012;118:5245-5250. Available at: https://www.ncbi.nlm.nih.gov/pubmed/22517478.

112. Joffe JK, Cafferty FH, Murphy L, et al. Imaging Modality and Frequency in Surveillance of Stage I Seminoma Testicular Cancer: Results From a Randomized, Phase III, Noninferiority Trial (TRISST). J Clin Oncol 2022;40:2468-2478. Available at: https://www.ncbi.nlm.nih.gov/pubmed/35298280.

113. Tolan S, Vesprini D, Jewett MA, et al. No role for routine chest radiography in stage I seminoma surveillance. Eur Urol 2010;57:474-479. Available at: https://www.ncbi.nlm.nih.gov/pubmed/19577354.

114. De La Pena H, Sharma A, Glicksman C, et al. No longer any role for routine follow-up chest x-rays in men with stage I germ cell cancer. Eur J Cancer 2017;84:354-359. Available at: https://www.ncbi.nlm.nih.gov/pubmed/28866371.

115. Kollmannsberger C, Tandstad T, Bedard PL, et al. Patterns of relapse in patients with clinical stage I testicular cancer managed with active surveillance. J Clin Oncol 2015;33:51-57. Available at: https://www.ncbi.nlm.nih.gov/pubmed/25135991.

116. Classen J, Schmidberger H, Meisner C, et al. Radiotherapy for stages IIA/B testicular seminoma: final report of a prospective multicenter clinical trial. J Clin Oncol 2003;21:1101-1106. Available at: https://www.ncbi.nlm.nih.gov/pubmed/12637477.

117. Patterson H, Norman AR, Mitra SS, et al. Combination carboplatin and radiotherapy in the management of stage II testicular seminoma: comparison with radiotherapy treatment alone. Radiother Oncol

Discussion Update in Progress

Version 1.2026 © 2025 National Comprehensive Cancer Network© (NCCN©), All rights reserved. NCCN Guidelines® and this illustration may not be reproduced in any form without the express written permission of NCCN.

PLEASE NOTE that use of this NCCN Content is governed by the End-User License Agreement, and you MAY NOT distribute this Content or use it with any artificial intelligence model or tool.
Printed by Máximo López Chenlo on 5/4/2026 6:31:34 PM. Copyright © 2026 National Comprehensive Cancer Network, Inc. All Rights Reserved.

2001;59:5-11. Available at: https://www.ncbi.nlm.nih.gov/pubmed/11295200.

118. Detti B, Livi L, Scoccianti S, et al. Management of Stage II testicular seminoma over a period of 40 years. Urol Oncol 2009;27:534-538. Available at: https://www.ncbi.nlm.nih.gov/pubmed/18848787.

119. Glaser SM, Vargo JA, Balasubramani GK, Beriwal S. Stage II Testicular Seminoma: Patterns of Care and Survival by Treatment Strategy. Clin Oncol (R Coll Radiol) 2016;28:513-521. Available at: https://www.ncbi.nlm.nih.gov/pubmed/27146264.

120. Paly JJ, Lin CC, Gray PJ, et al. Management and outcomes of clinical stage IIA/B seminoma: Results from the National Cancer Data Base 1998-2012. Pract Radiat Oncol 2016;6:e249-e258. Available at: https://www.ncbi.nlm.nih.gov/pubmed/27345128.

121. Gospodarwicz MK, Sturgeon JF, Jewett MA. Early stage and advanced seminoma: role of radiation therapy, surgery, and chemotherapy. Semin Oncol 1998;25:160-173. Available at: https://www.ncbi.nlm.nih.gov/pubmed/9562449.

122. Tachibana I, Alabd A, Tong Y, et al. Primary Retroperitoneal Lymph Node Dissection for Stage II Seminoma: Is Surgery the New Path Forward? J Clin Oncol 2023;41:3930-3938. Available at: https://www.ncbi.nlm.nih.gov/pubmed/36730902.

123. Daneshmand S, Cary C, Masterson T, et al. Surgery in Early Metastatic Seminoma: A Phase II Trial of Retroperitoneal Lymph Node Dissection for Testicular Seminoma With Limited Retroperitoneal Lymphadenopathy. J Clin Oncol 2023;41:3009-3018. Available at: https://www.ncbi.nlm.nih.gov/pubmed/36913642.

124. Heidenreich A, Paffenholz P, Hartmann F, et al. Retroperitoneal Lymph Node Dissection in Clinical Stage IIA/B Metastatic Seminoma: Results of the COlogne Trial of Retroperitoneal Lymphadenectomy In Metastatic Seminoma (COTRIMS). Eur Urol Oncol 2024;7:122-127. Available at: https://www.ncbi.nlm.nih.gov/pubmed/37438222.

125. Hiester A, Che Y, Lusch A, et al. Phase 2 Single-arm Trial of Primary Retroperitoneal Lymph Node Dissection in Patients with Seminomatous Testicular Germ Cell Tumors with Clinical Stage IIA/B (PRIMETEST). Eur Urol 2023;84:25-31. Available at: https://www.ncbi.nlm.nih.gov/pubmed/36372627.

126. Papachristofilou A, Bedke J, Hayoz S, et al. Single-dose carboplatin followed by involved-node radiotherapy for stage IIA and stage IIB seminoma (SAKK 01/10): a single-arm, multicentre, phase 2 trial. Lancet Oncol 2022;23:1441-1450. Available at: https://www.ncbi.nlm.nih.gov/pubmed/36228644.

127. de Wit R, Roberts JT, Wilkinson PM, et al. Equivalence of three or four cycles of bleomycin, etoposide, and cisplatin chemotherapy and of a 3- or 5-day schedule in good-prognosis germ cell cancer: a randomized study of the European Organization for Research and Treatment of Cancer Genitourinary Tract Cancer Cooperative Group and the Medical Research Council. J Clin Oncol 2001;19:1629-1640. Available at: https://www.ncbi.nlm.nih.gov/pubmed/11250991.

128. Kondagunta GV, Bacik J, Bajorin D, et al. Etoposide and cisplatin chemotherapy for metastatic good-risk germ cell tumors. J Clin Oncol 2005;23:9290-9294. Available at: https://www.ncbi.nlm.nih.gov/pubmed/16361627.

129. Cary C, Jacob JM, Albany C, et al. Long-Term Survival of Good-Risk Germ Cell Tumor Patients After Postchemotherapy Retroperitoneal Lymph Node Dissection: A Comparison of BEP x 3 vs. EP x 4 and Treating Institution. Clin Genitourin Cancer 2018;16:e307-e313. Available at: https://www.ncbi.nlm.nih.gov/pubmed/29104087.

130. Kawai K, Akaza H. Current status of chemotherapy in risk-adapted management for metastatic testicular germ cell cancer. Cancer Sci 2010;101:22-28. Available at: https://www.ncbi.nlm.nih.gov/pubmed/19922501.

131. Calabro F, Albers P, Bokemeyer C, et al. The contemporary role of chemotherapy for advanced testis cancer: a systematic review of the literature. Eur Urol 2012;61:1212-1221. Available at: https://www.ncbi.nlm.nih.gov/pubmed/22464311.

132. Feldman DR, Bosl GJ, Sheinfeld J, Motzer RJ. Medical treatment of advanced testicular cancer. JAMA 2008;299:672-684. Available at: https://www.ncbi.nlm.nih.gov/pubmed/18270356.

Discussion update in progress

Version 1.2026 © 2025 National Comprehensive Cancer Network© (NCCN©), All rights reserved. NCCN Guidelines® and this illustration may not be reproduced in any form without the express written permission of NCCN.

PLEASE NOTE that use of this NCCN Content is governed by the End-User License Agreement, and you MAY NOT distribute this Content or use it with any artificial intelligence model or tool.
Printed by Máximo López Chenlo on 5/4/2026 6:31:34 PM. Copyright © 2026 National Comprehensive Cancer Network, Inc. All Rights Reserved.

133. Fizazi K, Delva R, Caty A, et al. A risk-adapted study of cisplatin and etoposide, with or without ifosfamide, in patients with metastatic seminoma: results of the GETUG S99 multicenter prospective study. Eur Urol 2014;65:381-386. Available at: https://www.ncbi.nlm.nih.gov/pubmed/24094847.

134. Yoshida T, Yonese J, Kitsukawa S, et al. [Treatment results of VIP (etoposide, ifosfamide and cisplatin) chemotherapy as a first-line therapy in metastatic germ cell tumors]. Nihon Hinyokika Gakkai Zasshi 2000;91:55-61. Available at: https://www.ncbi.nlm.nih.gov/pubmed/10723177.

135. Ishioka J, Kageyama Y, Inoue M, et al. [Result of treatment for advanced germ cell tumor in the last decade]. Nihon Hinyokika Gakkai Zasshi 2010;101:539-546. Available at: https://www.ncbi.nlm.nih.gov/pubmed/20387513.

136. Spermon JR, De Geus-Oei LF, Kiemeney LA, et al. The role of (18)fluoro-2-deoxyglucose positron emission tomography in initial staging and re-staging after chemotherapy for testicular germ cell tumours. BJU Int 2002;89:549-556. Available at: https://www.ncbi.nlm.nih.gov/pubmed/11942962.

137. De Santis M, Pont J. The role of positron emission tomography in germ cell cancer. World J Urol 2004;22:41-46. Available at: https://www.ncbi.nlm.nih.gov/pubmed/15024601.

138. De Santis M, Becherer A, Bokemeyer C, et al. 2-18fluoro-deoxy-D-glucose positron emission tomography is a reliable predictor for viable tumor in postchemotherapy seminoma: an update of the prospective multicentric SEMPET trial. J Clin Oncol 2004;22:1034-1039. Available at: https://www.ncbi.nlm.nih.gov/pubmed/15020605.

139. Becherer A, De Santis M, Karanikas G, et al. FDG PET is superior to CT in the prediction of viable tumour in post-chemotherapy seminoma residuals. Eur J Radiol 2005;54:284-288. Available at: https://www.ncbi.nlm.nih.gov/pubmed/15837411.

140. Treglia G, Sadeghi R, Annunziata S, et al. Diagnostic performance of fluorine-18-fluorodeoxyglucose positron emission tomography in the postchemotherapy management of patients with seminoma: systematic review and meta-analysis. Biomed Res Int 2014;2014:852681. Available at: https://www.ncbi.nlm.nih.gov/pubmed/24963486.

141. Becherer A. PET in testicular cancer. Methods Mol Biol 2011;727:225-241. Available at: https://www.ncbi.nlm.nih.gov/pubmed/21331937.

142. Cathomas R, Klingbiel D, Bernard B, et al. Questioning the Value of Fluorodeoxyglucose Positron Emission Tomography for Residual Lesions After Chemotherapy for Metastatic Seminoma: Results of an International Global Germ Cell Cancer Group Registry. J Clin Oncol 2018:JCO1800210. Available at: https://www.ncbi.nlm.nih.gov/pubmed/30285559.

143. Hinz S, Schrader M, Kempkensteffen C, et al. The role of positron emission tomography in the evaluation of residual masses after chemotherapy for advanced stage seminoma. J Urol 2008;179:936-940; discussion 940. Available at: https://www.ncbi.nlm.nih.gov/pubmed/18207171.

144. Kondagunta GV, Bacik J, Donadio A, et al. Combination of paclitaxel, ifosfamide, and cisplatin is an effective second-line therapy for patients with relapsed testicular germ cell tumors. J Clin Oncol 2005;23:6549-6555. Available at: https://www.ncbi.nlm.nih.gov/pubmed/16170162.

145. Loehrer PJ, Sr., Lauer R, Roth BJ, et al. Salvage therapy in recurrent germ cell cancer: ifosfamide and cisplatin plus either vinblastine or etoposide. Ann Intern Med 1988;109:540-546. Available at: https://www.ncbi.nlm.nih.gov/pubmed/2844110.

146. Miller KD, Loehrer PJ, Gonin R, Einhorn LH. Salvage chemotherapy with vinblastine, ifosfamide, and cisplatin in recurrent seminoma. J Clin Oncol 1997;15:1427-1431. Available at: https://www.ncbi.nlm.nih.gov/pubmed/9193335.

147. Kondagunta GV, Bacik J, Sheinfeld J, et al. Paclitaxel plus Ifosfamide followed by high-dose carboplatin plus etoposide in previously treated germ cell tumors. J Clin Oncol 2007;25:85-90. Available at: https://www.ncbi.nlm.nih.gov/pubmed/17194908.

148. Flechon A, Bompas E, Biron P, Droz JP. Management of post-chemotherapy residual masses in advanced seminoma. J Urol

Discussion update in progress

Version 1.2026 © 2025 National Comprehensive Cancer Network© (NCCN©), All rights reserved. NCCN Guidelines® and this illustration may not be reproduced in any form without the express written permission of NCCN.

PLEASE NOTE that use of this NCCN Content is governed by the End-User License Agreement, and you MAY NOT distribute this Content or use it with any artificial intelligence model or tool.
Printed by Máximo López Chenlo on 5/4/2026 6:31:34 PM. Copyright © 2026 National Comprehensive Cancer Network, Inc. All Rights Reserved.

2002;168:1975-1979. Available at: https://www.ncbi.nlm.nih.gov/pubmed/12394688.

149. de Wit M, Brenner W, Hartmann M, et al. [18F]-FDG-PET in clinical stage I/II non-seminomatous germ cell tumours: results of the German multicentre trial. Ann Oncol 2008;19:1619-1623. Available at: https://www.ncbi.nlm.nih.gov/pubmed/18453520.

150. Huddart RA, O'Doherty MJ, Padhani A, et al. 18fluorodeoxyglucose positron emission tomography in the prediction of relapse in patients with high-risk, clinical stage I nonseminomatous germ cell tumors: preliminary report of MRC Trial TE22--the NCRI Testis Tumour Clinical Study Group. J Clin Oncol 2007;25:3090-3095. Available at: https://www.ncbi.nlm.nih.gov/pubmed/17634488.

151. Ranganath P, Kesler KA, Einhorn LH. Perioperative Morbidity and Mortality Associated With Bleomycin in Primary Mediastinal Nonseminomatous Germ Cell Tumor. J Clin Oncol 2016;34:4445-4446. Available at: https://www.ncbi.nlm.nih.gov/pubmed/27621392.

152. Zuniga A, Kakiashvili D, Jewett MA. Surveillance in stage I nonseminomatous germ cell tumours of the testis. BJU Int 2009;104:1351-1356. Available at: https://www.ncbi.nlm.nih.gov/pubmed/19840012.

153. Oliver RT, Ong J, Shamash J, et al. Long-term follow-up of Anglian Germ Cell Cancer Group surveillance versus patients with Stage 1 nonseminoma treated with adjuvant chemotherapy. Urology 2004;63:556-561. Available at: https://www.ncbi.nlm.nih.gov/pubmed/15028457.

154. Stephenson AJ, Bosl GJ, Bajorin DF, et al. Retroperitoneal lymph node dissection in patients with low stage testicular cancer with embryonal carcinoma predominance and/or lymphovascular invasion. J Urol 2005;174:557-560; discussion 560. Available at: https://www.ncbi.nlm.nih.gov/pubmed/16006891.

155. Albers P, Siener R, Krege S, et al. Randomized phase III trial comparing retroperitoneal lymph node dissection with one course of bleomycin and etoposide plus cisplatin chemotherapy in the adjuvant treatment of clinical stage I Nonseminomatous testicular germ cell tumors: AUO trial AH 01/94 by the German Testicular Cancer Study Group. J Clin Oncol 2008;26:2966-2972. Available at: https://www.ncbi.nlm.nih.gov/pubmed/18458040.

156. Tandstad T, Dahl O, Cohn-Cedermark G, et al. Risk-adapted treatment in clinical stage I nonseminomatous germ cell testicular cancer: the SWENOTECA management program. J Clin Oncol 2009;27:2122-2128. Available at: https://www.ncbi.nlm.nih.gov/pubmed/19307506.

157. Stephenson AJ, Bosl GJ, Motzer RJ, et al. Retroperitoneal lymph node dissection for nonseminomatous germ cell testicular cancer: impact of patient selection factors on outcome. J Clin Oncol 2005;23:2781-2788. Available at: https://www.ncbi.nlm.nih.gov/pubmed/15837993.

158. Calaway AC, Einhorn LH, Masterson TA, et al. Adverse Surgical Outcomes Associated with Robotic Retroperitoneal Lymph Node Dissection Among Patients with Testicular Cancer. Eur Urol 2019;76:607-609. Available at: https://www.ncbi.nlm.nih.gov/pubmed/31174891.

159. Taylor J, Becher E, Wysock JS, et al. Primary Robot-assisted Retroperitoneal Lymph Node Dissection for Men with Nonseminomatous Germ Cell Tumor: Experience from a Multi-institutional Cohort. Eur Urol Focus 2021;7:1403-1408. Available at: https://www.ncbi.nlm.nih.gov/pubmed/32682794.

160. Abdul-Muhsin H, Rocco N, Navaratnam A, et al. Outcomes of post-chemotherapy robot-assisted retroperitoneal lymph node dissection in testicular cancer: multi-institutional study. World J Urol 2021;39:3833-3838. Available at: https://www.ncbi.nlm.nih.gov/pubmed/33959785.

161. Bamias A, Aravantinos G, Kastriotis I, et al. Report of the long-term efficacy of two cycles of adjuvant bleomycin/etoposide/cisplatin in patients with stage I testicular nonseminomatous germ-cell tumors (NSGCT): a risk adapted protocol of the Hellenic Cooperative Oncology Group. Urol Oncol 2011;29:189-193. Available at: https://www.ncbi.nlm.nih.gov/pubmed/19362863.

162. Guney S, Guney N, Sonmez NC, Ergenekon E. Risk-adapted management for patients with clinical stage I non-seminomatous germ cell tumour of the testis. Med Oncol 2009;26:136-142. Available at: https://www.ncbi.nlm.nih.gov/pubmed/18821067.

163. Chovanec M, Hanna N, Cary KC, et al. Management of stage I testicular germ cell tumours. Nat Rev Urol 2016;13:663-673. Available at: https://www.ncbi.nlm.nih.gov/pubmed/27618772.

Discussion update in progress

Version 1.2026 © 2025 National Comprehensive Cancer Network© (NCCN©), All rights reserved. NCCN Guidelines® and this illustration may not be reproduced in any form without the express written permission of NCCN.

PLEASE NOTE that use of this NCCN Content is governed by the End-User License Agreement, and you MAY NOT distribute this Content or use it with any artificial intelligence model or tool.
Printed by Máximo López Chenlo on 5/4/2026 6:31:34 PM. Copyright © 2026 National Comprehensive Cancer Network, Inc. All Rights Reserved.

164. Huddart RA, Reid AM. Adjuvant Therapy for Stage IB Germ Cell Tumors: One versus Two Cycles of BEP. Adv Urol 2018;2018:8781698. Available at: https://www.ncbi.nlm.nih.gov/pubmed/29808086.

165. Chevreau C, Mazerolles C, Soulie M, et al. Long-term efficacy of two cycles of BEP regimen in high-risk stage I nonseminomatous testicular germ cell tumors with embryonal carcinoma and/or vascular invasion. Eur Urol 2004;46:209-214; discussion 214-205. Available at: https://www.ncbi.nlm.nih.gov/pubmed/15245815.

166. Meinardi MT, Gietema JA, van der Graaf WT, et al. Cardiovascular morbidity in long-term survivors of metastatic testicular cancer. J Clin Oncol 2000;18:1725-1732. Available at: https://www.ncbi.nlm.nih.gov/pubmed/10764433.

167. Chovanec M, Abu Zaid M, Hanna N, et al. Long-term toxicity of cisplatin in germ-cell tumor survivors. Ann Oncol 2017;28:2670-2679. Available at: https://www.ncbi.nlm.nih.gov/pubmed/29045502.

168. Strumberg D, Brugge S, Korn MW, et al. Evaluation of long-term toxicity in patients after cisplatin-based chemotherapy for non-seminomatous testicular cancer. Ann Oncol 2002;13:229-236. Available at: https://www.ncbi.nlm.nih.gov/pubmed/11885999.

169. Fung C, Dinh P, Jr., Ardeshir-Rouhani-Fard S, et al. Toxicities Associated with Cisplatin-Based Chemotherapy and Radiotherapy in Long-Term Testicular Cancer Survivors. Adv Urol 2018;2018:8671832. Available at: https://www.ncbi.nlm.nih.gov/pubmed/29670654.

170. Hartmann JT, Lipp HP. Toxicity of platinum compounds. Expert Opin Pharmacother 2003;4:889-901. Available at: https://www.ncbi.nlm.nih.gov/pubmed/12783586.

171. Kerns SL, Fung C, Monahan PO, et al. Cumulative Burden of Morbidity Among Testicular Cancer Survivors After Standard Cisplatin-Based Chemotherapy: A Multi-Institutional Study. J Clin Oncol 2018;36:1505-1512. Available at: https://www.ncbi.nlm.nih.gov/pubmed/29617189.

172. Sprauten M, Darrah TH, Peterson DR, et al. Impact of long-term serum platinum concentrations on neuro- and ototoxicity in Cisplatin-treated survivors of testicular cancer. J Clin Oncol 2012;30:300-307. Available at: https://www.ncbi.nlm.nih.gov/pubmed/22184390.

173. Haugnes HS, Stenklev NC, Brydoy M, et al. Hearing loss before and after cisplatin-based chemotherapy in testicular cancer survivors: a longitudinal study. Acta Oncol 2018;57:1075-1083. Available at: https://www.ncbi.nlm.nih.gov/pubmed/29384420.

174. Raphael MJ, Wei X, Karim S, et al. Neurotoxicity Among Survivors of Testicular Cancer: A Population-based Study. Clin Oncol (R Coll Radiol) 2019;31:653-658. Available at: https://www.ncbi.nlm.nih.gov/pubmed/31056287.

175. Gietema JA, Meinardi MT, Sleijfer DT, et al. Routine chest X-rays have no additional value in the detection of relapse during routine follow-up of patients treated with chemotherapy for disseminated non-seminomatous testicular cancer. Ann Oncol 2002;13:1616-1620. Available at: https://www.ncbi.nlm.nih.gov/pubmed/12377651.

176. Lv ZJ, Wu S, Dong P, et al. Clinical outcomes in patients with stage I non-seminomatous germ cell cancer. Asian J Androl 2013;15:558-563. Available at: https://www.ncbi.nlm.nih.gov/pubmed/23685909.

177. Mezvrishvili Z, Managadze L. Three cycles of etoposide and cisplatin chemotherapy in clinical stage IS nonseminomatous testicular cancer. Int Urol Nephrol 2006;38:621-624. Available at: https://www.ncbi.nlm.nih.gov/pubmed/17111082.

178. Stephenson AJ, Bosl GJ, Motzer RJ, et al. Nonrandomized comparison of primary chemotherapy and retroperitoneal lymph node dissection for clinical stage IIA and IIB nonseminomatous germ cell testicular cancer. J Clin Oncol 2007;25:5597-5602. Available at: https://www.ncbi.nlm.nih.gov/pubmed/18065732.

179. Weissbach L, Bussar-Maatz R, Flechtner H, et al. RPLND or primary chemotherapy in clinical stage IIA/B nonseminomatous germ cell tumors? Results of a prospective multicenter trial including quality of life assessment. Eur Urol 2000;37:582-594. Available at: https://www.ncbi.nlm.nih.gov/pubmed/10765098.

180. Rabbani F, Sheinfeld J, Farivar-Mohseni H, et al. Low-volume nodal metastases detected at retroperitoneal lymphadenectomy for testicular

Discussion update in progress

Version 1.2026 © 2025 National Comprehensive Cancer Network© (NCCN©), All rights reserved. NCCN Guidelines® and this illustration may not be reproduced in any form without the express written permission of NCCN.

PLEASE NOTE that use of this NCCN Content is governed by the End-User License Agreement, and you MAY NOT distribute this Content or use it with any artificial intelligence model or tool.
Printed by Máximo López Chenlo on 5/4/2026 6:31:34 PM. Copyright © 2026 National Comprehensive Cancer Network, Inc. All Rights Reserved.

cancer: pattern and prognostic factors for relapse. J Clin Oncol 2001;19:2020-2025. Available at: https://www.ncbi.nlm.nih.gov/pubmed/11283135.

181. Kondagunta GV, Sheinfeld J, Mazumdar M, et al. Relapse-free and overall survival in patients with pathologic stage II nonseminomatous germ cell cancer treated with etoposide and cisplatin adjuvant chemotherapy. J Clin Oncol 2004;22:464-467. Available at: https://www.ncbi.nlm.nih.gov/pubmed/14752068.

182. Horwich A, Norman A, Fisher C, et al. Primary chemotherapy for stage II nonseminomatous germ cell tumors of the testis. J Urol 1994;151:72-77; discussion 77-78. Available at: https://www.ncbi.nlm.nih.gov/pubmed/8254836.

183. Behnia M, Foster R, Einhorn LH, et al. Adjuvant bleomycin, etoposide and cisplatin in pathological stage II non-seminomatous testicular cancer. the Indiana University experience. Eur J Cancer 2000;36:472-475. Available at: https://www.ncbi.nlm.nih.gov/pubmed/10717522.

184. Stephenson AJ, Klein EA. Surgical management of low-stage nonseminomatous germ cell testicular cancer. BJU Int 2009;104:1362-1368. Available at: https://www.ncbi.nlm.nih.gov/pubmed/19840014.

185. Donohue JP, Thornhill JA, Foster RS, et al. The role of retroperitoneal lymphadenectomy in clinical stage B testis cancer: the Indiana University experience (1965 to 1989). J Urol 1995;153:85-89. Available at: https://www.ncbi.nlm.nih.gov/pubmed/7966799.

186. Sheinfeld J, Motzer RJ, Rabbani F, et al. Incidence and clinical outcome of patients with teratoma in the retroperitoneum following primary retroperitoneal lymph node dissection for clinical stages I and IIA nonseminomatous germ cell tumors. J Urol 2003;170:1159-1162. Available at: https://www.ncbi.nlm.nih.gov/pubmed/14501715.

187. McHugh DJ, Funt SA, Silber D, et al. Adjuvant Chemotherapy With Etoposide Plus Cisplatin for Patients With Pathologic Stage II Nonseminomatous Germ Cell Tumors. J Clin Oncol 2020;38:1332-1337. Available at: https://www.ncbi.nlm.nih.gov/pubmed/32109195.

188. Carver BS, Shayegan B, Eggener S, et al. Incidence of metastatic nonseminomatous germ cell tumor outside the boundaries of a modified postchemotherapy retroperitoneal lymph node dissection. J Clin Oncol 2007;25:4365-4369. Available at: https://www.ncbi.nlm.nih.gov/pubmed/17906201.

189. Nonomura N, Nishimura K, Takaha N, et al. Nerve-sparing retroperitoneal lymph node dissection for advanced testicular cancer after chemotherapy. Int J Urol 2002;9:539-544. Available at: https://www.ncbi.nlm.nih.gov/pubmed/12445231.

190. King J, Althouse SK, Cary C, et al. Surveillance after complete response in patients with metastatic non-seminomatous germ-cell tumor (NSGCT). Journal of Clinical Oncology 2021;39:5018-5018. Available at: https://ascopubs.org/doi/abs/10.1200/JCO.2021.39.15_suppl.5018.

191. Culine S, Kerbrat P, Kramar A, et al. Refining the optimal chemotherapy regimen for good-risk metastatic nonseminomatous germ-cell tumors: a randomized trial of the Genito-Urinary Group of the French Federation of Cancer Centers (GETUG T93BP). Ann Oncol 2007;18:917-924. Available at: https://www.ncbi.nlm.nih.gov/pubmed/17351252.

192. Jones RH, Vasey PA. Part II: testicular cancer--management of advanced disease. Lancet Oncol 2003;4:738-747. Available at: https://www.ncbi.nlm.nih.gov/pubmed/14662430.

193. de Wit R, Stoter G, Sleijfer DT, et al. Four cycles of BEP vs four cycles of VIP in patients with intermediate-prognosis metastatic testicular non-seminoma: a randomized study of the EORTC Genitourinary Tract Cancer Cooperative Group. European Organization for Research and Treatment of Cancer. Br J Cancer 1998;78:828-832. Available at: https://www.ncbi.nlm.nih.gov/pubmed/9743309.

194. Culine S, Kramar A, Theodore C, et al. Randomized trial comparing bleomycin/etoposide/cisplatin with alternating cisplatin/cyclophosphamide/doxorubicin and vinblastine/bleomycin regimens of chemotherapy for patients with intermediate- and poor-risk metastatic nonseminomatous germ cell tumors: Genito-Urinary Group of the French Federation of Cancer Centers Trial T93MP. J Clin Oncol 2008;26:421-427. Available at: https://www.ncbi.nlm.nih.gov/pubmed/18202419.

195. Nichols CR, Catalano PJ, Crawford ED, et al. Randomized comparison of cisplatin and etoposide and either bleomycin or ifosfamide

Discussion update in progress

Version 1.2026 © 2025 National Comprehensive Cancer Network© (NCCN©), All rights reserved. NCCN Guidelines® and this illustration may not be reproduced in any form without the express written permission of NCCN.

PLEASE NOTE that use of this NCCN Content is governed by the End-User License Agreement, and you MAY NOT distribute this Content or use it with any artificial intelligence model or tool.
Printed by Máximo López Chenlo on 5/4/2026 6:31:34 PM. Copyright © 2026 National Comprehensive Cancer Network, Inc. All Rights Reserved.

in treatment of advanced disseminated germ cell tumors: an Eastern Cooperative Oncology Group, Southwest Oncology Group, and Cancer and Leukemia Group B Study. J Clin Oncol 1998;16:1287-1293. Available at: https://www.ncbi.nlm.nih.gov/pubmed/9552027.

196. Funt SA, McHugh DJ, Tsai S, et al. Four Cycles of Etoposide plus Cisplatin for Patients with Good-Risk Advanced Germ Cell Tumors. Oncologist 2021;26:483-491. Available at: https://www.ncbi.nlm.nih.gov/pubmed/33586274.

197. van Dijk MR, Steyerberg EW, Habbema JD. Survival of non-seminomatous germ cell cancer patients according to the IGCC classification: An update based on meta-analysis. Eur J Cancer 2006;42:820-826. Available at: https://www.ncbi.nlm.nih.gov/pubmed/16574403.

198. Cafferty FH, White JD, Shamash J, et al. Long-term outcomes with intensive induction chemotherapy (carboplatin, bleomycin, vincristine and cisplatin/bleomycin, etoposide and cisplatin) and standard bleomycin, etoposide and cisplatin in poor prognosis germ cell tumours: A randomised phase II trial (ISRCTN53643604). Eur J Cancer 2020;127:139-149. Available at: https://www.ncbi.nlm.nih.gov/pubmed/32007714.

199. Kollmannsberger C, Daneshmand S, So A, et al. Management of disseminated nonseminomatous germ cell tumors with risk-based chemotherapy followed by response-guided postchemotherapy surgery. J Clin Oncol 2010;28:537-542. Available at: https://www.ncbi.nlm.nih.gov/pubmed/20026807.

200. Schmidt AH, Hoyer M, Jensen BFS, Agerbaek M. Limited post-chemotherapy retroperitoneal resection of residual tumour in non-seminomatous testicular cancer: complications, outcome and quality of life. Acta Oncol 2018;57:1084-1093. Available at: https://www.ncbi.nlm.nih.gov/pubmed/29537330.

201. Heidenreich A, Haidl F, Paffenholz P, et al. Surgical management of complex residual masses following systemic chemotherapy for metastatic testicular germ cell tumours. Ann Oncol 2017;28:362-367. Available at: https://www.ncbi.nlm.nih.gov/pubmed/27831507.

202. Daneshmand S, Albers P, Fossa SD, et al. Contemporary management of postchemotherapy testis cancer. Eur Urol 2012;62:867-876. Available at: https://www.ncbi.nlm.nih.gov/pubmed/22938868.

203. Riggs SB, Burgess EF, Gaston KE, et al. Postchemotherapy surgery for germ cell tumors--what have we learned in 35 years? Oncologist 2014;19:498-506. Available at: https://www.ncbi.nlm.nih.gov/pubmed/24718515.

204. Loehrer PJ, Sr., Gonin R, Nichols CR, et al. Vinblastine plus ifosfamide plus cisplatin as initial salvage therapy in recurrent germ cell tumor. J Clin Oncol 1998;16:2500-2504. Available at: https://www.ncbi.nlm.nih.gov/pubmed/9667270.

205. Park S, Lee S, Lee J, et al. Salvage chemotherapy with paclitaxel, ifosfamide, and cisplatin (TIP) in relapsed or cisplatin-refractory germ cell tumors. Onkologie 2011;34:416-420. Available at: https://www.ncbi.nlm.nih.gov/pubmed/21934340.

206. Kurobe M, Kawai K, Oikawa T, et al. Paclitaxel, ifosfamide, and cisplatin (TIP) as salvage and consolidation chemotherapy for advanced germ cell tumor. J Cancer Res Clin Oncol 2015;141:127-133. Available at: https://www.ncbi.nlm.nih.gov/pubmed/25062721.

207. Einhorn LH, Williams SD, Chamness A, et al. High-dose chemotherapy and stem-cell rescue for metastatic germ-cell tumors. N Engl J Med 2007;357:340-348. Available at: https://www.ncbi.nlm.nih.gov/pubmed/17652649.

208. Feldman DR, Sheinfeld J, Bajorin DF, et al. TI-CE high-dose chemotherapy for patients with previously treated germ cell tumors: results and prognostic factor analysis. J Clin Oncol 2010;28:1706-1713. Available at: https://www.ncbi.nlm.nih.gov/pubmed/20194867.

209. Albers P, Ganz A, Hannig E, et al. Salvage surgery of chemorefractory germ cell tumors with elevated tumor markers. J Urol 2000;164:381-384. Available at: https://www.ncbi.nlm.nih.gov/pubmed/10893590.

210. George DW, Foster RS, Hromas RA, et al. Update on late relapse of germ cell tumor: a clinical and molecular analysis. J Clin Oncol

Discussion update in progress

Version 1.2026 © 2025 National Comprehensive Cancer Network© (NCCN©), All rights reserved. NCCN Guidelines® and this illustration may not be reproduced in any form without the express written permission of NCCN.

PLEASE NOTE that use of this NCCN Content is governed by the End-User License Agreement, and you MAY NOT distribute this Content or use it with any artificial intelligence model or tool.
Printed by Máximo López Chenlo on 5/4/2026 6:31:34 PM. Copyright © 2026 National Comprehensive Cancer Network, Inc. All Rights Reserved.

2003;21:113-122. Available at: http://www.ncbi.nlm.nih.gov/pubmed/12506179.

211. Lipphardt ME, Albers P. Late relapse of testicular cancer. World J Urol 2004;22:47-54. Available at: https://www.ncbi.nlm.nih.gov/pubmed/15064970.

212. Oing C, Lorch A, Bokemeyer C. Ongoing Clinical Trials in Testicular Cancer: The TIGER Trial. Oncol Res Treat 2016;39:553-556. Available at: https://www.ncbi.nlm.nih.gov/pubmed/27614956.

213. McHugh DJ, Feldman DR. Conventional-Dose versus High-Dose Chemotherapy for Relapsed Germ Cell Tumors. Adv Urol 2018;2018:7272541. Available at: https://www.ncbi.nlm.nih.gov/pubmed/29736168.

214. Lorch A, Bascoul-Mollevi C, Kramar A, et al. Conventional-dose versus high-dose chemotherapy as first salvage treatment in male patients with metastatic germ cell tumors: evidence from a large international database. J Clin Oncol 2011;29:2178-2184. Available at: https://www.ncbi.nlm.nih.gov/pubmed/21444870.

215. Le DT, Durham JN, Smith KN, et al. Mismatch repair deficiency predicts response of solid tumors to PD-1 blockade. Science 2017;357:409-413. Available at: https://www.ncbi.nlm.nih.gov/pubmed/28596308.

216. Le DT, Uram JN, Wang H, et al. PD-1 Blockade in Tumors with Mismatch-Repair Deficiency. N Engl J Med 2015;372:2509-2520. Available at: https://www.ncbi.nlm.nih.gov/pubmed/26028255.

217. Lala M, Li TR, de Alwis DP, et al. A six-weekly dosing schedule for pembrolizumab in patients with cancer based on evaluation using modelling and simulation. Eur J Cancer 2020;131:68-75. Available at: https://www.ncbi.nlm.nih.gov/pubmed/32305010.

218. Marabelle A, Fakih M, Lopez J, et al. Association of tumour mutational burden with outcomes in patients with advanced solid tumours treated with pembrolizumab: prospective biomarker analysis of the multicohort, open-label, phase 2 KEYNOTE-158 study. Lancet Oncol 2020;21:1353-1365. Available at: https://www.ncbi.nlm.nih.gov/pubmed/32919526.

219. Bokemeyer C, Oechsle K, Honecker F, et al. Combination chemotherapy with gemcitabine, oxaliplatin, and paclitaxel in patients with cisplatin-refractory or multiply relapsed germ-cell tumors: a study of the German Testicular Cancer Study Group. Ann Oncol 2008;19:448-453. Available at: https://www.ncbi.nlm.nih.gov/pubmed/18006893.

220. De Giorgi U, Rosti G, Aieta M, et al. Phase II study of oxaliplatin and gemcitabine salvage chemotherapy in patients with cisplatin-refractory nonseminomatous germ cell tumor. Eur Urol 2006;50:1032-1038; discussion 1038-1039. Available at: https://www.ncbi.nlm.nih.gov/pubmed/16757095.

221. Einhorn LH, Brames MJ, Juliar B, Williams SD. Phase II study of paclitaxel plus gemcitabine salvage chemotherapy for germ cell tumors after progression following high-dose chemotherapy with tandem transplant. J Clin Oncol 2007;25:513-516. Available at: https://www.ncbi.nlm.nih.gov/pubmed/17290059.

222. Kollmannsberger C, Beyer J, Liersch R, et al. Combination chemotherapy with gemcitabine plus oxaliplatin in patients with intensively pretreated or refractory germ cell cancer: a study of the German Testicular Cancer Study Group. J Clin Oncol 2004;22:108-114. Available at: https://www.ncbi.nlm.nih.gov/pubmed/14701772.

223. Mulherin BP, Brames MJ, Einhorn LH. Long-term survival with paclitaxel and gemcitabine for germ cell tumors after progression following high-dose chemotherapy with tandem transplant. Am J Clin Oncol 2015;38:373-376. Available at: https://www.ncbi.nlm.nih.gov/pubmed/26214082.

224. Pectasides D, Pectasides M, Farmakis D, et al. Gemcitabine and oxaliplatin (GEMOX) in patients with cisplatin-refractory germ cell tumors: a phase II study. Ann Oncol 2004;15:493-497. Available at: https://www.ncbi.nlm.nih.gov/pubmed/14998855.

225. Seidel C, Oechsle K, Lorch A, et al. Efficacy and safety of gemcitabine, oxaliplatin, and paclitaxel in cisplatin-refractory germ cell cancer in routine care--Registry data from an outcomes research project of the German Testicular Cancer Study Group. Urol Oncol 2016;34:167 e121-168. Available at: https://www.ncbi.nlm.nih.gov/pubmed/26699830.

Discussion update in progress

Version 1.2026 © 2025 National Comprehensive Cancer Network© (NCCN©), All rights reserved. NCCN Guidelines® and this illustration may not be reproduced in any form without the express written permission of NCCN.

PLEASE NOTE that use of this NCCN Content is governed by the End-User License Agreement, and you MAY NOT distribute this Content or use it with any artificial intelligence model or tool.
Printed by Máximo López Chenlo on 5/4/2026 6:31:34 PM. Copyright © 2026 National Comprehensive Cancer Network, Inc. All Rights Reserved.

226. Miller JC, Einhorn LH. Phase II study of daily oral etoposide in refractory germ cell tumors. Semin Oncol 1990;17:36-39. Available at: https://www.ncbi.nlm.nih.gov/pubmed/2154858.

227. U.S. Food and Drug Administration. FDA approves pembrolizumab for adults and children with TMB-H solid tumors. 2020. Available at: https://www.fda.gov/drugs/drug-approvals-and-databases/fda-approves-pembrolizumab-adults-and-children-tmb-h-solid-tumors. Accessed January 19, 2021.

228. Prescribing information for pembrolizumab injection, for intravenous use. 2024. Available at: https://www.accessdata.fda.gov/drugsatfda_docs/label/2024/125514s155lbl.pdf. Accessed July 17, 2024.

229. Adra N, Einhorn LH, Althouse SK, et al. Phase II trial of pembrolizumab in patients with platinum refractory germ-cell tumors: a Hoosier Cancer Research Network Study GU14-206. Ann Oncol 2018;29:209-214. Available at: https://www.ncbi.nlm.nih.gov/pubmed/29045540.

230. Feldman DR, Lorch A, Kramar A, et al. Brain Metastases in Patients With Germ Cell Tumors: Prognostic Factors and Treatment Options--An Analysis From the Global Germ Cell Cancer Group. J Clin Oncol 2016;34:345-351. Available at: https://www.ncbi.nlm.nih.gov/pubmed/26460295.

231. Schmoll HJ, Souchon R, Krege S, et al. European consensus on diagnosis and treatment of germ cell cancer: a report of the European Germ Cell Cancer Consensus Group (EGCCCG). Ann Oncol 2004;15:1377-1399. Available at: https://www.ncbi.nlm.nih.gov/pubmed/15319245.

232. Beyer J, Albers P, Altena R, et al. Maintaining success, reducing treatment burden, focusing on survivorship: highlights from the third European consensus conference on diagnosis and treatment of germ-cell cancer. Ann Oncol 2013;24:878-888. Available at: https://www.ncbi.nlm.nih.gov/pubmed/23152360.

233. Boyle HJ, Jouanneau E, Droz JP, Flechon A. Management of brain metastases from germ cell tumors: a single center experience. Oncology 2013;85:21-26. Available at: https://www.ncbi.nlm.nih.gov/pubmed/23816811.

234. Loriot Y, Pagliaro L, Flechon A, et al. Patterns of relapse in poor-prognosis germ-cell tumours in the GETUG 13 trial: Implications for assessment of brain metastases. Eur J Cancer 2017;87:140-146. Available at: https://www.ncbi.nlm.nih.gov/pubmed/29149760.

235. Kollmannsberger C, Nichols C, Bamberg M, et al. First-line high-dose chemotherapy +/- radiation therapy in patients with metastatic germ-cell cancer and brain metastases. Ann Oncol 2000;11:553-559. Available at: https://www.ncbi.nlm.nih.gov/pubmed/10907948.

236. Kalra M, Adra N, Hanna N, et al. High-dose chemotherapy plus peripheral blood stem cell transplantation for patients with relapsed germ cell tumors and active brain metastases. Cancer 2020;126:1202-1207. Available at: https://www.ncbi.nlm.nih.gov/pubmed/31743434.

237. Carver BS, Shayegan B, Serio A, et al. Long-term clinical outcome after postchemotherapy retroperitoneal lymph node dissection in men with residual teratoma. J Clin Oncol 2007;25:1033-1037. Available at: https://www.ncbi.nlm.nih.gov/pubmed/17261854.

238. Comiter CV, Kibel AS, Richie JP, et al. Prognostic features of teratomas with malignant transformation: a clinicopathological study of 21 cases. J Urol 1998;159:859-863. Available at: https://www.ncbi.nlm.nih.gov/pubmed/9474169.

239. Donadio AC, Motzer RJ, Bajorin DF, et al. Chemotherapy for teratoma with malignant transformation. J Clin Oncol 2003;21:4285-4291. Available at: https://www.ncbi.nlm.nih.gov/pubmed/14645417.

240. Flood TA, Ulbright TM, Hirsch MS. "Embryonic-type Neuroectodermal Tumor" Should Replace "Primitive Neuroectodermal Tumor" of the Testis and Gynecologic Tract: A Rationale for New Nomenclature. Am J Surg Pathol 2021;45:1299-1302. Available at: https://www.ncbi.nlm.nih.gov/pubmed/34232605.

241. Al-Hader AA, Jain A, Al-Nasrallah N, Einhorn LH. Metastatic malignant transformation of teratoma to primitive neuroectodermal tumor (PNET): results with PNET-based chemotherapy. Am J Clin Oncol

Discussion update in progress

Version 1.2026 © 2025 National Comprehensive Cancer Network© (NCCN©), All rights reserved. NCCN Guidelines® and this illustration may not be reproduced in any form without the express written permission of NCCN.

PLEASE NOTE that use of this NCCN Content is governed by the End-User License Agreement, and you MAY NOT distribute this Content or use it with any artificial intelligence model or tool.
Printed by Máximo López Chenlo on 5/4/2026 6:31:34 PM. Copyright © 2026 National Comprehensive Cancer Network, Inc. All Rights Reserved.

2015;38:364-366. Available at: https://www.ncbi.nlm.nih.gov/pubmed/23799289.

242. Wei C, Cary C, Masterson TA, et al. Adjuvant chemotherapy with CAV/IE for malignant transformation of teratoma to primitive neuroectodermal tumor (PNET): An institutional analysis from Indiana University. Journal of Clinical Oncology 2021;39:5026-5026. Available at: https://ace.asco.org/content/329491/abstract/198085.

243. Punjani N, Winquist E, Power N. Do retroperitoneal extragonadal germ cell tumours exist? Can Urol Assoc J 2015;9:381-384. Available at: https://www.ncbi.nlm.nih.gov/pubmed/26788225.

Discussion update in progress

Version 1.2026 © 2025 National Comprehensive Cancer Network© (NCCN©), All rights reserved. NCCN Guidelines® and this illustration may not be reproduced in any form without the express written permission of NCCN.